Chapter 7

High-Tension Abdominoplasty

Lorne King Rosenfield



Pierre Auguste Renoir: Woman in an interior

Abdominoplasty can be both deceivingly easy to perform and maddeningly difficult to perfect. The plastic surgeon is challenged to excise all of the redundant skin and fat through the shortest possible incision and to ensure per primam healing with an inconspicuous scar. To rise to this challenge requires one to become a student of abdominoplasty; one must continuously hone his or her surgical planning and execution in an effort to find a more balanced technique that is both reliably safe and aesthetically successful. One such technique is the original high lateral tension abdominoplasty (HLTA) modified into the high tension abdominoplasty (HTA), with some 2.0 modifications.

The traditional primary goals of abdominoplasty have always been to excise the excess skin or pannus of the central lower abdomen and to plicate the abdominal fascia through a suprapubic incision. Unfortunately, the classic abdominoplasty often falls short of this goal and results in a high-riding scar, or leaves remaining skin and lipodystrophy at the pubis, thighs, flanks, and hips, and there is a persistent incidence of midline skin necrosis or wound dehiscence.

The HTA addresses these shortfalls. This procedure may be defined as a more complete treatment of the trunk aesthetic unit from the abdomen to the pubis, hips, and thighs, with a greater aesthetic result and a margin of vascular safety. This chapter outlines the techniques and tools needed to obtain these superior results safely and consistently.

Evolution of the Modern Abdominoplasty

The abdominoplasty technique has evolved significantly over the past 40 years. The modern technique was developed in South America during the 1960s. The basic surgical tenets have always been to conduct a rectus plication that involves maximal excision of the central skin excess through extensive undermining of the entire abdominal wall. The closure is often performed under some tension, so it is conducted with the patient in significant flexion.

When liposuction was introduced during the 1980s, it soon became apparent that its exuberant application during an abdominoplasty was fraught with an unacceptable incidence of flap ischemia and skin necrosis. Liposuction then evolved into a

more conservative adjuvant treatment. Although there were indeed fewer physiologic problems with this technique, the aesthetic results were also, once again, more constrained.

Then, during the early 1990s, Lockwood published a series of seminal articles that single-handedly changed the tack of the abdominoplasty. With his extensive experience with body contouring surgery, he decisively demonstrated and defin tively modifi d the surgical principles of abdominoplasty and reported greater safety and improved aesthetics. He enumerated several surgical tenets that were in many ways diametrically opposed to those of the classic or traditional abdominoplasty. These included the undermining of only the central skin flap to facilitate plication, with discontinuous dissection elsewhere (to enhance vascularity and allow judicious concomitant liposuction), as well as the initial resection of the lateral excess skin, with more conservative resection of the central skin flap (to accomplish a more complete and natural repair) by using a planned and controlled high-tension closure with the diligent use of the underlying superfic al fascial system (SFS). Thus the HLTA was born.

HIGH-TENSION ABDOMINOPLASTY VERSION 2.0

Since 2000 I have become a diligent student of these Lockwood principles, and I have applied them to several hundred patients. The application of these principles and the critical analysis of their results have driven the successful evolution of the original HLTA procedure. For a patient's results to be considered truly successful, strict self-imposed standards were applied: the procedure had to demonstrate the greatest degree of safety (zero tolerance for complications) and the maximal aesthetic result (correction of all deformities), with consistent reliability of the technique (regardless of patient presentation). Several important expanded principles can be distilled from this experience to defi e a true 2.0 advancement in technique.

Excess Skin Above the Incision

Surgeons performing the abdominal procedure should not adhere slavishly to the age-old mandate that all of the excess skin between the pubis and the umbilicus be excised. Th s approach only truly works for a patient with an enormous pannus. For all other cases, the excisional marking has traditionally been placed above the pubic hairline to accomplish wound closure. Despite the harnessing of excess pubis, the closure often remains overly tight. Th s results in an excessively high scar, a superiorly retracted pubis, an unnaturally flat hypogastrium, and, more seriously, an increased opportunity for wound dehiscence and skin necrosis. The redundant pubis should instead be excised rather than harnessed to ensure an inconspicuous

wound closure. With the exception of the most redundant cases, this approach often involves deliberately leaving some of the skin between the pubis and the umbilicus intact, thereby necessitating closure of the original umbilical site. The surgeon must resist the temptation to remove even these few centimeters of intervening central abdominal skin for fear of re-creating the usual overly tight closure.

Excess Skin Below the Incision

Any surgeon performing abdominoplasty should consider not only what is above the future incision (the traditional pannus) but also what is below it: excess pubis, anterolateral and medial thigh redundancy, and buttocks laxity. If these areas are not addressed, the tissues below the incision may be distractingly untreated, and thus the full effect of HTA will not be realized. This tenet underlines one of the greatest benefits of HTA, which is not usually considered possible with traditional abdominoplasty: one can affect a true body lift through an anterior incision. This approach describes what is actually more of a *global* tension abdominoplasty, with maximal sequential tension placed from laterally to medially (hence the evolution of HLTA [with emphasis on the lateral] to, more simply, HTA).

Excess Skin Left Behind

It has always been important to evaluate the magnitude of the excess skin to be excised. However, to actually design the most efficient length and cant of the incision, the extent and orientation of the skin to be left behind should also be assessed. The surgeon can at once ensure that the remaining skin is sufficient to close the defect and is efficiently relieved of its *own* redundancy. This principle should be applied to both the central and lateral closures. More specifically, laterally, the excess skin at the hip and thigh is often neglected by traditional abdominoplasty. This primarily obliquely oriented excess tissue is most efficiently removed through the oblique incision and vector of the HTA. Centrally, the superfluous skin at the epigastrium (supraumbilical area) actually constitutes primarily horizontal excess. This excess skin can neither be efficiently removed nor used to close a lower abdominal defect through the horizontal incision. Therein lie the essential flaws of the traditional abdominoplasty and the compelling efficacies of the high-tension technique: conflicting and unintended consequences may occur with the former and be mitigated with the latter. The central epigastric excess is not treated effectively, and the suprapubic wound closure is too tight, despite this epigastric redundancy. Laterally, the excess cannot be effectively treated, because the remaining abdominal flap has been recruited primarily to close the wound centrally. To reconcile this paradox, less skin should be excised centrally and more skin excised laterally through an HTA-oriented incision and repair.

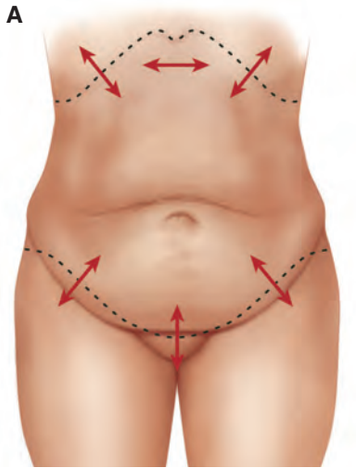

The more the procedure follows the vectors of excess of both what is taken and what will remain, the more efficient the treatment of redundant skin will be. By applying this vector of excess principle, the necessary direction of the most desirable HTA central and lateral incision placement is easily understood and defined.

Fig. 7-1, A

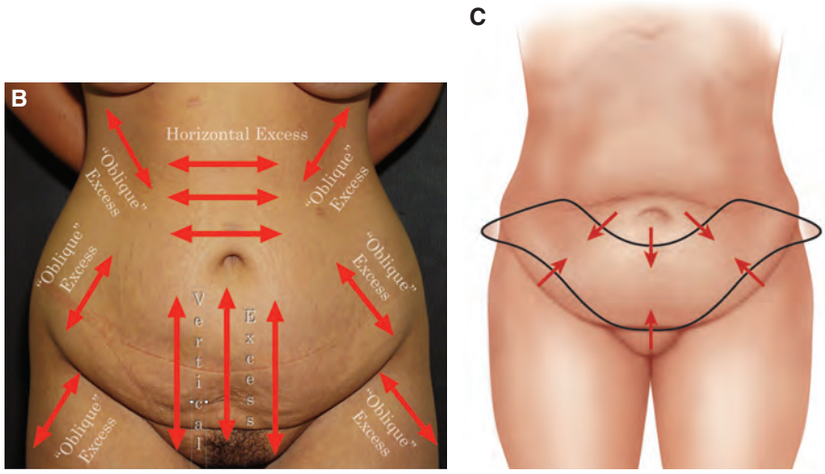

Fig. 7-1, B and C

With the use of this vector analysis, the tissue above and below the planned incision is then appreciated to be redundant in a more oblique vector and so should be removed through an opposing oblique incision. Serendipitously, this same vector matches the relative direction of the desired HTA lateral scar placement. And at the same time, this oblique vector more efficiently treats the predominantly horizontal excess in the epigastrium. However, centrally in the suprapubic region, the excess is truly vertically oriented, so a fully horizontal incision remains most efficacious. When applying this vector of excess principle, the necessary direction of the most desirable HTA central and lateral incision placement is easily understood and defined. Thus, the more a procedure follows the vectors of excess of both what is taken and what will remain, the more efficient the treatment of redundant skin will be. These principles will be clearly illustrated in the Physical Examination section later in this chapter.

Length of the Incision

There is a corollary of the vector of excess principle: The extent of the incision should follow the extent of the skin excess, permitting the application of the high-tension approach and a more dramatic result. In fact, as will be discussed later in this chapter, a virtual lower body lift can be accomplished with the patient in an entirely supine position. Although the most posterior aspects of the buttocks and thighs cannot be fully addressed, this technique can and does gratify the majority of patients. And, most importantly, this more conservative body lift educes the surgical time and the operative risks as compared with a full truncal lift procedure.

Tension of the Incision

Lockwood—originally and rightfully so—emphasized the lateral tension nature of this technique. Contrary to the traditional approach, he stated that one must begin the resection laterally rather than medially. This admonition emanated from his original observation that there was actually more redundancy laterally at the hip, thigh, and buttock as compared with centrally. Indeed, if the surgeon respects and executes this principle, he or she will realize a superior correction (hence Lockwood's "lateral tension" eponym). However, as previously explained, it is more instructive and in fact more efficacious to consider the entire length of the wound to be available for a tension repair. If this tension principle is honored, it is possible to realize maximal correction centrally as well as in the pubic area and the inner and anterior thigh regions.

Placement of the Incision

The goals of the design and placement of the future abdominoplasty wound are to harness its access and hide its scar. Lockwood originally described a very high (French-cut) lateral closure, probably because of the style of clothing that was more fashionable at the time and also because a more oblique vector of pull does indeed effici tly treat the upper abdominal excess, as described previously. However, because fashion changes and a hidden scar will always trump some residual excess skin, it is a basic tenet of this HTA 2.0 technique to deliberately mark patients within the outlines of their preferred style of clothing. Th s philosophy becomes particularly relevant when contending with a low-cut jeans fashion so as to prevent displacement of the lateral scar too far superiorly.

Treatment of the Remaining Subcutaneous Fat

The location and extent of the remaining subcutaneous fat must also be evaluated. Th s assessment represents an age-old plastic surgical battle between beauty and

blood. In other words, at what cost to the blood supply does the surgeon attempt to remove all remaining excess subcutaneous fat? Lockwood originally described a reasonable treatment détente: Liposuction could be conducted beneath any tissues that have not been undermined. More recently, the proverbial pendulum has swung backward, with certain publications once again giving surgeons permission to conduct more aggressive full truncal liposuction at the time of the abdominoplasty. Th s recommendation is predicated on Lockwood's admonition that the restrained abdominal flap dissection preserves enough perforators to allow central liposuction. However, one fact must be persistently respected: the abdominal flap remains a *random* flap. In addition, some of these same precious perforators must already be sacrific d with the repair of the more protuberant abdomen. Lockwood's past principles, built on a prodigious amount of experience, embody these very facts. Today's surgeon should perhaps still pause and consider second-stage liposuction of the flap as a safer alternative. Thus, in an abdominoplasty patient with the more common higher BMI of 26 or more, liposuction should be restricted to the waist and hip rolls, with a secondary central liposuction planned for some 6 to 12 months after the initial procedure; only at that time can zero tolerance for skin-flap necrosis and dehiscence be honored.

Surgical Anatomy

A general survey of the abdominal wall's anatomy has already been described in great detail in Chapter 1. For greater efficacy, the specific natomy most relevant to the understanding, planning, and application of the HTA involves three critical anatomic points that should be understood and respected:

1. The SFS: Scarpa fascia was described more than 200 years ago, but it was Lockwood who rediscovered this powerful anatomic layer. Lockwood's vision of maximally lifting the body's skin envelope with the use of tension mandated a more secure closure, and this resulted in his revelation that this fascial layer had tensile properties far beyond the local wound. The Scarpa layer was anything but passive and could instead act more like a finger trap that tightened reliably as the wound tension increased. Thus the SFS layer must be harnessed to at once realize the maximal lift that this technique can proffer and prevent wound dehiscence.
2. The perforator blood supply: It is a poorly respected fact that, when the abdominal skin is undermined, it becomes a random flap and therefore must be protected just as judiciously to avoid flap ischemia. Once again, Lockwood was the fi st to emphasize the importance of sacrifici g only those perforators within the boundaries of the prospective fascial plication during flap elevation. Although the remaining flap has not been fully undermined, the application of discontinuous dissection still ensures its effici t mobilization and preservation of its perforators.

3. The zones of adherence: Lockwood emphasized the existence of various points of skin attachment. Practically speaking, the skin must simply be released, at least bluntly, wherever adhered if one is to realize the maximum translation of the pull of the remaining skin envelope. This is particularly true in the region of the anterolateral hip and thigh. The one exception to this rule is the supraumbilical constricted waistband of adherence, which I originally described. This impressively immobile zone is most often identified in heavier patients and in those who have experienced significant weight loss. Although it can indeed inhibit the mobility of the upper abdominal flap, this inordinately tight band should be left intact. Even with significant undermining, the overhanging excess skin cannot be treated effectively, and the ischemia risk will remain predictable. This situation is further discussed later in this chapter.

Anatomic Danger Zones

- The SFS: This layer must be maximally used to accomplish a proper tension lift, and it must be fully harnessed to prevent wound dehiscence.
- The costal perforators: The remaining skin flap of an abdominoplasty should properly be considered a random flap, and the superior and lateral costal perforators are its sole nourishment and insurance against skin necrosis. Efforts to preserve these vessels include conservative skin-flap elevation (which occurs in combination with discontinuous dissection) without direct liposuction.
- The supraumbilical band of adhesion: This scarlike crease and its overhanging skin excess are best left not elevated. Only a nominal degree of additional skin will be realized at the expense of a significantly higher chance of skin necrosis.
- The lateral femoral cutaneous nerve is quite vulnerable to inadvertent injury. This structure is best protected by mindfully preserving a layer of tissue over the iliac when dissecting the flap.

Indications and Contraindications

The most effective way to define the best use of the HTA is to discuss the characteristics of the ideal patient. In so doing, there is a necessary correlative principle: Rather than trying to fit an abdominoplasty technique to every patient, the surgeon must concede that some patients are simply not good surgical candidates. The indices that should guide the surgeon when determining abdominoplasty candidacy include the following:

- Omental fat: A patient with voluminous omental fat and attendant prodigious abdominal wall protrusion will resist effective fascial plication.

- Subcutaneous fat: A patient with significant excess subcutaneous fat will tempt aggressive liposuction and possible skin necrosis. Excessive fat also acts like a glue that immobilizes the skin, resisting the adequate translation of pull and therefore its removal.
- Skin: A patient with excessively deflated skin often responds after contouring with an annoyingly inevitable recurrence of relaxation that I call the "double stretch." This potential deformity mandates effective and thorough preoperative counseling.

PATIENT SELECTION

The patient criteria to be considered must be exhaustive and respected if the surgeon is to avoid major complications and patient disappointment. The ideal patient criteria include the following:

- Weight: The patient should not be grossly overweight (BMI less than 30). His or her weight should be stable for more than 6 months if a significant amount of weight has recently been lost.
- Medical condition: No major medical issues should be present, such as labile hypertension, diabetes, coronary disease, and nutritional deficiency (check albumin and protein levels).
- Psychological state: The patient should be well motivated to complete his or her postsurgical care and realistic about the results of the procedure.
- Habits/lifestyle: Patients should preferably perform regular exercise, eat a reasonable diet, and not smoke or consume excessive amounts of alcohol.
- Anatomy: The patient should have an absence of multiple abdominal scars, no extreme abdominal protrusion, a moderate subcutaneous fat layer, and easily mobile and translatable redundant skin.

Patient Evaluation

A comprehensive examination is essential to enable the surgeon to properly prepare the patient and accurately plan the surgery.

PHYSICAL EXAMINATION

The physical examination should include evaluation of all layers of the abdominal wall: skin, subcutaneous fat, and the underlying fascia and muscle, with an indirect assessment of the extent of intraabdominal fat.

Skin

The skin examination should involve much more than just assessment of the classic pannus of excess lower abdominal skin above the pubis.

Striae The boundaries and extent of any striae that may not be included in the resection should be duly noted and explained to the patient, particularly if they affect the area above the umbilicus.

Fig. 7-2

Adhesions Note should be made of any adhesions of the skin in the thighs and the abdomen proper. An adhesion can also be found at the level of the waist, particularly laterally; this is the waistline zone of adherence and contraction. There is most often what one may call a "secondary roll" of excess skin that rests above this valley, most notably in the larger patient or in the patient who has lost a signifi ant amount of weight. Th s band essentially divides the abdominal excess skin into superior and inferior segments. The surgeon must be aware that this adhesion will resist efforts to efface he upper abdominal excess of skin. Because this zone harbors vital perforators, only a judicious release of the area with the use of discontinuous undermining should be attempted. Otherwise, the upper abdominal redundancy is best addressed with either a fleu -de-lis type of abdominoplasty or a second-stage reverse abdominoplasty.

Excess Skin The extent of obvious anterior redundant skin (the width of the pannus) is noted fi st. Th s evaluation most accurately defi es the potential length of the incision. However, a proper assessment must extend beyond this obvious excess if a more complete correction of the entire anterior trunk aesthetic unit is to be made. In other words, the extent of redundancy should also be evaluated in a few areas: below the pannus; at the hips, thighs, and pubis; and above the pannus at the upper abdominal and epigastric area. The mobility or translation of the skin is also very telling: the looser the skin, the better the potential result.

Inferior Excess If there is particular excess at the lateral thighs, then the incision will be appreciably longer. If the HTA approach is to be properly applied in these patients, it is likely that the longer the incision is made, the better the results will be. Alternatively, if the patient has minimal excess laterally, then significant tension should not be planned to avoid making the incision gratuitously longer.

Fig. 7-3

Examination must be made of the redundancy of the skin at the upper abdomen, which can be more "stealthy" in its presentation, being evident only when the patient is asked to sit, bend over, or lie flat and the skin is "gathered." As previously explained, in the case of the horizontal "secondary roll" (Fig. 7-2), it is the waistline zone of adhesion that resists its full excision from below and thus would actually require a reverse-type abdominoplasty repair. In addition, for the more horizontal excess redundancy that may be seen at the upper, primarily midline zone, a fleur-de-lis type of approach would be necessary for full correction. Clearly, these more aggressive surgeries are primarily indicated in the massive-weight-loss patient, but the fact that this excess skin can be found in the routine patient underlies the necessity to duly inform patients that this same excess may not be fully removed through the traditional lower abdominoplasty approach.

Scars All scars of the abdomen are assessed. Of greatest concern are scars in the subcostal and midline areas; these require the surgeon to map out the safest and most effective surgical approach. For a subcostal scar, it is best to restrict undermining and, if possible, to convert the HTA into a fleur-de-lis type of procedure so that the scar is included within the pattern. The midline scar presents a similar challenge, and either a fleur-de-lis type of procedure or a reverse abdominoplasty pattern should again be considered.

Subcutaneous Fat

The subcutaneous layer must be carefully assessed and a "topographic" map of the underlying fat must be visualized. A "topographic" sense of the extent of underlying fat must be achieved. Th s mapping of the subcutaneous layer can serve as a guide for future markings to show where liposuction should be performed and, just as importantly, where it should not be performed. Usually the contouring will focus on the waist, hips, and lateral thighs. Th s liposuction enhances the HTA by both facilitating the translation of the pull of the skin with its liposuction-induced discontinuous dissection as well as accentuating the abdominoplasty's shaping effects. If the central flap is particularly thick with fat, then it is best to inform the patient that a second-stage liposuction surgery may be necessary to complete the repair safely.

Abdominal Wall

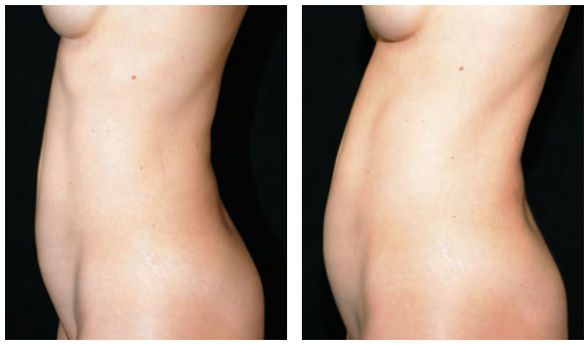

Fig. 7-4

Extent and Etiology of Protrusion The surgeon must assess the *degree* of abdominal wall relaxation, fi st with the patient lying down and the knees bent, and then with the patient standing. And while the patient is standing, he or she should be asked to make a conscious effort to relax the abdominal wall. The additional extent of protrusion that occurs is both surprising and informative. The image shows the extent of protrusion before and after relaxation.

It is then equally important to determine the *cause* of the abdominal wall protrusion, by asking the standing patient to try to suck in his or her stomach. The degree to which the patient can do so is directly proportional to the efficacy of a plication, because this maneuver gauges the magnitude of the intraabdominal fat. Compressing the lower abdominal wall with the patient supine and watching for herniation of the epigastric area is a good corroborative maneuver.

Presence of a Hernia The examination should also explore for the presence of any hernias, including incisional, epigastric, and periumbilical hernias, so that the surgical plan can include a proper repair in advance of any liposuction.

Shape of the Waist If the waist is more square as a result of excess fat blunting its shape, then aggressive liposuction in this zone can be very salutary.

Preoperative Planning and Preparation

All patients undergo an antisepsis/methicillin-resistant *Staphylococcus aureus* protocol that begins 3 days before surgery. The patient is instructed to do the following:

1. Shower daily with chlorhexidine gluconate (Hibiclens).
2. Apply mupirocin ointment (Bactroban) daily to the inside of the nose, ear canals, nipples, and umbilicus.

A few weeks before the surgery, the patient is encouraged to establish as regular a bowel program as possible. The patient is also discouraged from crash dieting or performing power exercise during the run-up period before the surgery.

The surgeon must clearly define for the patient the extent and limitations of the planned surgery:

- There will be excess skin that cannot be fully removed, including the potential dog-ears at the lateral margins and the inevitable residual skin and possible rolls of the upper abdomen above the zones of adhesion.
- There may be a scar at the lower midline of the abdomen that represents the site of the original umbilicus when all of the lower midline skin is intentionally not excised.
- The scar may be extended more laterally, depending on the amount of mobilized excess skin, explaining that the longer the wound becomes, the better the result should be.

Surgical Technique

PHOTOGRAPHY

It is critical to first procure a consistent and complete portfolio of photographs of the patient. This should include two sets (with the arms down and raised), with quarter-turn views both before and after marking. Also, as previously mentioned, it is valuable to pointedly ask the patient to fully relax their abdomen to document the true extent of wall laxity. All pictures should encompass not only the area of concern (the abdomen) but also the adjacent anatomic zones (the thighs and buttocks as well as the lower chest and epigastrium) so that the far-reaching effects of

the HTA may properly be documented. Additional views should be taken to further assist with accurate diagnosis and outcome assessment:

1. Photographs of the patient both sitting and bending over will illustrate the true amount of excess skin that is often hiding in front of a protuberant abdomen.
2. Photographs of the patient grasping the excess skin superiorly will confirm the accuracy of your markings and the potential treatment of the thigh and buttock excess with the lateral tension and at the abdominal area, and will help dictate the future improvement at the pubis and anterior thigh excess with the central tension.

ANESTHESIA

For a proper tension abdominoplasty, all patients will usually undergo general anesthesia. Only then can the patient's comfort be ensured when conducting the often far-reaching dissection and manipulation for the advanced treatment of the pubis, hips, and thighs. In addition, a period of muscle paralysis during the plication can be helpful to realize a more satisfactory correction of the abdominal wall relaxation.

MARKINGS

In addition to delineating the excess skin to be excised above and below the incision, an important goal of the marking process is to control the final position of the scar so that it rests within the patient's underclothes.

Marking Steps

Fig. 7-5, A-C

1. Discuss the placement and length of the lateral scar with the patient: This decision is made by balancing the merits of removing the maximum amount of redundant skin with the patient's preferences for clothing styles. In other words, the surgeon must reconcile the degree of lateral excess with the boundaries of the patient's most revealing clothing (underwear, a one- or two-piece bathing suit, or low-cut jeans, etc.). Then the incision may rise or fall at the hip markings, depending on the style of clothing selected.

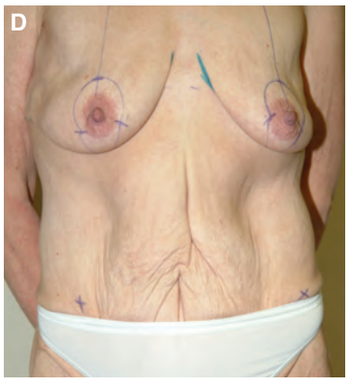

Fig. 7-5, D

2. Position the patient for marking: Mark the patient in the upright position, with him or her standing against a wall for support as necessary during the traction-assisted marking process.

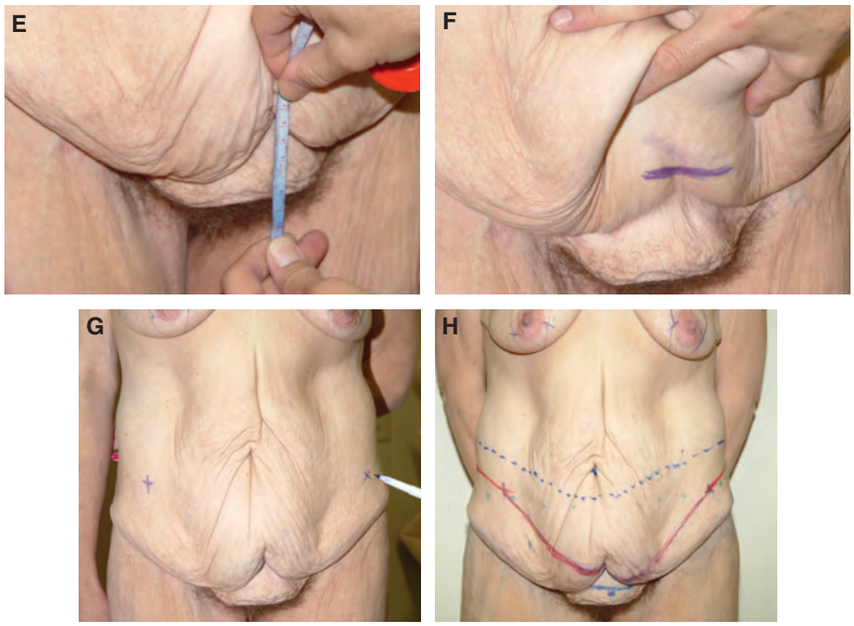

Fig. 7-5, E-H

3. Mark the location of the eventual scar:
   - Boundary marking: First, draw the outline of the patient's preferred clothing (underwear, low-cut jeans, or a bathing suit) on his or her body.
   - Suprapubic marking: Now, place a point on the pubis or abdomen that measures 6.5 to 7.5 cm superiorly from the upper incisura of the vagina or from the base of the penis.
   - Lateral marking: Next, place a dot on each side at the most lateral extent of the excess skin (pannus).

- Closure marking: Finally, connect the dots at the suprapubic level and laterally, staying within the clothing boundary marking. Th s line usually rests between the natural inguinal and abdominal wall gullies.

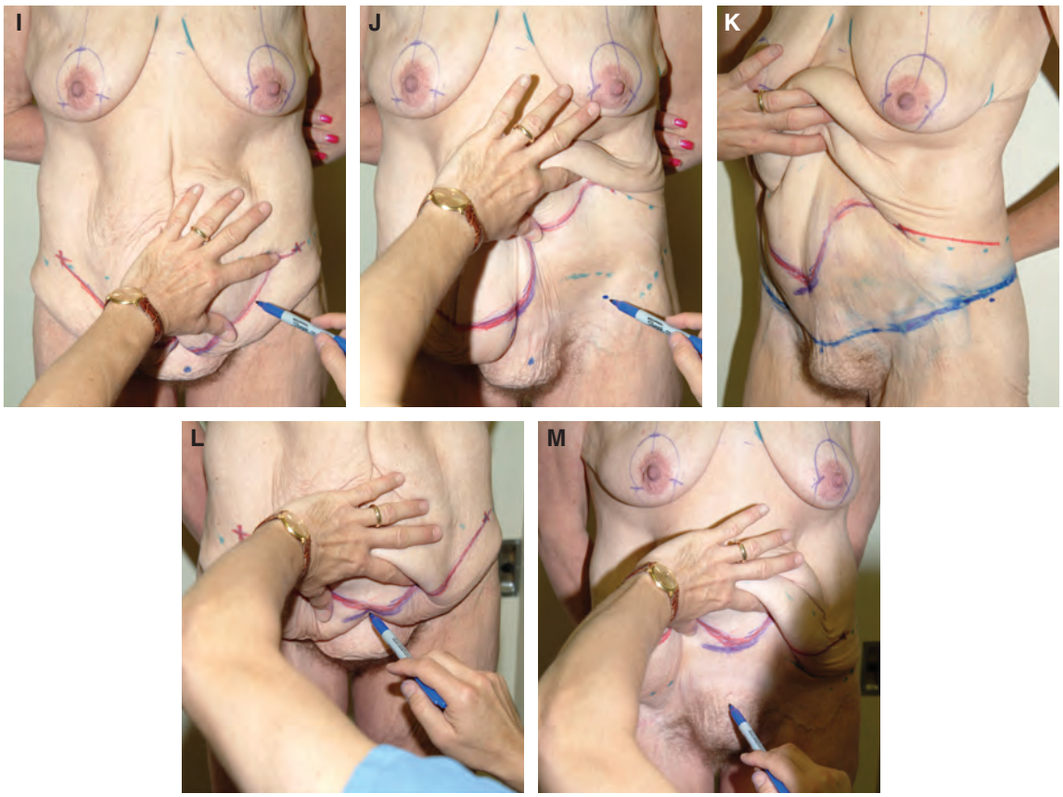

Fig. 7-5, I-M

4. Defi e the lower margin of excision next:
   - Place the marking pen over the future closure line, and maintain this position while pulling the excess skin upward vigorously until it is taut; this is the "tension" part of the HTA. Next, mark the displaced skin that is now directly below the tip of the pen. Because these maneuvers can and should be quite forceful, it is helpful to have the patient lean against a wall during the marking process.
   - Perform this procedure as many times as needed across the width of the abdomen to defi e the location of the lower incision.
   - To ensure harmonious scars laterally, it is prudent to extend the anterior markings to include the design of a possible future posterior body lift

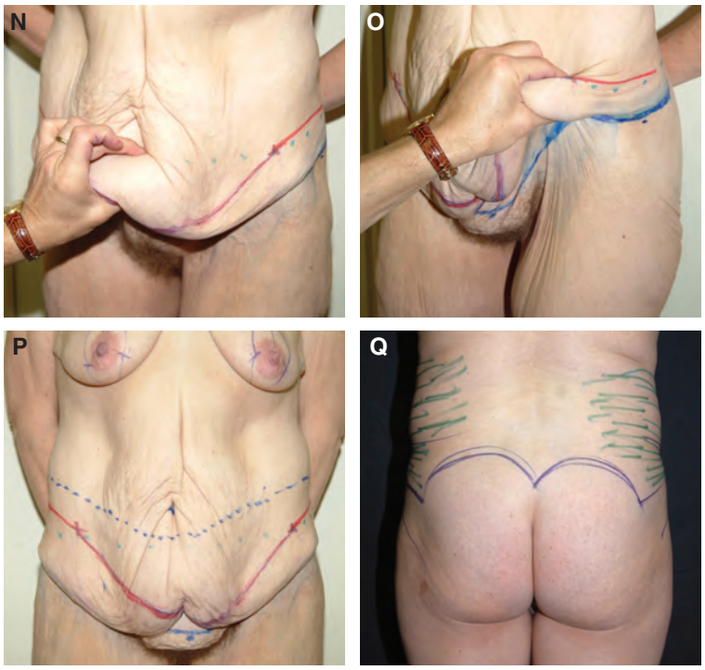

Fig. 7-5, N-Q

5. Estimate the upper margin of the excision:
   - Pinch the excess skin with the thumb on the lower incision line and the fi gers at the superior extent of the excess; try to keep the premarked fi al closure line visible at the middle of the skin roll. Next, dot along the superior margin of the skin roll to defi e the approximate upper limit of excision.
   - The resultant upper line of excision will usually rest several centimeters above the level of the umbilicus laterally and a few centimeters below the umbilicus centrally.
6. Determine the treatment of the umbilicus with the use of the following guiding coordinates:
   - The umbilicus should be roughly 9 to 12 cm above the superior margin of the pubis, depending on the patient's habitus.
   - The umbilicus should rest slightly above the latitude of the superior margin of the iliac crests.
   - However, during the fi al analysis—and like many challenges in plastic surgery—the surgeon's critical eye should ultimately prevail. The treatment of the umbilicus is determined by the following factors:
     - The amount of excess skin above and below the umbilicus (in other words, the upper and lower poles of the abdomen)
     - The location of the umbilicus in conjunction with the length of the abdomen and the waist

- If there is only a modest amount of excess skin above and below the umbilicus, the excision may be conducted with the umbilicus left intact, as in a mini-abdominoplasty.
- If there is a moderate amount of excess skin above and below the umbilicus and the umbilicus itself is relatively high riding, then the umbilicus may be released from its stalk (if only for a few centimeters) as part of a fl ating abdominoplasty.
- If there is a major amount of excess skin above and below the umbilicus, then the umbilicus must be circumscribed as part of a full abdominoplasty with translocation.

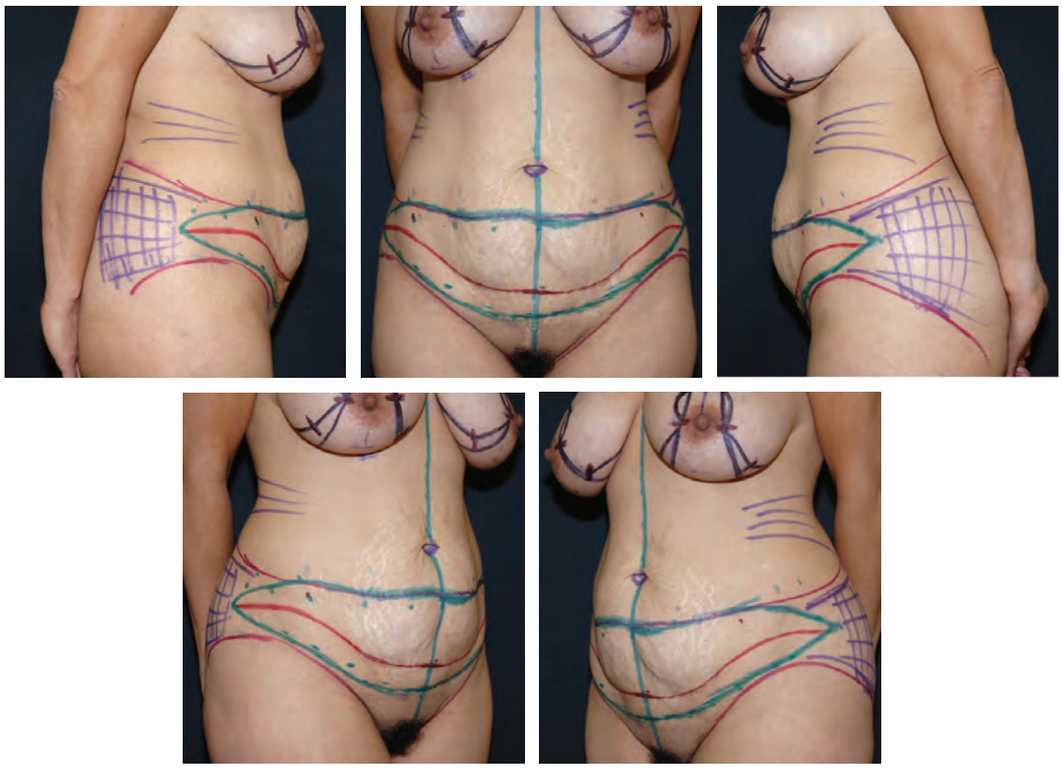

Fig. 7-6

7. Confi m the surgical plan: The fi al markings include areas of liposuction (purple), which purposely only include areas not undermined at the waist, hips, and thighs, as well as the fi al closure (red) and the inferior and superior margins of excision (green).

Fig. 7-7

- To preoperatively confirm the markings and the patient's expectations, the surgeon simply instructs the patient to reproduce the desired result by performing an examination room "lift" with the hands. This maneuver is particularly valuable for the massive-weight-loss patient with voluminous skin excess.

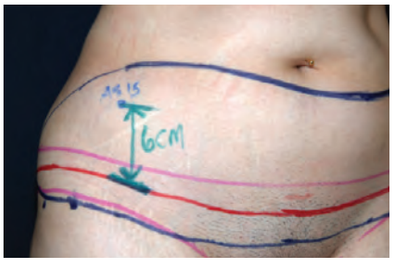

Fig. 7-8

- To further ensure a predictable final resting place for the closure, one can preoperatively mark and intraoperatively utilize the predetermined distance measured between the fixed point of the anterosuperior iliac spine and the closure marking to allow for final adjustment of the excision.

PATIENT PREPARATION, POSITIONING, AND SETUP

The patient is placed supine on a warmer on the operating table. Antiembolic compression devices are applied, and a Foley catheter is inserted. General anesthesia is administered.

To ensure proper exposure of all potential areas of repair, standing preparation is usually conducted; otherwise, a supine prep is performed anteriorly from the nipples to the knees and posteriorly from the back to the buttock. It should be noted that proper well-lit attention should be paid to the umbilicus, with one assistant exposing and the other cleansing the cavity. The bed, the patient, and the intravenous fluids are all warmed appropriately. Foot/ankle antiembolism compression devices are applied, and a Foley catheter is inserted.

TECHNIQUE

Traditional tumescent fluid is injected into the areas of future liposuction. With a needle and dye, the quadrants of the umbilicus are marked (with a double dot at the 12 o'clock position to prevent inadvertent rotation and possible torsion at closure), as well as the center point of the pubis and the defined future umbilical site.

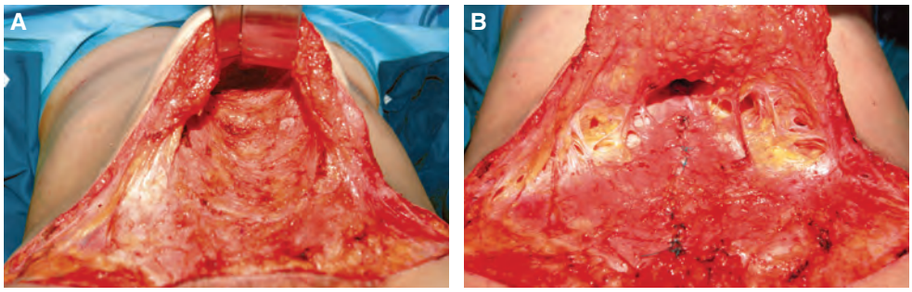

Fig. 7-9, A and B

The lower markings are incised, and the skin flap is elevated off the deep fascia just widely enough to allow the plication of the rectus fascia. To try to reduce the chance of seroma, a deliberate effort should be made to leave behind as much of the fine suprafascial and inguinal lymphatic tissue as possible.

Plication of the midline abdominal wall fascia is then accomplished by using a heavy suture material (0 or 1-0 PDS) in a running fashion while avoiding capture of the underlying muscle. A second running suture is placed to reinforce the repair and to allow further plication of the fascia as necessary. Additional plication may be conducted in an oblique or horizontal vector at the anterolateral abdominal wall to narrow the waist and locally flatten the abdominal wall.

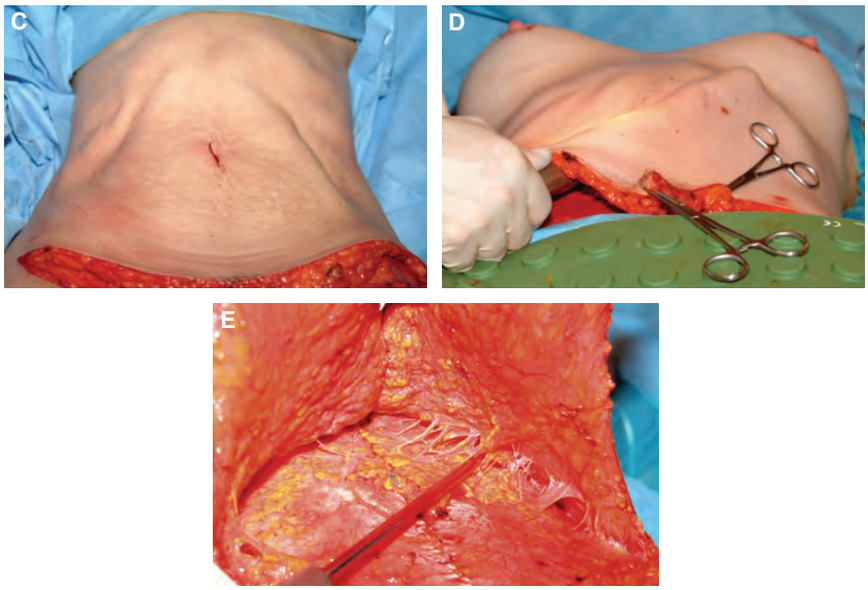

Fig. 7-9, C-E

Further release and mobilization of the nonundermined flap is then performed with one guiding principle in mind: to preserve as many perforators as possible. The surgeon could use either a measured and vertically oriented spreading of a large Mayo-like scissors or the gentle penetration of one or more fi gers, an oversized suction cannula, or, as is my preference, a Lockwood discontinuous dissector.

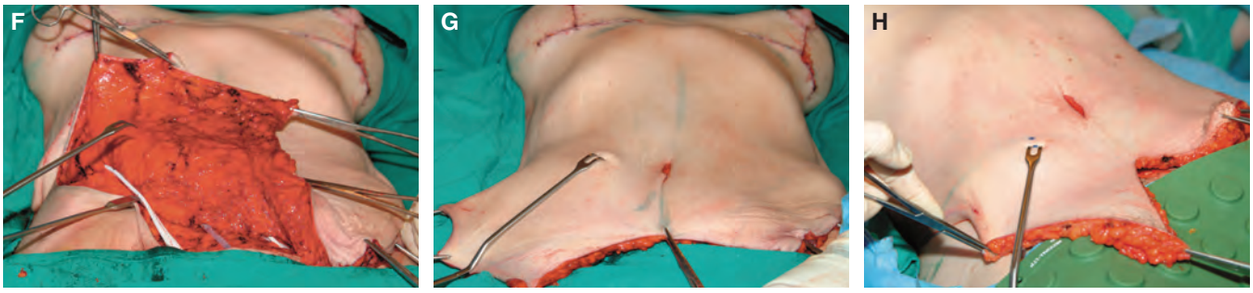

Fig. 7-9, F-H

The excess skin is then marked for resection, ideally with the use of the Lockwood flap instrument (a modifi d d'Assumpção-type clamp). Th s maneuver must be performed in a lateral-to-medial direction to properly carry out a high-tension resection and its attendant lateral contouring and lift. s previously described, the preoperatively determined desired distance between the ASIS and the future closure can be cross-checked intraoperatively and appropriate adjustments of skin excision made. Kocher clamps are placed on the upper flap, and the skin clamp tongs are se-

cured into the skin at the edge of the lower margin of the incision. With the simultaneous inferolateral pulling of the Kocher forceps and the superomedial pushing of the Lockwood instrument, the excess skin is accurately determined and marked.

Fig. 7-9, I

The tip of the demarcator should be pulled back a centimeter or so, and the incision skived to maintain a little more skin than subcutaneous tissue. In this way, when the deep-tension closure is conducted, this same tension is preferentially abided by the fascia, leaving the skin closure visibly everted and reciprocally tension free. If necessary, to neutralize the frequently discrepant thicknesses between the wound margins, some of the excess subscarpal fat can be carefully trimmed for several centimeters superiorly.

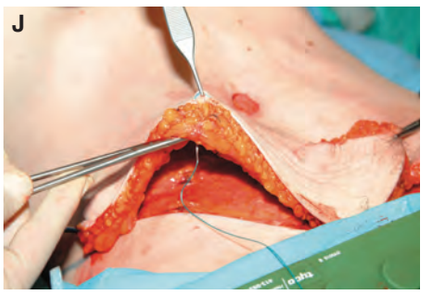

Fig. 7-9, J

An effort should be made to avoid closure over the ASIS itself to prevent the placement of additional tension on the wound. Also, if the pubic skin is excessively "mobile," particularly in the massive-weight-loss patient, tacking sutures can be placed to stabilize the tissues before wound closure. Finally, it is not necessary to place the operating room table in a lawn-chair position, as is done with the traditional approach. The Lockwood technique does not mandate the excision of all of the infra-

umbilical skin and thus inherently prevents the placement of excess tension on the suprapubic closure. Depending on the extent of infraumbilical skin resection, the umbilicus can be stretched in place, allowed to flat, or circumscribed and translocated, with the original umbilical site closed vertically when necessary. A triangular segment of mons pubis can be also excised if there is significant horizontal excess. After the excision of skin has been conducted and the tacking sutures have been placed, liposuction is conducted at the waist, hip rolls, pubis, and thighs, as planned. The areas that will deliver the greatest reward—and yet are the most often neglected—are the waist and pubis. If necessary, the lipodystrophy remaining at the abdominal flap is treated with a planned second-stage liposuction at any point 6 months or more postoperatively. If a new umbilical site is needed, it is then incised in a vertical direction, because this wound will be pulled open to an appropriate shape with the significant lateral pull of the high-tension approach. A small elliptical excision of skin on either side of the vertical incision may be conducted to increase the width of the umbilicus if needed. Pollock-type progressive tension sutures and a long-acting bupivacaine-type injection are placed, obviating the need for both drains and pain pumps. With 1-0 or 0 PDS, the SFS is reapproximated every few centimeters; this is one of the most critical steps in the whole operation. The more confident the surgeon is of the fascial closure, the more definitive and aggressive the skin traction and resection can be, and ultimately the better the results will be.

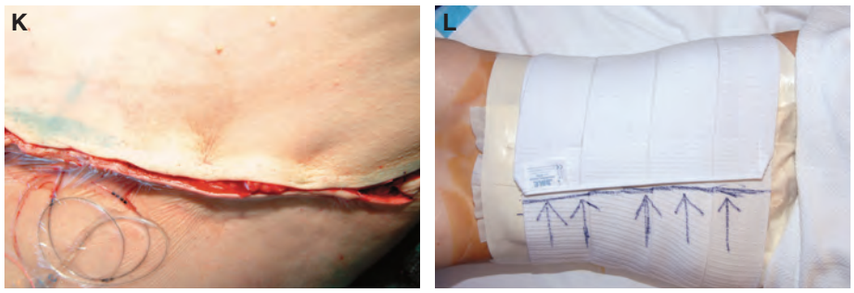

Fig. 7-9, K and L

The final closure is then made with 2-0 Vicryl for the deep dermis and 3-0 barbed suture for the superficial dermis. As previously mentioned, the closure should demonstrate a decidedly rolled border that indicates a lack of skin tension. Shortened Steri-Strips are placed to prevent edema-induced blisters. The surgeon applies the dressing of fluffed Kerlix and Velcro binder. To prevent the possibility of excess binder compression with reapplication, the binder's maximal outer edge is defined with a marker.

Postoperative Care

For the first day or two, all patients are cared for one-on-one by a dedicated RN team member in a private nursing setting. Antiembolism pumps and incentive spirometry are used consistently until the patient is fully mobile at approximately 4 or 5 days postoperatively. As previously mentioned, because the wound closure is not conducted in a flexed position, the patient is entirely able and fully free to stand upright. Within the first 2 weeks, the patient usually switches to an over-the-counter compression garment for an additional 6 weeks or so. Aerobic exercises may start approximately 2 to 3 weeks after surgery, and more aggressive activities gradually begin by 6 to 12 weeks after the operation.

Results and Outcomes

1. The essential advantage of this technique is its ability to deliver consistently superior and safer results:
   - The incision is reliably and satisfyingly hidden within the patient's clothing.
   - The hypogastrium is left with a more aesthetically pleasing mild convexity with the closure of the suprapubic skin under no tension.
   - The redundant skin below the incision can be effectively removed both laterally (fulfilling a significant lift of the anterolateral thighs and even the buttocks) and centrally (offering a reparative lift of the pubis and the anteromedial thighs). In effect, a virtual posterolateral body lift can be accomplished through an anterior approach if the wound is extended maximally, delivering a powerful "bedside to bedside" incision laterally.
   - The abdominal flap has essentially been "inoculated" from ischemia with the diligent maintenance of maximum blood supply. Local perforators are preserved with the application of discontinuous undermining, the withholding of any liposuction or direct fat removal from the flap itself, and the inherently tension-free suprapubic wound closure.
   - The horizontal skin excess from the middle to upper abdomen is more effectively treated with this oblique vector of excision.
2. Any residual fat (particularly within the abdominal flap itself) can safely be treated more aggressively, and as such more comprehensively, as a second-stage procedure 6 to 12 months after the abdominoplasty.
3. If desired, any remaining posterior excess at the back or buttock can be addressed during a second-stage procedure with a relatively short posterior extension of this extended abdominal incision for a complete posterior body lift
4. Any residual skin resting at the upper epigastric and subcostal areas can be treated later with a complementary excision through either submammary incisions or a proper reverse abdominoplasty.

5. If the lateral scar rests slightly outside of the outlines of the patient's preferred clothing, it can be easily moved up or down by excising the appropriate amount of adjoining skin under local anesthesia.

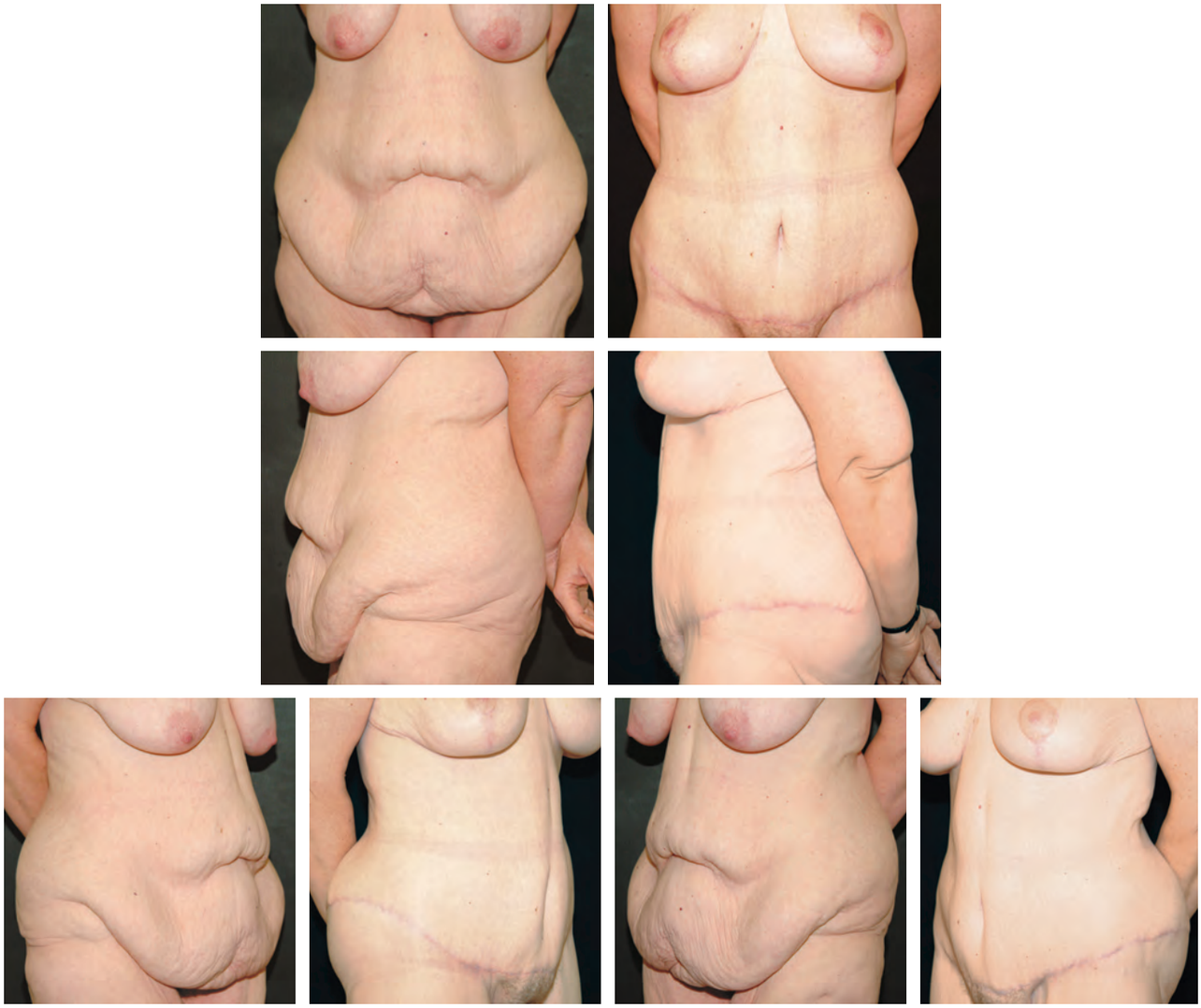

Fig. 7-10

Th s 46-year-old nulliparous woman was seen after a signifi ant weight loss of 66 kg (145 pounds) resulting from gastric bypass surgery. She preferred to avoid a midline scar, but she still desired as much improvement as possible. She underwent HTA with liposuction of the hips and lateral thighs, and a mastopexy was performed during the same surgery. Note the presence of the supraumbilical line of demarcation buttressing the more redundant skin above it. Dissection was deliberately discontinuous in this area, and the patient was informed of the likelihood of some residual epigastric excess postoperatively. She healed without complications.

These photographs were taken approximately 8 months postoperatively. Note the correction of the abdominal deformity, even in the epigastric area, as a result of the aforementioned oblique vector of excision. By extending the incision posterolaterally, the HTA's body lift effect is realized in the anterolateral thigh and buttock areas.

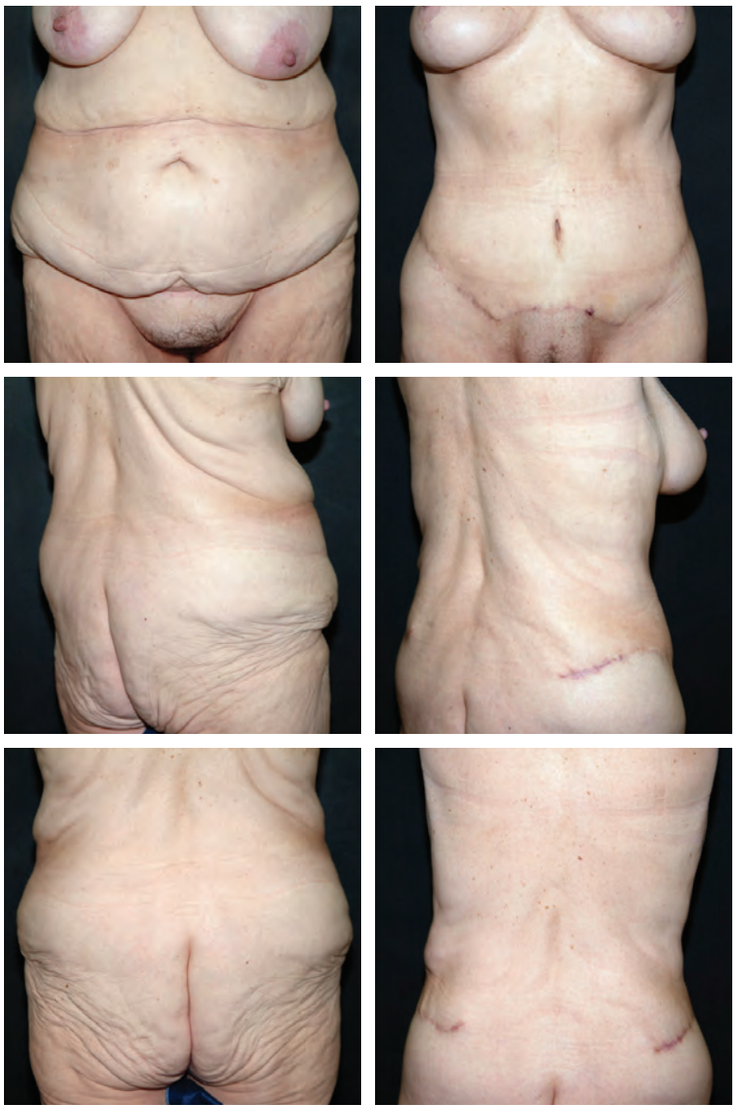

Fig. 7-11

Th s 57-year-old woman (gravida 2, para 2) is seen after a weight loss of about 45 kg (100 pounds). She underwent HTA with liposuction of the hips and thighs as well as breast reduction. Note the reconstitution of an aesthetic abdomen and how far posteriorly the incision was extended to realize a rewarding buttock lift for this patient.

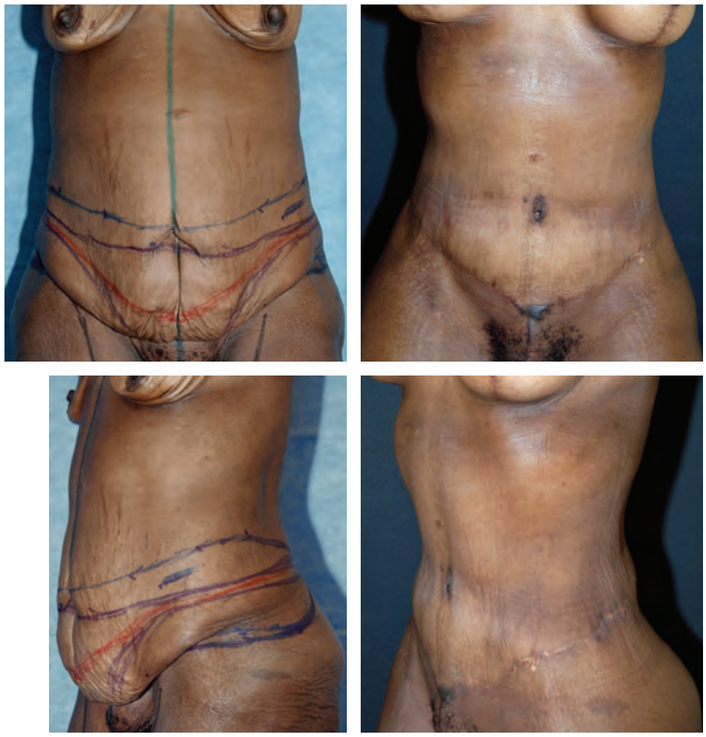

Fig. 7-12

This 39-year-old nulliparous woman achieved a weight loss of 90 kg (200 pounds) through diet and exercise alone. She had the most desirable skin envelope: thin and mobile. The patient underwent HTA with an extended posterior incision to realize the more complete excision and lift of the lateral trunk while still properly treating the central tissues. Liposuction of the hips and lateral thighs was accomplished, and a mastopexy with implantation was performed as well.

Fig. 7-13

Th s 43-year-old nulliparous woman achieved a weight loss of 66 kg (145 pounds) after gastric bypass surgery. She subsequently underwent HTA, and she is seen here 9 months postoperatively. The hallmarks of the HTA effects are evident: the scar rests in a hidden position, the suprapubic skin is not overly tight, and the thigh and hip regions have been lifted. The closeup picture of the thigh reveals the qualitative improvement of the skin that extends practically to the knee.

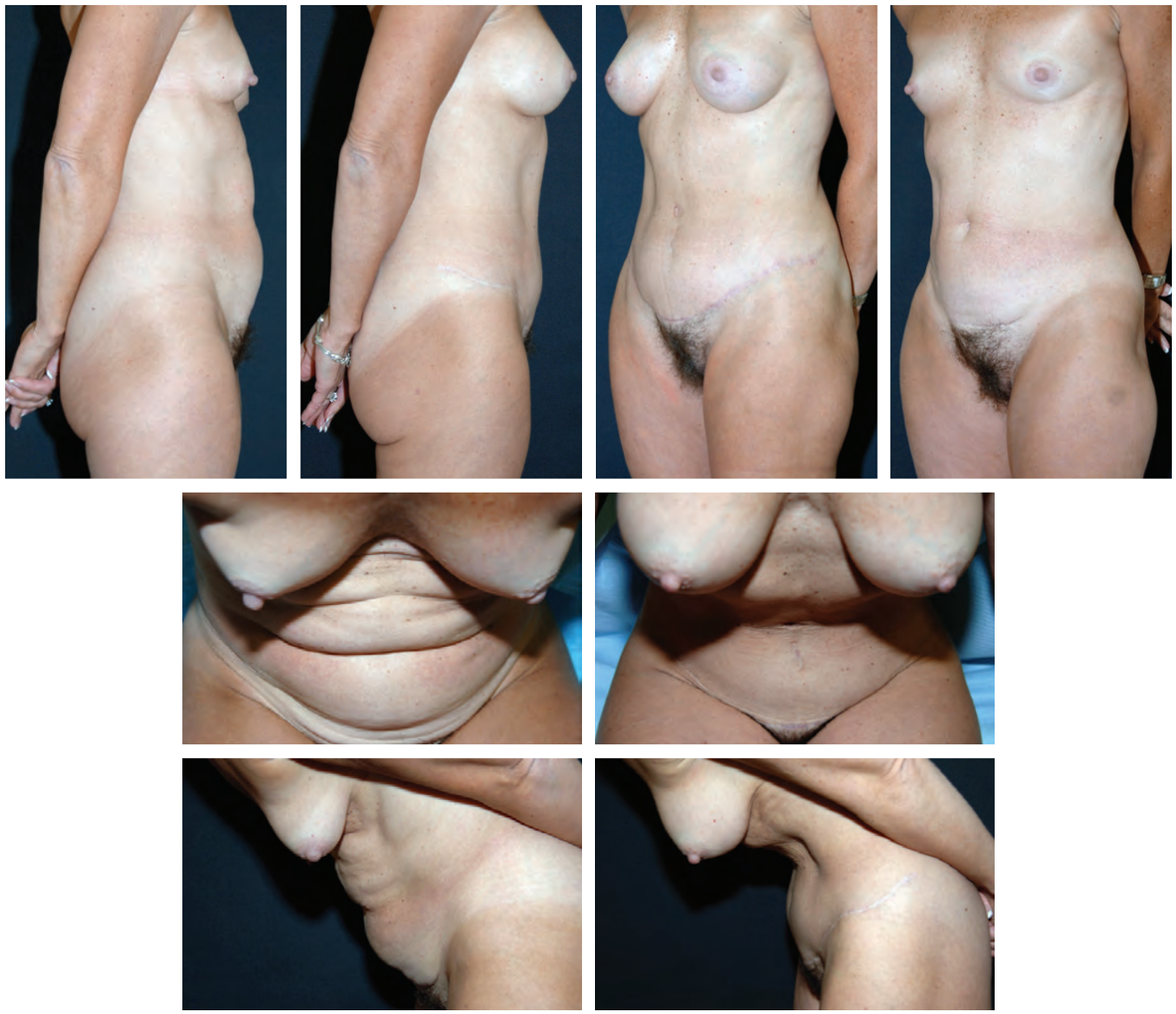

Fig. 7-14

Th s 50-year-old woman (gravida 1, para 1) desired rejuvenation of her abdomen. She underwent HTA with liposuction of the hips and lateral thighs as well as augmentation mammoplasty. The pleasing aesthetic of the abdominal repair is realized with a well-placed scar, a suprapubic region that is not overly tight, and an improved hip/thigh contour. Note the stealth skin redundancy, which is visible when the patient is sitting and bending, and its repair postoperatively. However, as expected, residual skin persists in the epigastric area postoperatively.

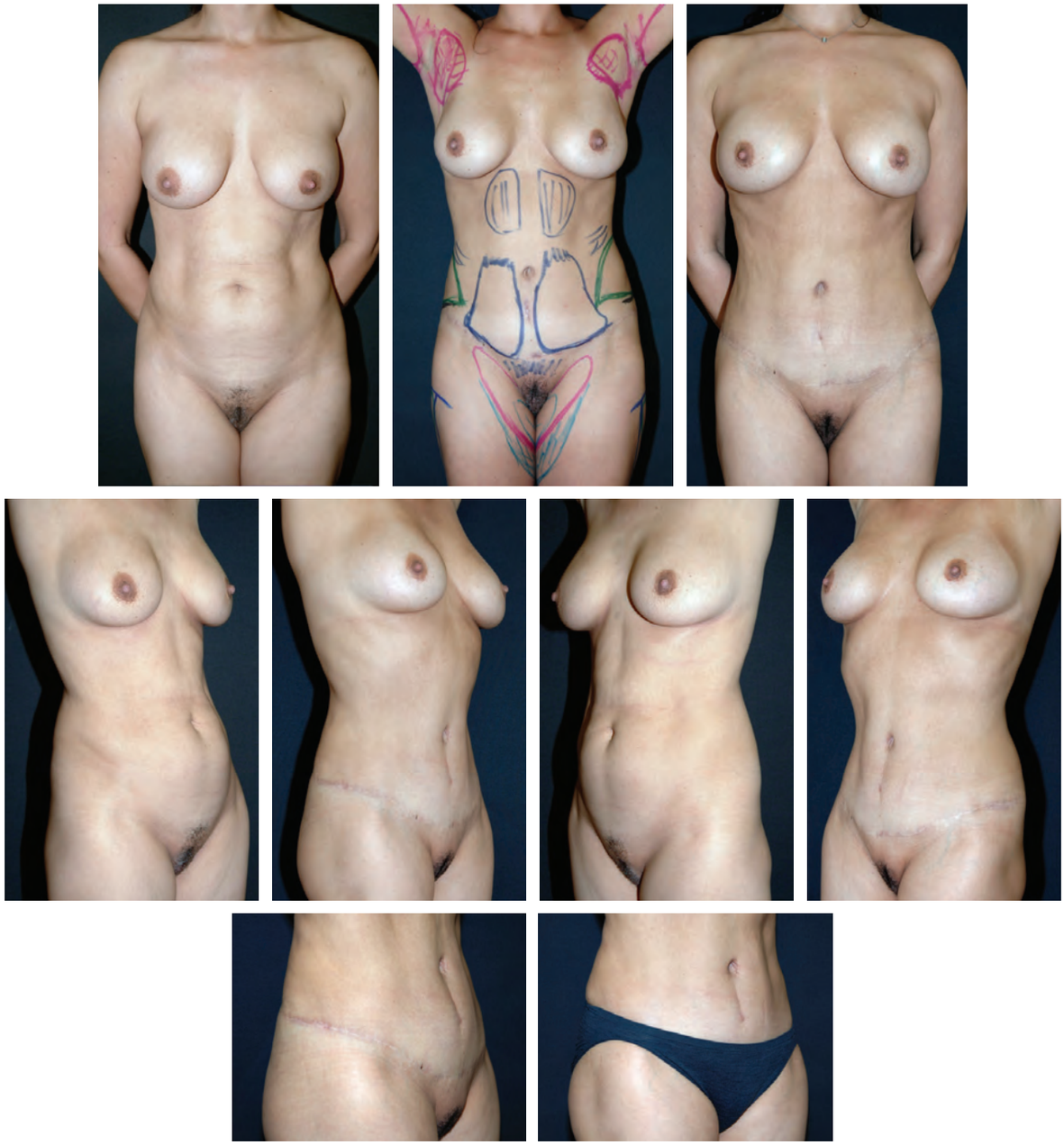

Fig. 7-15

Th s 35-year-old woman (gravida 1, para 1) presented for correction of her abdominal protrusion as a result of abdominal wall laxity and lipodystrophy. She had a similar excess of skin when bending over or sitting. The patient underwent a first-stage HTA with a planned second-stage liposuction of the entire trunk. The benefits of this technique are demonstrated with the return of a prepregnancy abdominal contour. As planned, the scar is properly hidden within the patient's underclothes.

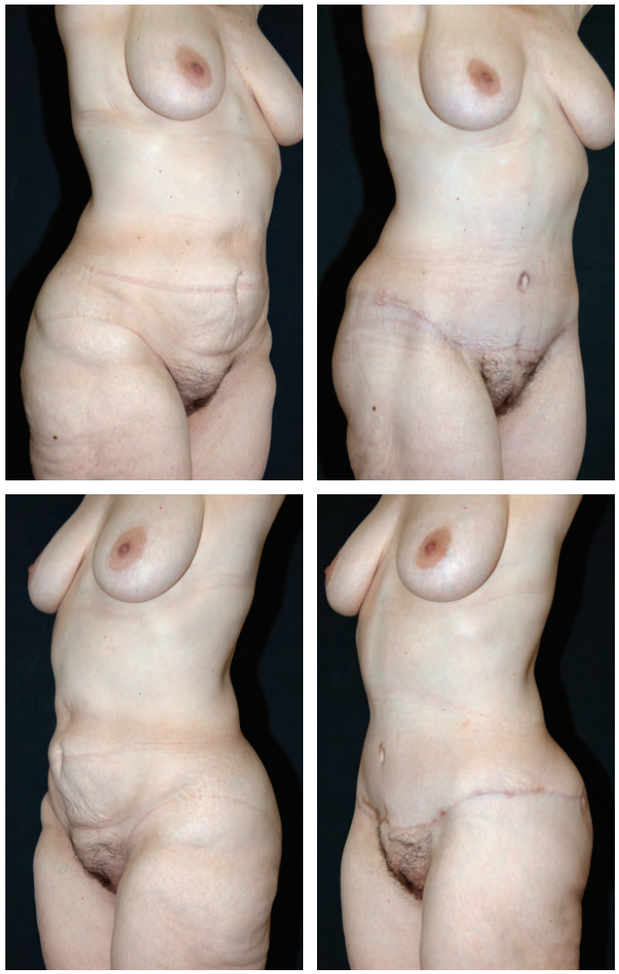

Fig. 7-16

Th s 43-year-old nulliparous woman achieved a signifi ant weight loss of more than 45 kg (100 pounds) after gastric bypass surgery. She underwent HTA with liposuction of the hips and thighs. Again, note the lift nd correction of the lateral thigh/buttock region through a well-placed scar.

Fig. 7-17

This 37-year-old woman (gravida 3, para 3) presented with the complaint of residual abdominal deformity despite aggressive diet and exercise. She is 1.6 m (5 feet 3 inches) tall and weighs 70 kg (155 pounds). She underwent HTA with aggressive liposuction of the hips and thighs. Note the relative lift seen at the buttocks and thighs. As planned, the productive (albeit lengthy) incision scar is hidden within the patient's underwear.

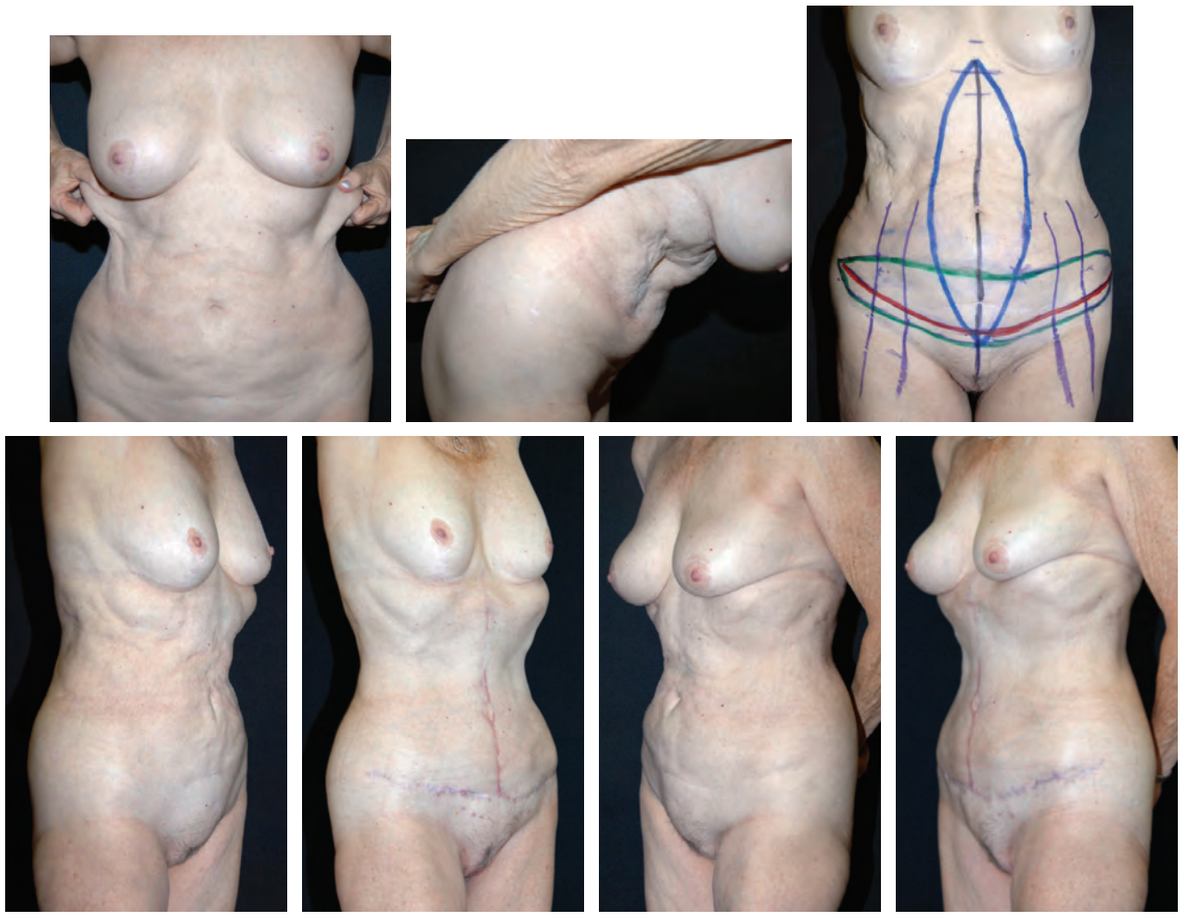

Fig. 7-18

Th s fit 65-year-old woman (gravida 2, para 2) desired better contour and the maximal correction of her abdominal redundant skin and protrusion. Th s case demonstrates the power of integrating the fleu -de-lis design into the HTA approach to more fully improve the patient's shape. Note the excess stealth skin that becomes more obvious with a change in position or when put under tension. The patient's aesthetic habitus afforded the full effect of the fleu -de-lis design to be expressed, with a particularly dramatic improvement seen in her pubis, waist, upper abdomen, and back folds. In addition, the patient's posture appears to have improved.

Fig. 7-19

Th s 46-year-old woman (gravida 4, para 4) presented for abdominal repair after bearing her children. HTA was performed in addition to mastopexy and augmenta-

tion. The patient is shown 4 years postoperatively, and these images reveal significant lateral excision with this technique. The benefits of HTA with a more aesthetic waistline and a smoother epigastric zone are apparent.

Problems and Complications

The raison d'être of the HTA design is to deliver as much correction as possible with the lowest complication rate. Like Lockwood's original opus, this 2.0 upgraded version described here is predicated on zero tolerance for complications. Many of these outcomes are not really complications but rather planned tradeoffs for either better or safer results. Preoperative surgical disclosure is clearly valuable: when a patient is informed of an expected residual deformity, he or she will consider it part of the surgical plan rather than a complication. If any secondary surgery is needed, the patient will then appreciate it as a stage rather than a revision. Thus, the HTA technique evolved with guidance by the philosophy of simply confronting those complications that were unacceptable—irreversible aesthetic mistakes (misplaced scars) or devastating physiologic misadventures (flap necrosis)—and instead, choosing those that were self-limiting or easily correctable. The following sections highlight some of these complications and explain how the HTA has evolved to treat and conquer them.

AESTHETIC COMPLICATIONS

Abdominal Scar Too Long

The scar can only be considered too long if the patient was not clearly informed of its often requisite length. The lateral scar is the primary literal footprint of the HTA. If any tension lifting is attempted at the lateral thigh and hip area, the incision will, of necessity, grow longer. The surgeon should critically evaluate this anatomy preoperatively and decide, with the patient's input, whether there is enough laxity to warrant extending the incision. Experience otherwise indicates that—as long as it is of good quality, corrects the deformities, and, most importantly, remains hidden—the patient will always be accepting of a lengthier scar.

Lateral Scar Too High or Too Low

In general, the greater the amount of excess skin present, the more unpredictable the scar placement will be. Poor marking design is usually to blame, and this usually involves an overestimation or underestimation of the magnitude of skin redundancy below the incision. There are several ways to avoid this problem, depending on the extent of the redundant skin:

- If there is signifi ant excess of skin below the incision, then there is a real danger of an incomplete resection and a resulting high-riding scar. Thus the surgeon must be sure to capture all excess during the marking by placing the skin under maximum tension. And like any good tailor, the surgeon must remember to measure twice and cut once. The markings can be tested and the future scar can be visualized by having the patient pull on the excess tissue to re-create the prospective lift
- If there is a modest excess of skin below the incision (usually in the thicker, less mobile skin envelope) but too much skin is still marked and removed, the scar will predictably rest too low. Therefore, in this instance, the surgeon should place the skin under a modest amount of tension when marking.
- The preoperative measurement of the distance between the fi ed ASIS and the desired level of the fi al wound may be used as an additional "excisional" guide intraoperatively. In addition, because the thigh skin below may drift inferiorly postoperatively, it is best to be conservative with further skin excision.

Disproportionate Pubis

The pubis may appear out of proportion postoperatively; this is usually caused by inaccurate estimation of the true redundancy of the pubic area. The surgeon must put the pubis under maximum stretch during marking but leave at least 6.5 cm of pubic height to avoid creating a mons that is too tall or too short. The mons can also be left oo wide. If necessary, to prevent this appearance, a wedge resection of the pubis can be conducted concomitantly or at a later stage. However, overcorrection must also be avoided, leaving the mons too narrow, by maintaining a width of at least 6.5 cm. In addition, an adjuvant preventative strategy in the more mobile mons is to place stabilizing sutures to fix its posture before fi al wound closure.

Poor Umbilical Closure Scar

A poor scar from closure of the umbilicus is the most feared (more by the surgeon rather than the patient) but the least realized problem. These scars uniformly resolve into short, thin, white lines. A steroid injection or a revision procedure will occasionally be necessary. Even so, as the patient is made aware, this 2.5 cm scar is a small price to pay for the prevention of the alternative: an ectopic abdominoplasty scar that resides too high and drags the pubis along with it.

Residual Fat at the Central and Superior Abdomen

Residual fat should more accurately be considered a deliberate eschewing of the subcutaneous tissue to preserve the maximum blood supply to the central flap. The surgeon must decide what his or her individual tolerance is for the very real complications that may ensue with attempts to remove this fat at the fi st surgery. With the HTA 2.0, the patient is found to be best served with a second-stage unfettered abdominal liposuction procedure.

Residual Skin at Upper Abdomen

Residual skin is really not a unique complication of the HTA. There is a good argument that, because this technique delivers a more oblique vector of pull, more of this redundancy can actually be effac d. However, the patient with a very significant upper abdominal excess (a second pannus) should be informed of its probable persistence postoperatively. Otherwise, only a fleu -de-lis procedure or a reverse abdominoplasty can treat this zone defin tively.

Lateral Dog-Ears

The best way to avoid dog-ears is to fully liposuction this area and to intrepidly extend the incision as much as necessary. Otherwise, a revision can easily be accomplished with a local anesthetic.

Epigastric Recurrent/Residual Protrusion

As a result of the HTA's deliberately more conservative upper abdominal dissection, in the very protuberant patient, a commensurately more constrained plication is necessary. Although it is rare, a postoperative epigastric recurrence or a residual deformity is a possible but acceptable trade-off.

PHYSIOLOGIC COMPLICATIONS

Superficial Fascial System Suture Abscesses

The suture that is used for the tension closure of the fascia is, of necessity, of a larger caliber, and it usually contains abundant knots. As a result, a suture abscess may arise, often at a surprisingly late postoperative stage. Th s problem is far less likely if absorbable suture is used.

Seroma

The efficacy of progressive tension sutures for reducing seroma rates has been well described, and these sutures have proven to be equally efficacious in the HTA 2.0. In

addition, rarely, if a seroma does occur, it is usually "compartmentalized," conducive to easy aspiration and quick resolution. Also, preservation of abdominal suprafascial and inguinal lymphatic tissues are effective adjuvant strategies.

Deep Vein Thrombosis and Pulmonary Embolism

Tomes of analysis and advice have been written about deep vein thrombosis and pulmonary embolism, particularly during the past few years. With good patient selection, the consistent use of antiembolism pumps, and early mobilization, the incidence of these problems should remain rare. Considering the still unsettled status of the use of chemical prophylaxis, the surgeon should refer to the latest recommendations in the literature. However, at the time of this writing and until this subject is sorted out, a few observations can be made:

1. A Caprini-type risk assessment should be performed preoperatively for all patients.
2. In addition, there is anecdotal evidence that spinal anesthesia may be an even more reliable method of prophylaxis (A. Aly, personal communication, 2011).
3. That said, because these surgeries are, after all, elective, in the unambiguously riskiest candidate, the obese patient, the surgeon should consider the most effective strategy for the prevention of this life-threatening problem: to simply elect not to operate.

Skin Necrosis

Necrosis is a dreaded complication that will consistently occur if the surgeon goes too far during surgery by:

- Performing excessively aggressive flap mobilization and attendant destruction of one too many nourishing perforators
- Resecting too much skin and creating excess tension during wound closure
- Conducting overly zealous fat removal from the flap and compromising the subdermal plexus

It is regrettable that the patients who would seemingly be the best candidates for these extreme measures are also often the riskiest candidates (that is, those with the highest BMIs). Surgeons must therefore decide for themselves their personal thresholds when considering the proverbial conflicting forces of blood and beauty. However, as has been abundantly elucidated, the HTA 2.0 approach has been purposely designed to prevent this problem. Specifically, its antipodal strategies to each of the previously listed maneuvers include discontinuous dissection, preservation of suprapubic skin, and planned second-stage lipocontouring.

Critical Decisions and Operative Nuances

- HTA is driven by the concerted effort to treat not only the tissues above the incision but also those below the incision. Th s procedure is as much the excision of abdominal redundancy as it is a far-reaching body lift through an extended anterior incision. The pubis and the anteromedial thighs as well as the hips, the anterolateral thighs, and even the buttocks can be aesthetically improved with the use of this technique.
- Th s procedure is fundamentally different from traditional abdominoplasty in that the skin is considered more redundant at the lateral trunk than in the midline. Therefore, when this technique is applied, the anterolateral abdomen and the thighs are treated more effectively. Remarkably, the treatment of the central excess of skin is equally as complete with both procedures. This is because the redundant upper abdominal skin represents a more horizontal laxity that is more efficaciously treated with the oblique pull of the HTA than the fully vertical traction of the traditional abdominoplasty.
- Th s approach is not driven by the usually mandatory excision of all of the skin between the pubis and the umbilicus. Therefore, the wound closure will enjoy less tension, thereby improving the chances for per primam healing and better scarring as well as a more natural-looking result at the pubis, with the incision resting in a lower and more hidden position.
- HTA often mandates that the incision be longer laterally. However, it is also true that the longer the lateral incision is, the better the results will be. Th s approach allows the excision of a greater extent of skin. Th s balance between the scar length and the procedure's results must be negotiated with the patient. However, as long as the "deformity" is corrected and the scar is of good quality and hidden, the patient will generally be sanguine about its length.
- As a corollary, if there is a less redundant skin envelope at the lateral thigh, then HTA should be tempered, and the scar can and should be shorter laterally.
- Although this technique is more effective for the treatment of upper abdominal skin excess, it should still be supplemented, when indicated, by a second-stage reverse abdominoplasty procedure. If the excess is overwhelming, this procedure is best supplanted with a fleu -de-lis type of abdominoplasty.
- HTA is predicated on the preservation of the flap's blood supply. As part of this philosophy, for the patient with a higher BMI, the surgeon should seriously consider a staged liposuction of the central and superior abdominal flap. Only then can zero tolerance for skin necrosis be truly respected.

Selected Readings

Caprini J. Effective risk stratification of surgical and nonsurgical patients for venous thromboembolic disease. Semin Hematol 38:12, 2001.

Gradinger GP, Rosenfield LK, Nahai FR. Abdominoplasty. In Nahai F, ed. The Art of Aesthetic Surgery: Principles and Techniques, ed 2. St Louis: Quality Medical Publishing, 2011.

Hunter C, Rosenfield L, Silverstein E, et al. Methicillin-resistant Staphylococcus aureus infections: a comprehensive review and a plastic surgeon's approach to the occult sites. Plast Reconstr Surg 138:515, 2016.

Lockwood T. High-lateral-tension abdominoplasty with superficial fascial system suspension. Plast Reconstr Surg 96:603, 1995.

Matarasso A. Abdominolipoplasty: a system of classification and treatment for combined abdominoplasty and suction-assisted lipectomy. Aesthetic Plast Surg 15:111, 1991.

Naghshineh N. Nutritional assessment of bariatric surgery patients presenting for plastic surgery. Plast Reconstr Surg 126:602, 2012.

Pitanguy I. Abdominal lipectomy: an approach to it through an analysis of 300 consecutive cases. Plast Reconstr Surg 40:384, 1967.

Pollock H. Progressive tension sutures: a technique to reduce local complications in abdominoplasty. Plast Reconstr Surg 105:2583, 2000.

Rosenfield LK. Commentary on: Safety of aesthetic surgery in the overweight patient: analysis of 127,961 patients. Aesthet Surg J 36:730, 2016.

Rosenfield LK. High tension abdominoplasty 2.0. Clin Plast Surg 37:441, 2010.

Saldanha OR, De Souza Pinto EB, Mattos WN Jr, et al. Lipoabdominoplasty with selective and safe undermining. Aesthetic Plast Surg 27:322, 2003.

Samra S. Complication rates of lipoabdominoplasty versus traditional abdominoplasty in high-risk patients. Plast Reconstr Surg 125:683, 2010.