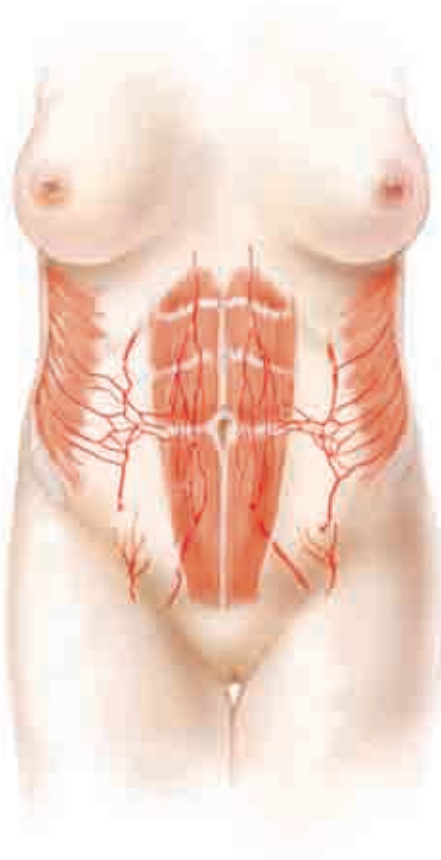

## CHAPTER 83



# Abdominoplasty



GILBERT P. GRADINGER,  
LORNE K. ROSENFELD, FARZAD R. NAHAI

**A**bdominoplasty is performed to correct soft tissue abnormalities of the anterior trunk, from the lower border of the ribcage to the inguinal and pubic areas. Body contour problems involving the fat and skin of the lateral and posterior truncal regions are treated with liposuction and extended dermolipectomy.

Plastic surgeons who perform abdominoplasty have recognized that variations in abdominal contour require modifications in surgical procedure. Newer techniques require shorter incisions and eliminate umbilical circumscription. In the past, patients who sought contour reduction had only one choice—abdominoplasty. Today superior aesthetic results can be achieved in many patients with liposuction alone. Liposuction combined with abdominoplasty has enhanced our ability to achieve better results. Small fat deposits, which cannot be treated with abdominoplasty, are ideal for liposuction, which is associated with insignificant scarring, minimal inconvenience, and negligible morbidity. On the other hand, treatment of a massive-weight-loss patient mandates more aggressive and advanced techniques to repair this multifaceted deformity.

Plastic surgeons now have a much wider range of choices for operative correction of the many abdominal deformities, including the following:

- Liposuction alone
- Complete abdominoplasty with or without umbilical translocation
- Lower abdominoplasty
- High lateral tension abdominoplasty
- Fleur-de-lis abdominoplasty
- Reverse abdominoplasty

Surgery may involve one option, a variation on an option, or a combination of options.

## Indications and Contraindications

The typical abdominoplasty patient is a woman (although increasingly men are also seeking treatment) who has had one or more full-term pregnancies and a subsequent loss of youthful abdominal contour. Most of these women have tried exercise and dieting but have been unable to regain their prior shape. Obesity may or may not be

a factor. Usually an excess of fat is present. The skin of the abdomen is stretched from pregnancy weight gain and subsequent weight loss. Dermal breakdown, as evidenced by stretch marks, is often present. The quality of the lower abdominal skin often determines the relative roles of surgical lipectomy versus liposuction. The status of the underlying fascia and abdominal wall muscles also dictates which surgical approach is indicated.

The patient criteria to be considered must be exhaustive if the surgeon is to avoid major complications and patient dissatisfaction. The elements of a successful abdominoplasty include the following:

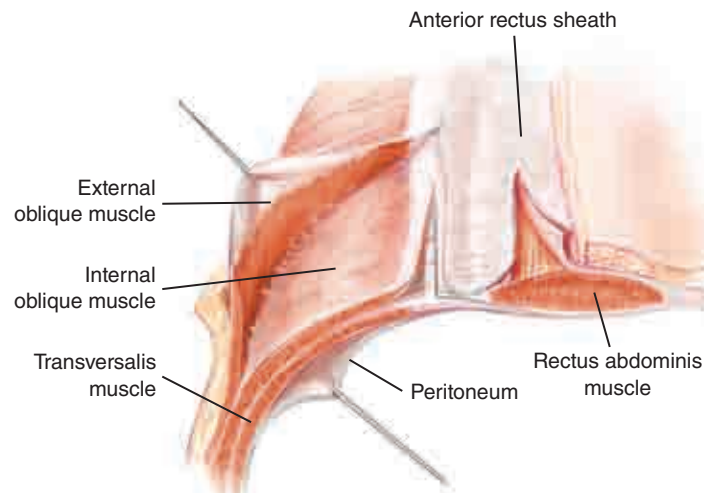
- **Weight:** Stable for more than 6 months and not grossly overweight (BMI less than 30)
- **Medical condition:** No major medical issues such as labile hypertension, diabetes, or coronary artery disease
- **Psychological state:** Well motivated and realistic (for example, postpregnancy or gastric bypass patients)
- **Habits:** Regular exercise, reasonable diet, and no smoking or excess alcohol consumption
- **Anatomy:** Absence of multiple abdominal scars and no extreme abdominal protrusion (secondary to intraabdominal fat accumulation)

## Pertinent Anatomy

FARZAD R. NAHAI

When considering aesthetic procedures of the abdomen, the surgeon must be thoroughly familiar with the anatomy of the abdominal wall. A clear understanding of the blood supply and soft tissue layers is critical when planning incisions, determining the amount of tissue to be resected, and deciding whether concomitant liposuction or lipectomy is indicated. It is also important when managing the umbilicus and calculating the degree of flap elevation, especially in patients who have had prior abdominal procedures. The specific anatomy most relevant to the understanding and application of these complementary techniques includes the zones of adherence, the superficial fascial system, and the blood supply remaining after each approach.

## Soft Tissue Layers of the Abdominal Wall

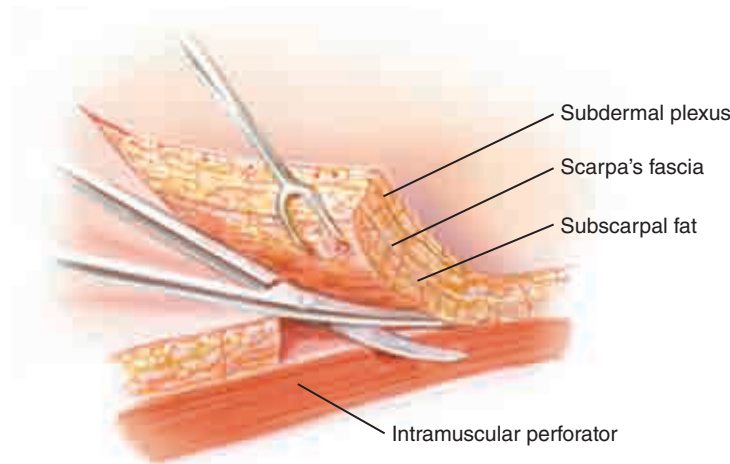


The abdominal wall is composed of six distinct soft tissue layers: skin, subcutaneous fat, subscarpal fat, anterior rectus sheath, muscle, and a posterior rectus fascia. It spans the area between the costal margin, midaxillary line, iliac crest, and symphysis pubis—a sort of elongated hexagon. The layers of the abdominal wall are consistent in their relationship to each other; the variability occurs with regard to the quality of the tissues and amount of fat present.

### Skin

The skin of the abdomen receives its blood supply from multiple muscle and fascial perforating vessels that feed a subdermal vascular plexus. Depending on multiple patient characteristics (such as age, BMI, and number of full-term pregnancies), the skin of the abdomen can have differing degrees of elasticity. Often, the skin of the patient being considered for abdominoplasty is stretched, demonstrating poor elasticity and multiple striae. These striae are surface evidence of attenuated or absent underlying dermis. The location and extent of striae should be considered when planning skin incisions, because at the time of closure these areas of poor or absent dermis are more difficult to close and are at risk for separation. The surgeon should attempt to place skin incisions on the abdomen in such a way that the resultant scars will be covered by the patient's choice of undergarments.

## Fat

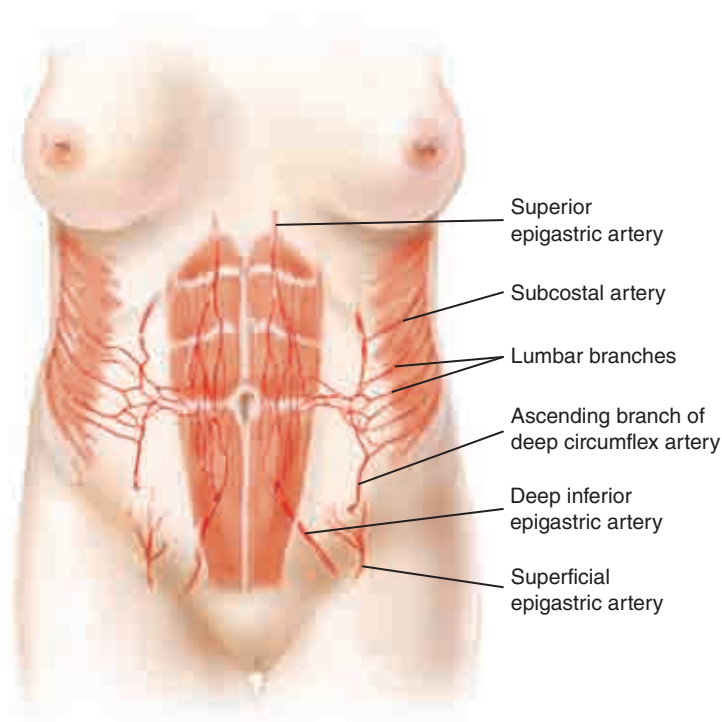


The adipose layer of the abdominal wall can be divided into two layers—superficial and deep—based on Scarpa's fascia. The superficial fat layer has a more robust blood supply, is usually thicker, and has a more dense and durable type of fat. Its vascular supply is from both the subdermal plexus and the underlying musculocutaneous perforators. The deeper layer of fat is typically less dense and receives most of its blood flow from underlying muscle, making it more prone to ischemia during abdominoplasty. This difference in blood supply to the superficial and deep layers of fat is an important factor to consider during lipectomy of the abdominal flap. Because the anterior abdominal wall fat deep to Scarpa's fascia is not involved in supplying circulation to the skin, it may be excised during an abdominoplasty. Conversely, preservation of subcutaneous fat superficial to Scarpa's fascia is crucial to survival of the overlying skin.

## Muscle and Fascia

There are four principal paired muscle groups of the abdominal wall: the rectus abdominis, external oblique, internal oblique, and transversalis. The common purpose of these muscle groups is to support the abdominal contents, assist in breathing, and permit the flexion/rotation of the thorax and pelvis. The external oblique, internal oblique, and transversalis muscles form the anterolateral wall of the abdomen, spanning the costal margin to the midline. The rectus abdominis originates on the anterior surface at the lower midline of the rib cage and inserts on the symphysis pubis. The aponeurotic portions of the oblique and transversalis muscles envelope the rectus abdominis and blend in the midline to form the linea alba, a dense confluence of fascia that separates the left and right rectus muscles. The arcuate line is a transition point above which the external oblique and a superficial division of the internal oblique form the anterior rectus sheath, while the deep division of the internal oblique and the transversalis composes the posterior rectus sheath. Below the arcuate line, approximately midway between the umbilicus and symphysis pubis, the transversalis aponeurosis, along with the deep division of the internal oblique muscles, progressively transfers to the anterior fascial layer, leaving only the preperitoneal fat between the rectus muscle and the underlying peritoneum.

## Blood Supply



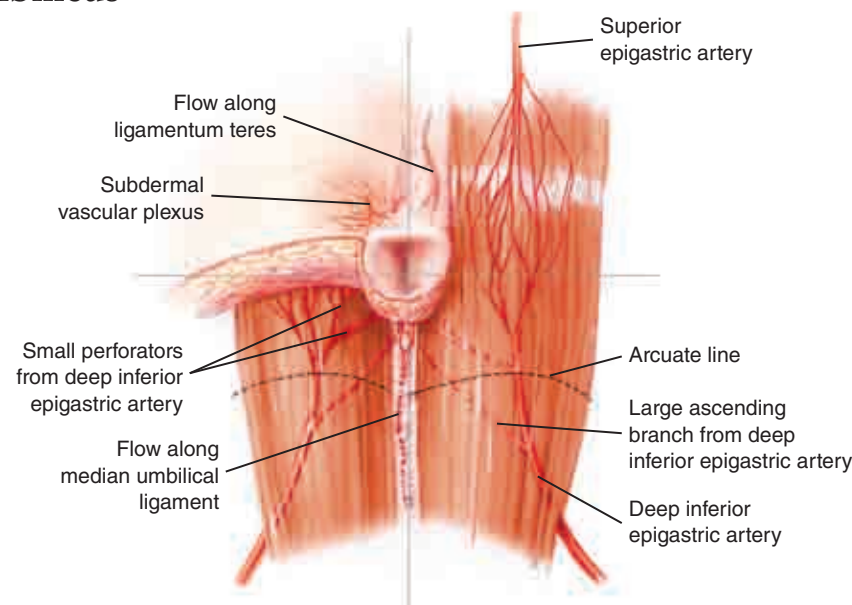
The blood supply to the muscles, skin, and fat of the abdominal wall comes from numerous major arteries of the thorax and pelvic region. These arteries exhibit many anastomotic interconnections that are important for abdominoplasty. Understanding their origins and routes is essential to avoiding ischemic complications.

For the purposes of this discussion, it is helpful to consider the blood supply to the abdominal wall from two areas: one that is superolateral in origin and the other that is inferior in origin. Superiorly, the superior epigastric artery, a branch of the internal thoracic artery, enters the posterior rectus sheath on its way into the rectus abdominis muscle as it emerges from the costal margin immediately lateral to the sternum. As it enters the rectus, it is situated medially in the muscle. It then perforates the rectus abdominis muscle, branching as it descends within the muscle until it anastomoses with the deep inferior epigastric artery. Perforators through the anterior rectus sheath, more densely present in the periumbilical area, supply the abdominal skin and fat overlying the muscle.

The other terminal branch of the internal thoracic artery is the musculophrenic artery, which passes inferolaterally deep to the ribs at the costal margin where it anastomoses with the lower and posterior intercostal vessels (direct branches of the aorta) at the last intercostal space. These posterior intercostal vessels travel between the transversalis and internal oblique muscles and have collateral, muscular, and cutaneous branches. Caudal to these are the subcostal and lumbar arteries, both dorsal branches of the thoracic aorta, which contribute to this anastomotic network of vessels that course between the transversalis and internal oblique muscles.

It is within this intermuscular space that one of the anastomoses between the superolaterally based vasculature and inferiorly based vasculature exists. The ascending branch of the deep circumflex artery, a branch of the external iliac artery, originates from the iliac crest and ascends to the aforementioned anastomotic network. The two other principal inferiorly based vessels are the paired deep inferior epigastric arteries (DIEAs), a branch of the external iliac artery, and the superficial epigastric arteries, a branch of the femoral artery. The DIEA travels superomedially from its origin, pierces the transversalis fascia, and runs along the posterior border of the rectus abdominis muscle before entering it. Once in the muscle, it branches on its way cephalad to anastomose with the branches of the superior epigastric artery. The principal perforators to the skin, on average five per side, emerge through the anterior rectus sheath more densely in the periumbilical region. These perforators receive more inflow from the DIEA than the superior epigastric artery. The superficial epigastric artery arises from the common femoral artery, 1 cm distal to the inguinal ligament at its midline, and ascends within the superficial abdominal fascia and fat toward the umbilicus. It often arises as a common trunk with the superficial circumflex iliac artery, superficial external pudendal artery, and deep circumflex iliac artery.

## The Umbilicus



The umbilicus is an aesthetically important surface structure of the abdomen. It is typically situated approximately 14 cm above the symphysis pubis in the midline, or 10 cm above the pubic hair (at the level of the iliac crest). The aesthetically pleasing umbilicus is shallow, has a thin superior skin hood, and is round or ellipsoid in shape. Blood flow to the umbilicus is from the subdermal plexus, in addition to three distinct sources: the principal supply is from branches of the right and left DIEAs; additional flow is from the ligamentum teres and the median umbilical ligament. Multiple branches of the DIEA ascend between the rectus muscle and the posterior rectus sheath on their way to the umbilicus. In a morbidly obese patient, the stretching and

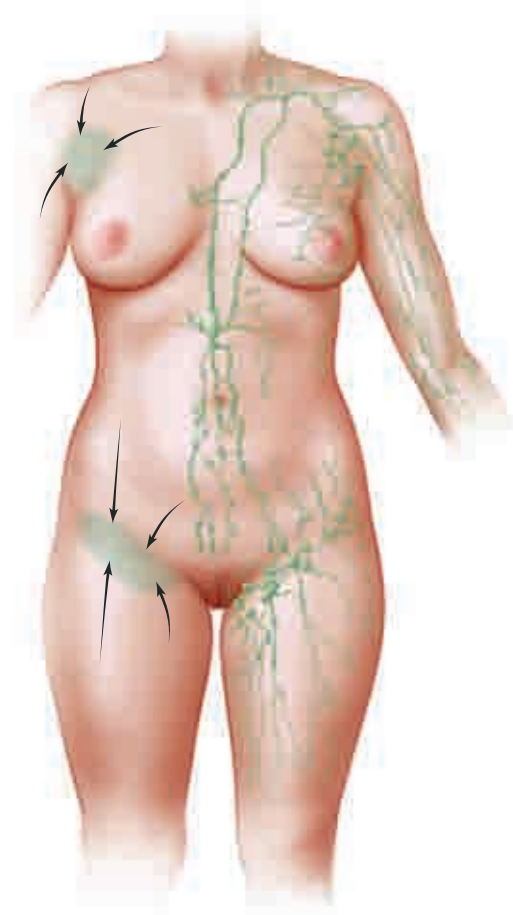


descent of the tissues distorts the vascular anatomy and the umbilicus is elongated. Extra caution should be exercised when dissecting the umbilicus in these cases. The fascia around the umbilicus can be weak with a resultant umbilical hernia. Care should also be taken to dissect around the hernia sac to avoid bowel injury.

## Nerves

Cutaneous sensation of the abdomen is derived from the lateral cutaneous and anterior cutaneous branches of intercostal nerves T7 through T12. The lateral cutaneous branches perforate the intercostal muscles at the midaxillary line to travel within the subcutaneous plane. The anterior cutaneous branches travel between the transverse and internal oblique muscles to penetrate the posterior rectus sheath lateral to the rectus muscle before entering the rectus muscle on their way to the overlying fascia and skin.

The anatomy of the lymphatic system of the abdominal wall is important, because it is clinically related to the occurrence of serous fluid accumulation and edema after abdominoplasty. A plexus of lymphatic vessels resides within the subscarpal fat layer just superficial to the anterior rectus sheath. Below the umbilicus, the lymphatic system drains inferiorly via the femoral route. Above the umbilicus, this system drains cephalad in the superficial plane to the axilla on its way to the thoracic duct.



Le Louarn and Mustoe published favorable results demonstrating that preservation of the suprafascial network of lymphatics (in addition to use of a quilting suture, in Le Louarn's case) diminishes time with a drain, and both stated that postoperative serous drain output, seromas, and abdominal flap swelling is diminished.



## Preoperative Assessment

### LORNE K. ROSENFELD

A comprehensive examination is crucial to enable the surgeon to properly prepare the patient and accurately plan surgery.

### Physical Examination

The physical exam should include evaluation of all “layers” of the abdominal wall: the skin, the subcutaneous fat, and underlying fascia/muscle (with an indirect assessment of the extent of intraabdominal fat).

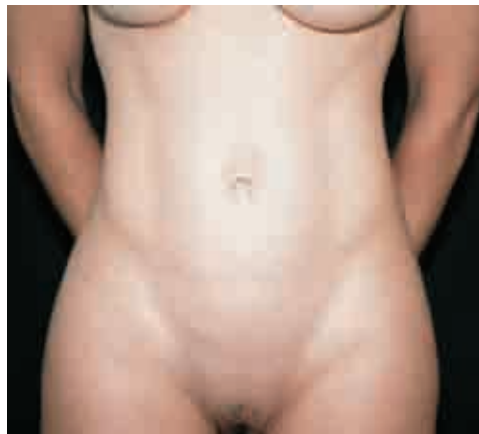#### *Skin*

The skin examination should involve much more than just the assessment of the classic pannus of excess lower abdominal skin above the pubis.

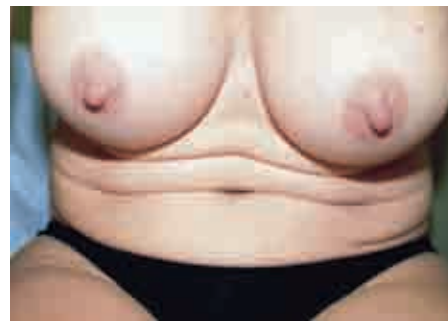#### *Striae*

The boundaries of striae are assessed. It should be duly noted and explained to the patient the extent of the striae that may not be included in the resection (particularly those above the umbilicus).

#### *Excess Skin*



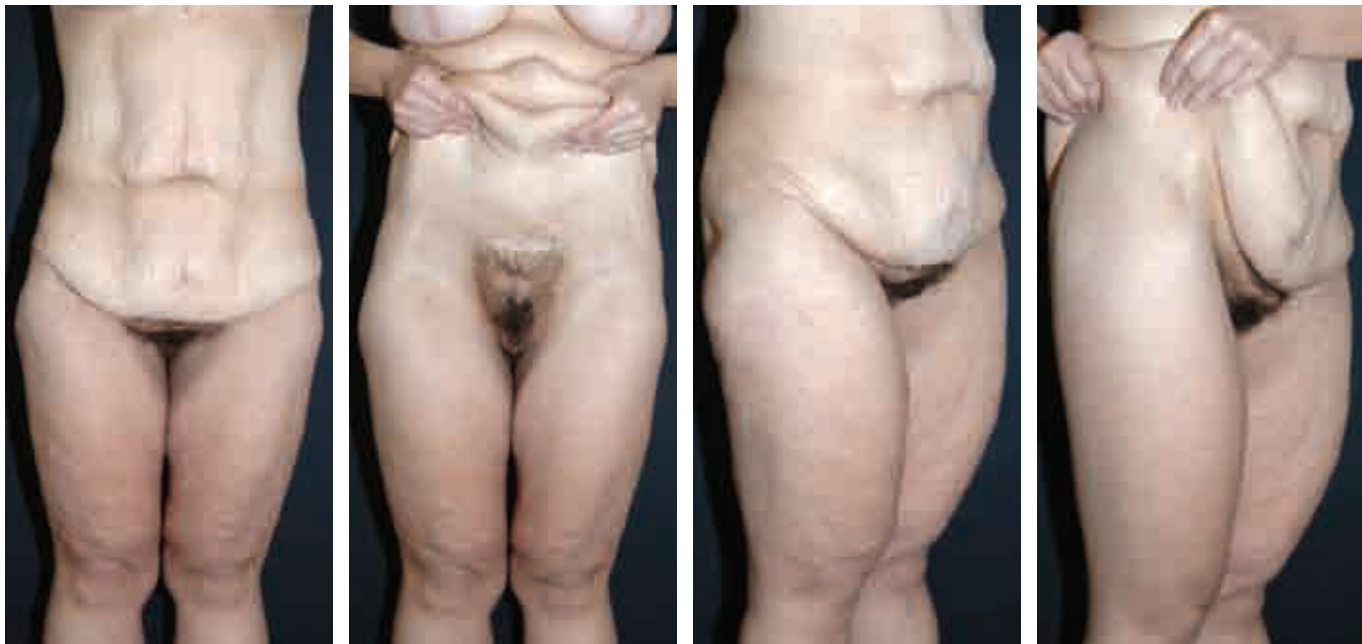Standing, this patient ostensibly has little excess skin



Same patient in relaxed sitting position

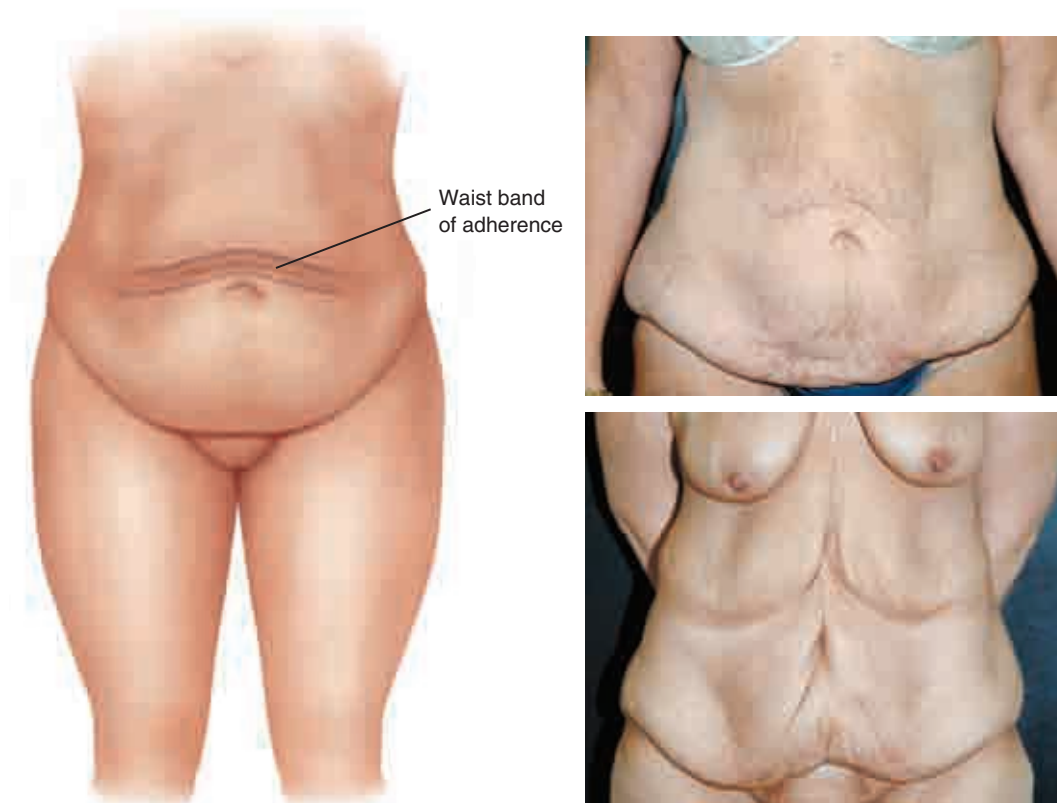The extent of obvious anterior redundant skin (width of the pannus) is noted first. This evaluation determines the initial estimation of the length of the incision. However, a proper assessment must be made beyond the obvious excess lower abdominal pannus if a more complete correction is to be made at the entire anterior trunk “aesthetic unit”; that is, the extent of redundancy is evaluated not only above the inguinal area but also below the incision, at the hips, thighs, and pubis. If there is particular excess at the lateral thighs, then the incision will, necessarily be appreciably

longer, if the high lateral tension abdominoplasty (HLTA) approach is to be properly applied. On the other hand, if the patient demonstrates minimal excess laterally, then significant tension should not be planned, for fear of making the incision unnecessarily longer.



Any excess skin at the upper abdomen should be noted. Here there may be what may be called a secondary roll or wall of cascading skin, which really represents a migration of redundancy from the chest rather than the abdomen. Consequently, usually not all of this upper abdominal skin can be removed from the suprapubic approach. It is of greater value to conduct this examination with the patient not only in the supine and standing positions, but also when *sitting and bending over*. This is often the only posture in which one can see the areas of redundancy in a patient who demonstrates what appears to be primarily abdominal wall protrusion. Of equal importance, the mobility or what may be called the “translation” of the skin should be assessed, because it can be very telling: the looser the skin, the better the result.

## Adhesions



The surgeon should note any adhesions of the skin at the thighs and abdomen proper. Although not previously described, adhesion can also be found at the level of the waist, particularly laterally: a waistline zone of adherence and contraction. In fact, there is most often what one may call a second roll of excess skin resting above this “valley,” most notably in the larger or weight-loss patient. This band essentially divides the abdominal excess skin into superior and inferior segments. The surgeon must be aware that this adhesion of tight skin will reliably resist the surgeon’s efforts to efface this upper abdominal excess. And because this zone harbors vital perforators, only a judicious release of the area by discontinuous undermining should be attempted. Otherwise, this upper abdominal redundancy is best addressed with either a fleur-de-lis-type abdominoplasty or a second-stage reverse abdominoplasty.

## Scars

Any scars at the abdomen are assessed. Of greatest concern are those at the subcostal and midline areas. These scars require the surgeon to map out the safest and most effective surgical approach. For a subcostal scar, it is best to restrict the amount of undermining in this area and if possible even include this scar in the resection with a fleur-de-lis approach. Similarly, the upper midline scar presents a challenge. Either a fleur-de-lis-type pattern or a reverse abdominoplasty should be considered. Otherwise, the risk of abdominal flap necrosis is too high. Finally, if there is a full-length midline scar, the fleur-de-lis template is ideal.

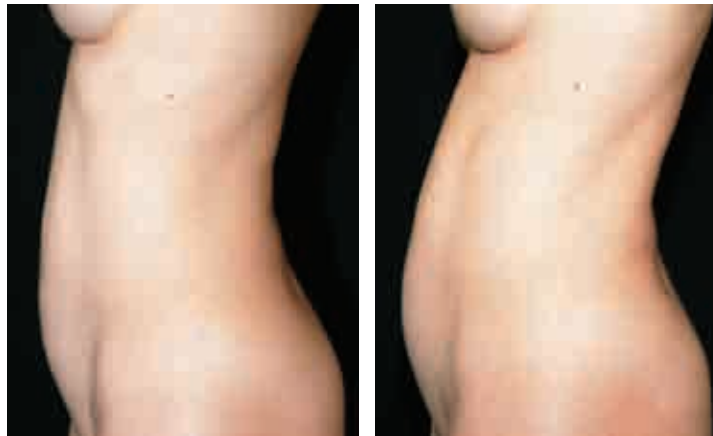### ***Subcutaneous Fat***

#### **Thickness of the Envelope**

A topographic sense of the extent of underlying fat must be defined. This mapping will guide where liposuction could be conducted—and just as important, where it should not be performed. Usually contouring of the waist, hips, and lateral thigh accentuates the abdominoplasty's shaping affects and assists the HLTA by facilitating the translation of pull of the skin with its liposuction-induced discontinuous dissection. If the central flap is very thick with fat, it is best to inform the patient that a second-stage liposuction surgery may be necessary to complete the repair safely.

### ***Abdominal Wall***

#### **The Location and Extent of Protrusion**



The patient is asked to relax the abdominal wall

The degree of lower abdominal wall relaxation is assessed with the patient lying down with knees bent, as well as when standing. *The patient, while standing, is asked to make a conscious effort to relax the abdominal wall.* The additional extent of protrusion that occurs is both surprising and quite informative. Besides the obvious lower abdominal wall protrusion, one should also assess the magnitude of laxity at the upper abdomen. Compressing the lower abdominal wall and watching for “herniation” of the epigastric area will accomplish this task.

#### **The Presence of a Hernia**

The exam should explore for an incisional, epigastric, or periumbilical hernia. This is particularly relevant, not only for planning to repair the defect, but also to avoid performing liposuction in these areas before abdominal flap elevation for fear of intraabdominal penetration with the cannula.

#### **The Shape of the Waist**

If the waist is square and blunted by fat, aggressive liposuction can be very beneficial.

## Preoperative Photographic Documentation

It is essential to obtain a consistent and complete set of photographs. This should include one set of eight views (quarter turns) of the patient from neck to knees with the arms up and a second set with the arms down. Including the anatomic regions above and below the abdomen mandates that the surgeon assess the entire truncal “aesthetic unit” to plan the initial surgery or subsequent stages. This allows proper assessment of the potential far-reaching salutary effects of the HLTA, fleur-de-lis, or reverse approaches postoperatively.

During the photographic session, the patient is again asked to totally relax the abdomen so a true representation of wall laxity can be documented.

Additional views may be photographed, as desired:

- With the patient sitting/bending over to illustrate the true excess skin that is often hiding (particularly in front of the protuberant abdomen)
- With the patient grasping the excess skin to reproduce the desired lift and potential result of the surgery (for HLTA, reverse, and fleur-de-lis abdominoplasties)

## Patient Education

### *Informed Consent*

Every patient is told that the general risks of bleeding, infection, delayed healing, and undesirable scarring are common to any operation. The risks specific to abdominoplasty are also explained, including loss of skin in the lower area of the flap above the pubis, distortion or malposition of the umbilicus, asymmetry of the scar or abdominal contour, failure to narrow the waistline, and postoperative seroma. The surgeon should also clearly define for the patient the extent and limitations of the planned surgery:

- The excess skin that may not be fully removed: the potential dog-ears at the lateral margins and the inevitable residual skin or even rolls at the upper abdomen, above the zones of adhesion
- The potential scar at the lower midline abdomen, the original site of the umbilicus: when all lower midline skin is intentionally not excised to facilitate a tension-free closure in an aesthetic location
- The possible lateral extension of the abdominal scar: depending on the amount of excess skin present, the longer the scar, often the better the result

### *Patient Instructions*

The patient is given a set of instructions covering preoperative, intraoperative, and postoperative considerations (see p. 2948).

## Patient Information

### *Preoperative Preparation*

To ensure that the patient is optimally prepared for surgery, the following instructions are given:

- The patient is assisted to accomplish a regular bowel program.
- The patient is instructed to take antiseptic showers and apply antibiotic ointment to the nares for a few days preoperatively.
- The patient is encouraged to continue regular diet and exercise programs.
- The patient is strongly urged to stop smoking altogether, but if this is not realistic, then to discontinue all smoking for at least 2 weeks before and 2 weeks after surgery.
- The patient is advised to donate 1 or 2 units of autologous blood, depending on the extent of the surgery planned.

### *Intraoperative Information*

To promote compliance, the surgeon must inform the patient of any relevant intraoperative activities:

- Antiembolism stockings and pumps will be in place before, during, and after surgery.
- Binder garments, drains, a Foley catheter, and a pain pump may be placed.

### *Postoperative Instructions*

To encourage a predictable recovery, the surgeon must carefully instruct the patient in all aspects of the postoperative course:

- The minimum time off work will be 2 weeks; the time away from exercise and heavy lifting will be at least 6 weeks.
- The patient should be assisted to ambulate early, and calf exercises and spirometry exercises should be conducted regularly.
- A full diet should gradually be introduced over several days.
- Drains and sutures will usually be removed within several to 10 days.
- The timeline of healing includes bruising for at least 2 to 3 weeks and swelling that will resolve over a minimum of 3 to 6 months.

## Preoperative Planning

LORNE K. ROSENFELD

### Decision-Making

Before the first stroke of the marking pen is made, the entire anterior trunk must be analyzed and staged plans made to address all areas of deformity. The key to designing a comprehensive repair is to envision the entire trunk as composed of aesthetic units rather than focusing solely on the obvious lower abdominal excess:

1. The hips and thighs: Is there extra fat or skin? If there are discrete noncellulite fat deposits with nominal excess skin, concomitant liposuction is wise. How-



- ever, if skin traction at the hip effects a good contour change at the thigh, then one needs to consider a high lateral tension procedure.
2. The lower rib cage and upper abdomen: Is there significant redundant skin? It is unlikely to change after an HLTA; a reverse abdominoplasty at a later stage or an initial fleur-de-lis-type abdominoplasty would best treat this difficult zone.
  3. The epigastric and supraumbilical abdomen: Is there a prominent subcutaneous layer of fat? If so, the surgeon should consider a second-stage aggressive liposuction procedure to treat this deformity definitively and with greater safety.
  4. The pubis: Is it redundant and/or full? If so, liposuction of the area, with or without excision of excess pubis, will prevent a residual distracting deformity in this area.
  5. The waist: Is it square? Additional fascial sutures and liposuction in the area could “nip in” this area. If this area harbors large skin excess, a fleur-de-lis approach should be considered.
  6. The breasts: Are they in need of rejuvenation as well? This deformity should be broached at this time, because the breasts must be considered an aesthetic unit if a complete repair is to be planned. In addition, any redundant upper abdominal skin can be efficiently resected at a later stage through the breast incisions as part of a reverse abdominoplasty.
  7. The skin: Are there subcostal or midline scars? In the patient with significant redundancy, the surgeon should seriously consider a fleur-de-lis approach that could excise most if not all of these scars and obviate potential ischemia concerns.

Once all components of the abdomen and its “environs” have been evaluated, the surgery can be definitively mapped out: A number of surgical approaches are available to treat abdominal deformities. These range from liposuction only to full abdominoplasty with fascial plication. The decision is based on evaluation of the abdominal skin, subcutaneous fat, and underlying fascia. The patient’s desires must also be taken into account: Is she seeking recontouring to look better in her clothing, or is she looking for recontouring and skin tightening so that she can look good in a two-piece bikini?

### ***Liposuction***

The best candidates for liposuction are nulliparous women with a modest amount of excess fat, tight abdominal musculature, no hernias, and tight skin of normal elasticity. Some women who have had children with minimal to modest loss of skin elasticity and no diastasis may also be candidates for liposuction if they understand that their skin quality will not be improved but their contour will be greatly enhanced, especially when they are fully clothed. These women should understand and accept this tradeoff for a less-invasive procedure.



### ***Traditional Abdominoplasty***

Patients who have excess skin above and below the umbilicus, periumbilical hooding, fat excess, and diastasis or abdominal wall hernias are appropriate candidates for traditional abdominoplasty. Traditional skin excision and more extensive skin excision is required to deal with the supraumbilical skin excess. These patients should anticipate improvement of their appearance in and out of their clothes.

### ***Limited Abdominoplasty***

Patients with nominal excess skin above and limited excess skin below the umbilicus are reasonable candidates for a more limited abdominoplasty. This approach is most conducive in a patient with a high-riding umbilicus. The patient may have a diastasis or even an umbilical hernia, which can be repaired through the limited approach. The effect on umbilical position is an important determining factor to candidacy for this approach. The limited skin incision combined with musculofascial tightening with liposuction above and below the umbilicus will enhance the patient's appearance in and out of her clothing.

### ***High Lateral Tension Abdominoplasty***

The "pure" Lockwood type of abdominoplasty is effective for patients with excess skin at the abdomen, lateral hip and thigh, pubis, and even the anteromedial thigh. If there is a significant amount of excess skin superolaterally, then either conversion to a fleur-de-lis approach or a plan for a second-stage reverse abdominoplasty should be considered. A concomitant reverse abdominoplasty is not recommended, because the intervening band of blood supply may not be enough to sustain the flaps.

### ***Fleur-de-Lis Abdominoplasty***

The fleur-de-lis abdominoplasty is appropriate for patients who require more aggressive treatment for excess skin throughout the abdomen and trunk, particularly at the upper pole of the abdomen and lower chest and back as well as at the waist, hips, and thighs. The patient must accept the tradeoff of a full midline scar for a more complete skin resection. This approach is also efficacious in a patient with abdominal scars that could otherwise compromise the blood supply of a more traditional abdominoplasty.

### ***Reverse Abdominoplasty***

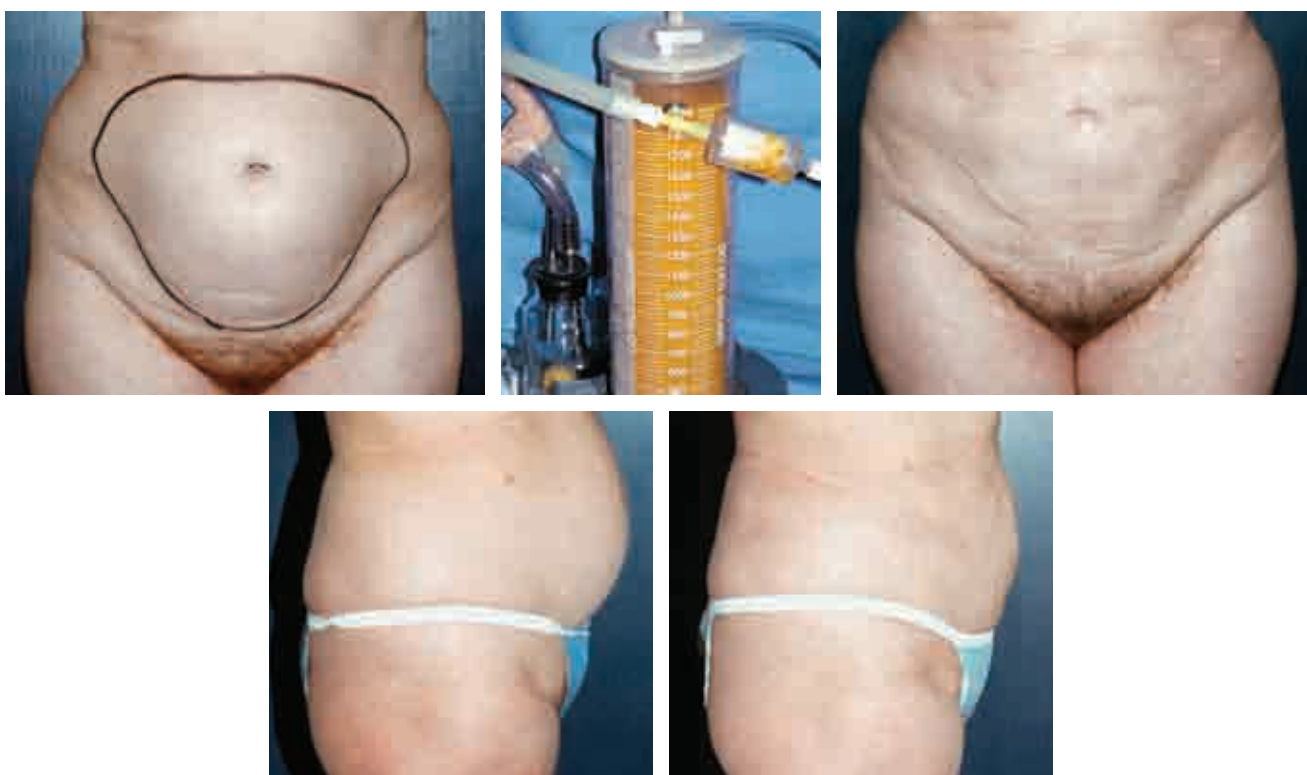The reverse abdominoplasty is particularly relevant in patients with primarily or residual excess upper abdominal skin. This approach can be very synergistic when combined with a Wise pattern type of breast surgery.

## OPERATIVE APPROACHES

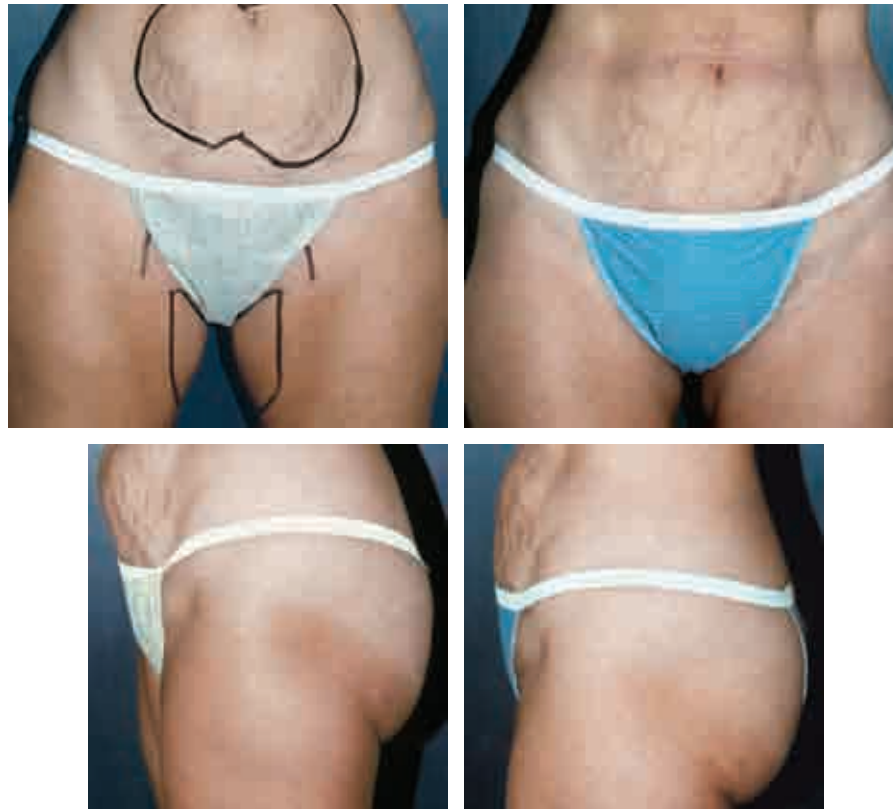### Liposuction

GILBERT P. GRADINGER

Some nonobese women who have a protuberant lower abdomen without excess skin present with good skin tone, excess lower abdominal fat, and some muscle laxity. Typically, liposuction alone can improve their contour.



Use of a tumescent technique (usually injection of 500 to 1000 ml Ringer's lactate with 50 ml of 1% lidocaine and 1 ml of 1:1000 epinephrine) enables the surgeon to suction fat with very little blood loss and a nice improvement in abdominal wall contour.



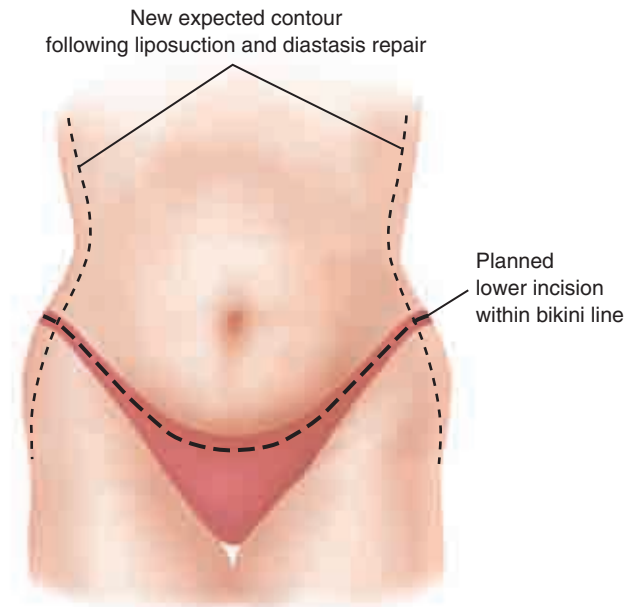
Although liposuction will never improve stretch marks, abdominal wall contour can be improved in some patients who do not want any form of abdominoplasty, as can be seen in this patient with poor skin tone and stretch marks.

## Traditional Abdominoplasty

GILBERT P. GRADINGER

Anterior abdominal dermolipectomy, with or without liposuction, constitutes traditional or classic abdominoplasty, which has two significant variations, depending on the management of the umbilicus. Dermolipectomy of the anterior abdominal wall removes excess skin and fat, primarily in the vertical direction. The repair results in tightening and flattening of the abdominal wall. The additional surgical component, fascial tightening, further flattens and contours through horizontal tension narrowing the waistline. Variations on the traditional abdominoplasty include lower abdominoplasty, HLTA, and fleur-de-lis abdominoplasty.

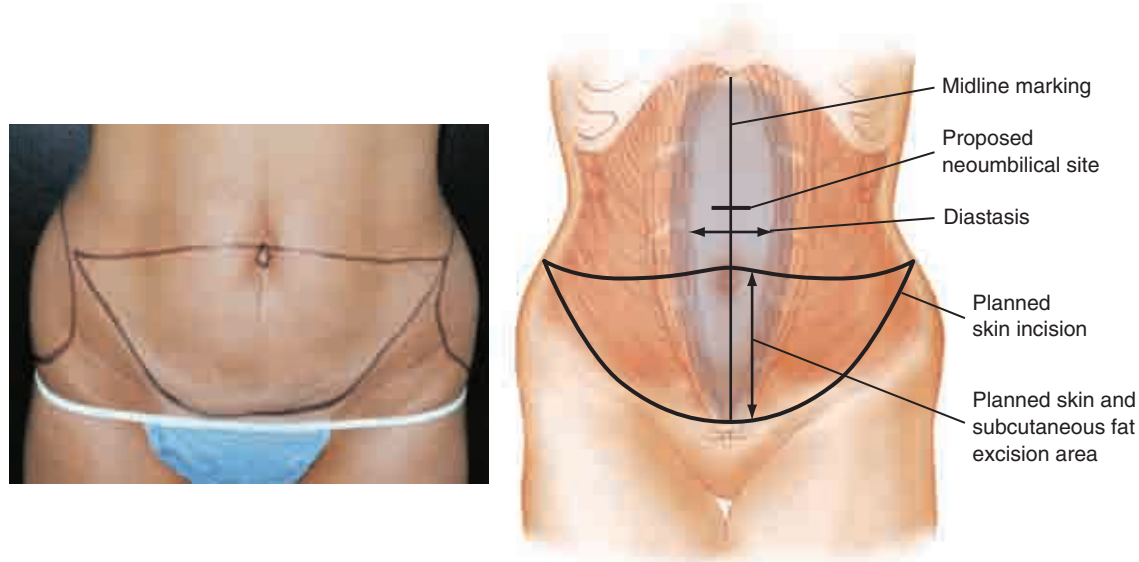
## Markings



The patient is examined and marked for surgery the day before the procedure. She has been advised to wear her usual style of underpants or swimsuit bottom (her choice), so that the garment will conceal the planned incision and resultant scar. The practice of marking the patient in the office the afternoon before the day of surgery has served my patients and me well.

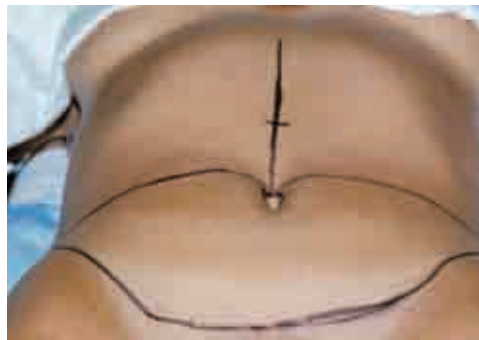
An office nurse is present and assists in making the patient feel more comfortable in this private setting, in contrast to the preoperative holding area. The patient is able to see the markings in the office, ask questions, and offer an opinion (particularly in liposuction marking). Thus she will have a better understanding of the location of incisions and resultant scars.

Planning is vital to successful surgery, and it can be done more accurately in a controlled situation. Photography is achieved with precise consistency of positioning, lighting, and background. I do not have to arrive in the preoperative holding area to arouse a medicated patient or request that she not be medicated until I have completed the markings.



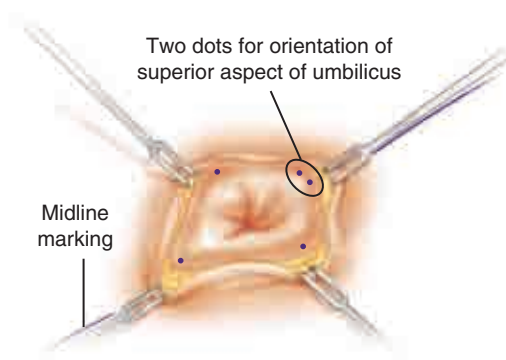
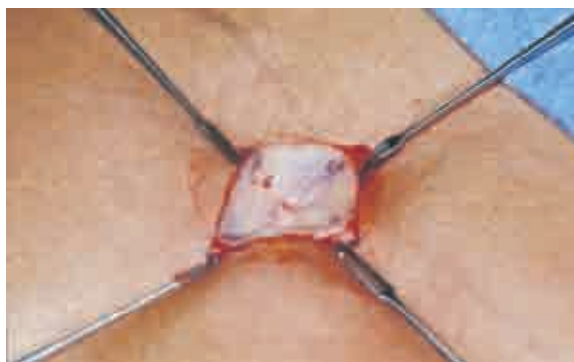Surgical marking is performed with the patient standing. The excess skin and fat to be excised are usually from the umbilicus to the pubis vertically and from one anterior superior iliac spine to the other horizontally. The maximum excision is in the midline, and it tapers laterally. The surgeon makes a clinical judgment as to whether supraumbilical skin will reach to the pubis after removal of the intervening skin. This can be done by grasping the tissue and bringing the proposed midline points together. The surgeon should be alert for patients with a greater-than-usual distance from umbilicus to pubis and a short distance from the xyphoid to the umbilicus.

The patient should urinate before leaving the preoperative holding area for the operating room. By going to surgery with an empty bladder, the patient avoids the need for a Foley catheter. Operating time is usually less than 2 hours. The patient will have recovered well enough from anesthesia to void spontaneously. Therefore the risks associated with an indwelling catheter are eliminated.

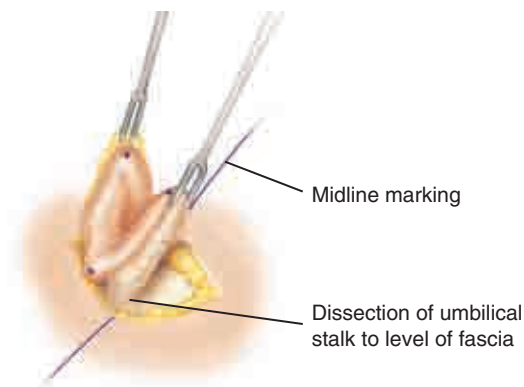
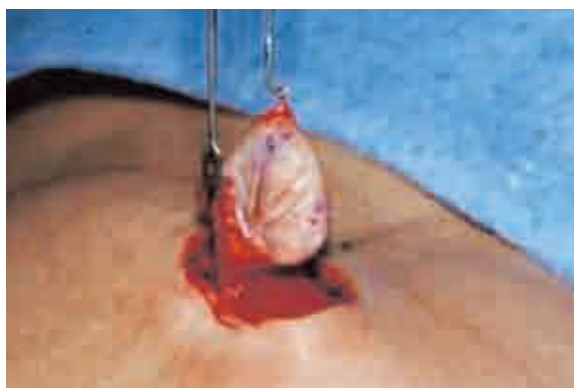

The periumbilical markings are made with the patient supine on the operating table, as is the vertical midline mark from the xyphoid process to the umbilicus. The estimated location of the new umbilical skin site is marked.

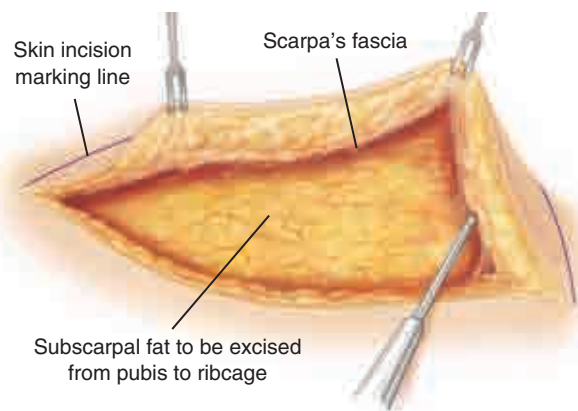
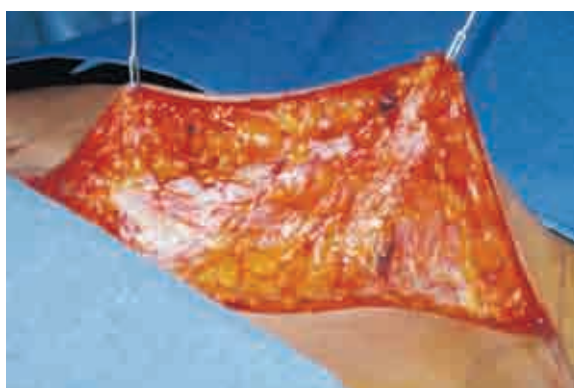## Operative Technique



After general anesthesia has been induced and the patient has been prepared and draped, the 3, 6, 9, and 12 o'clock positions of the umbilicus are needle-tattooed and the circumferential incision is made. Two dots are tattooed at the 12 o'clock position to prevent accidental rotation of the umbilicus at the time of repair.

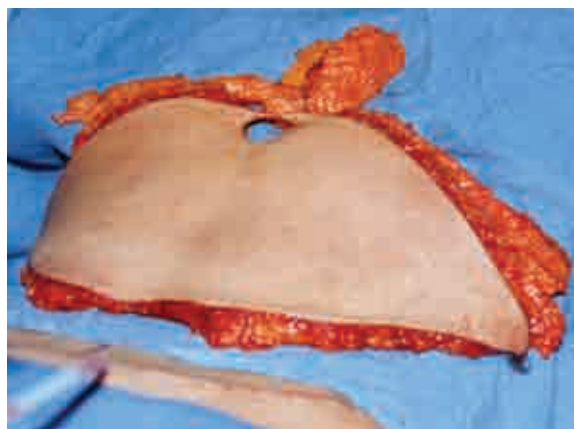


The umbilical stalk is dissected to the level of the anterior abdominal fascia.

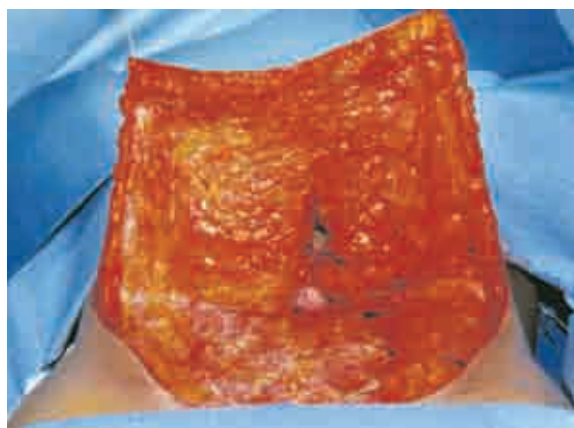


The skin and subcutaneous flap are dissected from the pubic/inguinal region cephalad at the level of the anterior abdominal wall fascia. Dissection continues cephalad to the lower border of the rib cage laterally and the xyphoid centrally.



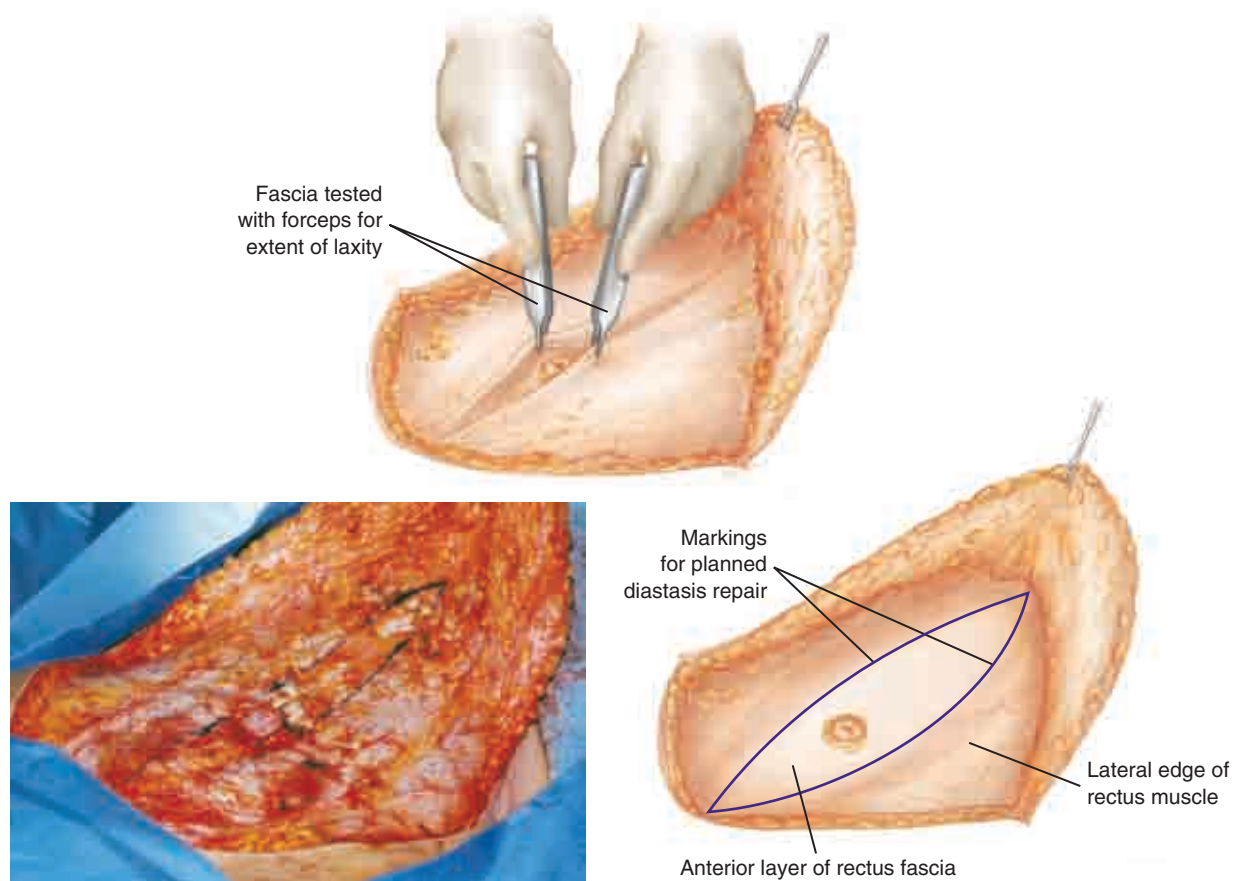


The tissue excised is a full-thickness skin and subcutaneous block including subscapular fat cephalad to the skin excision.

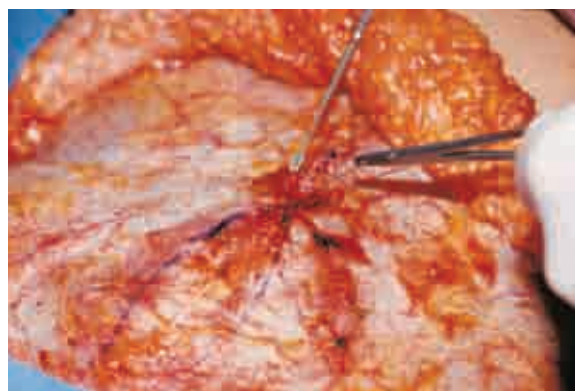


The elevated fat flap from which fat deep to Scarpa's fascia has been excised is shown. Dissection and hemostasis are achieved with an electro-surgical unit.

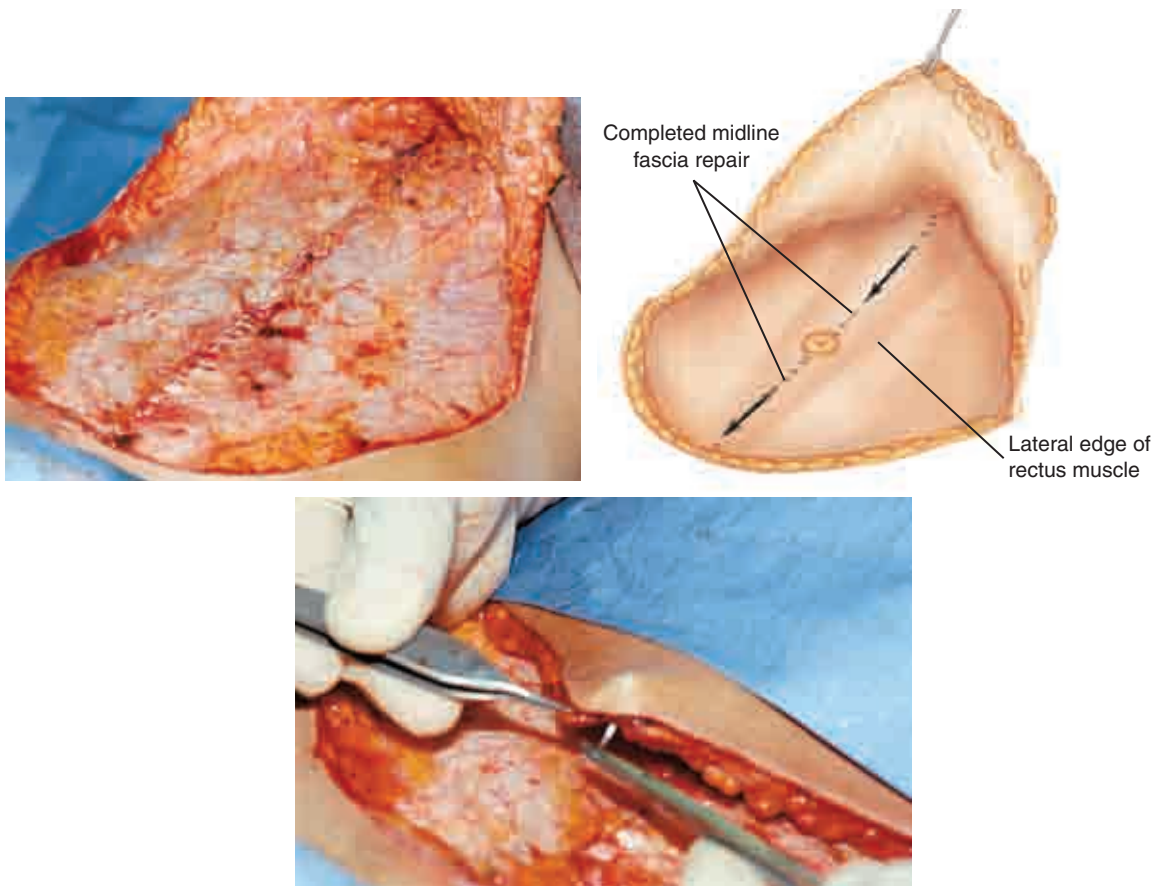




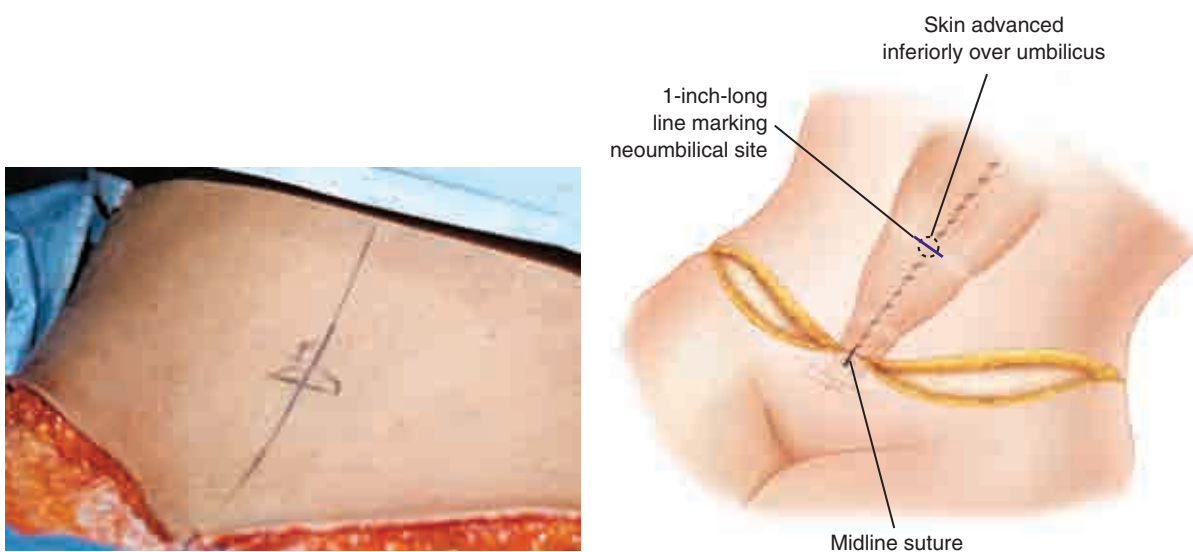
The extent of anterior abdominal wall midline fascial laxity is tested with forceps and the width of laxity marked for repair.



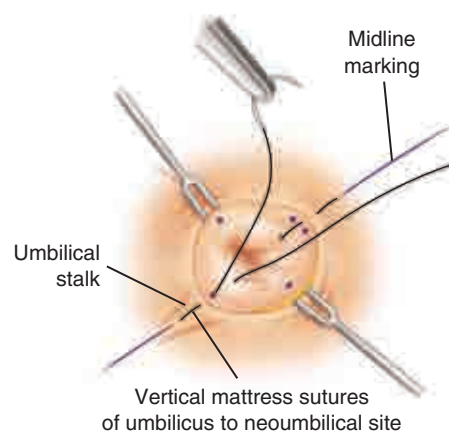
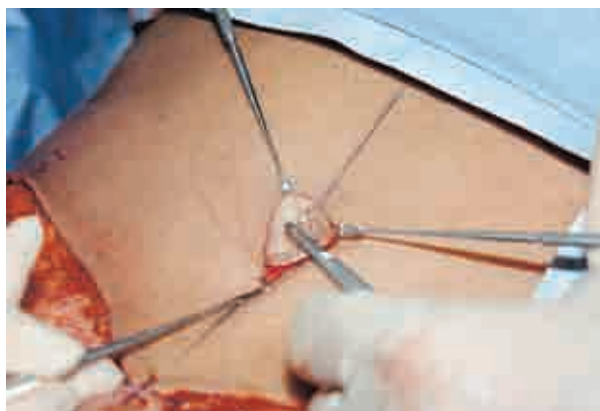The laxity and underlying diastasis are repaired by a running absorbable monofilament suture (for example, Monocryl) from the xyphoid to the umbilicus (and the umbilicus to the pubis). Liposuction is performed, then the wound is irrigated with saline solution and hemostasis is ensured. Jackson-Pratt drains (No. 7) are inserted in each side through separate incisions in the pubic region.



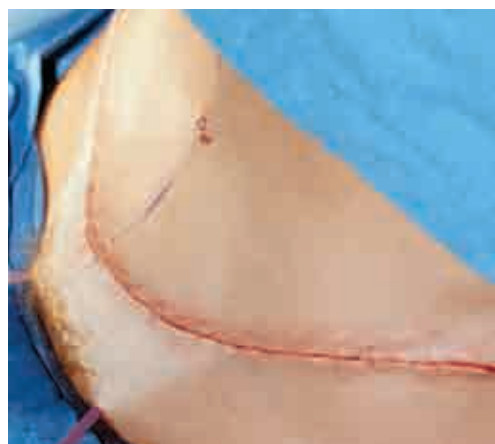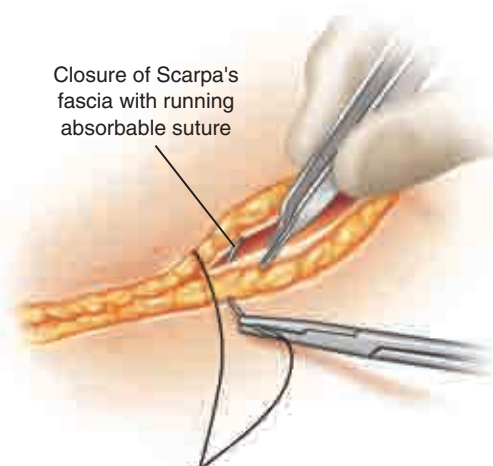
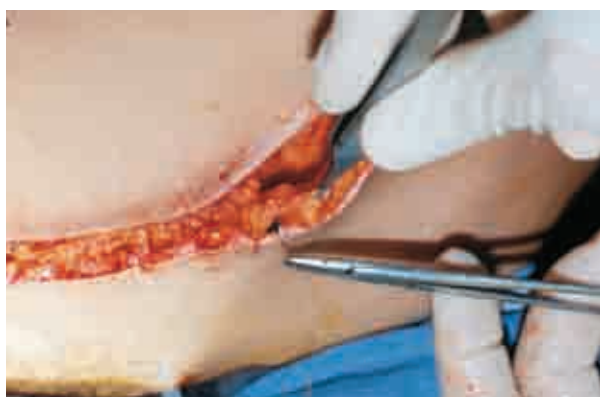The lowest midline point on the flap is advanced inferiorly to be sutured to the midline pubic skin. Subcutaneous fat is retained at the margin in the midline; this is important for skin circulation.



The 1-inch-long horizontal skin incision is marked in the midline directly over the umbilicus. It is anticipated that the umbilicus will again be vertically oriented after healing, because the tension placed on the flap by the closure will convert the horizontal opening into a vertical one.



The umbilicus is delivered through this incision and sutured at the 12, 3, 6, and 9 o'clock positions with one-half dermal (on the skin side) vertical mattress sutures of 5-0 nylon. The circumumbilical repair is completed with a running subcuticular 4-0 Vicryl suture.

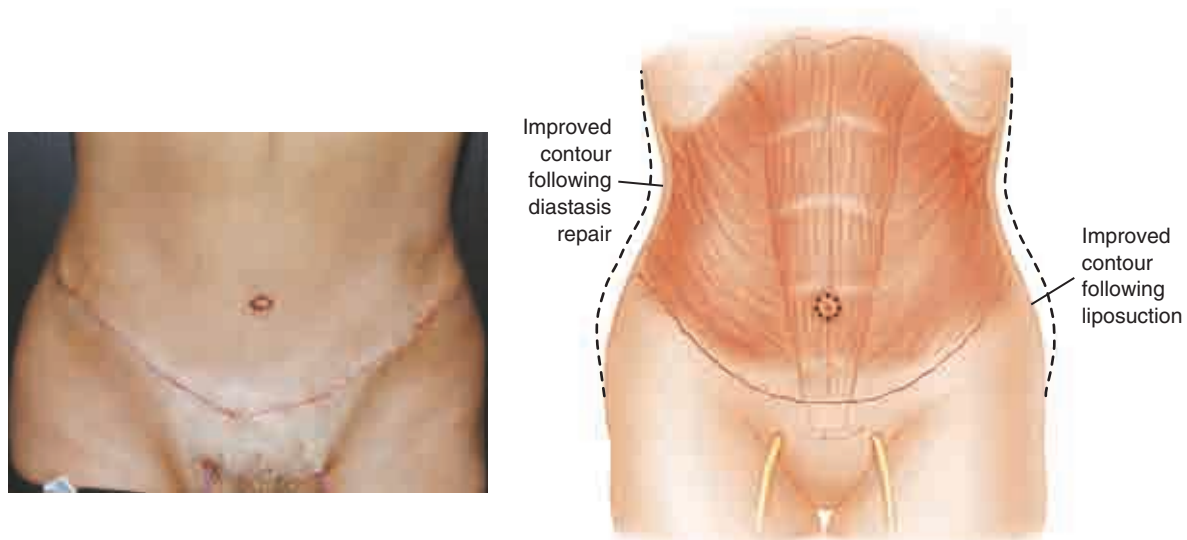


The wound is closed in two layers (Scarpa's fascia and subcuticular) using 4-0 Vicryl sutures. It will be obvious that the lower incision is longer than the upper one; it is more curvilinear, whereas the upper incision is straighter. Closing these incisions of unequal lengths is not a problem because of the tension and stretching of skin in the flap, which allows good approximation.

## Postoperative Care

Fine mesh, nonadhering gauze and layered  $4 \times 4$  sponges, ABD pads, and an abdominal binder (three panels, not four, so that respiration is not restricted postoperatively) are used for dressing. The patient is placed in bed with the head, knees, and feet elevated. Intermittent compression stockings, full leg length, are put on the patient in the operating room before surgery; these are activated throughout surgery, in the recovery room, and in the patient's hospital room postoperatively until she is fully ambulatory, at which time full-length support hose are used and continued for 3 weeks after discharge. Surgery is performed either on an outpatient basis, as was done in the patient described in this sequence, or with a 1-night hospital stay. Antibiotics are administered intravenously at the beginning of the surgical procedure and are not used again unless there is a problem postoperatively.

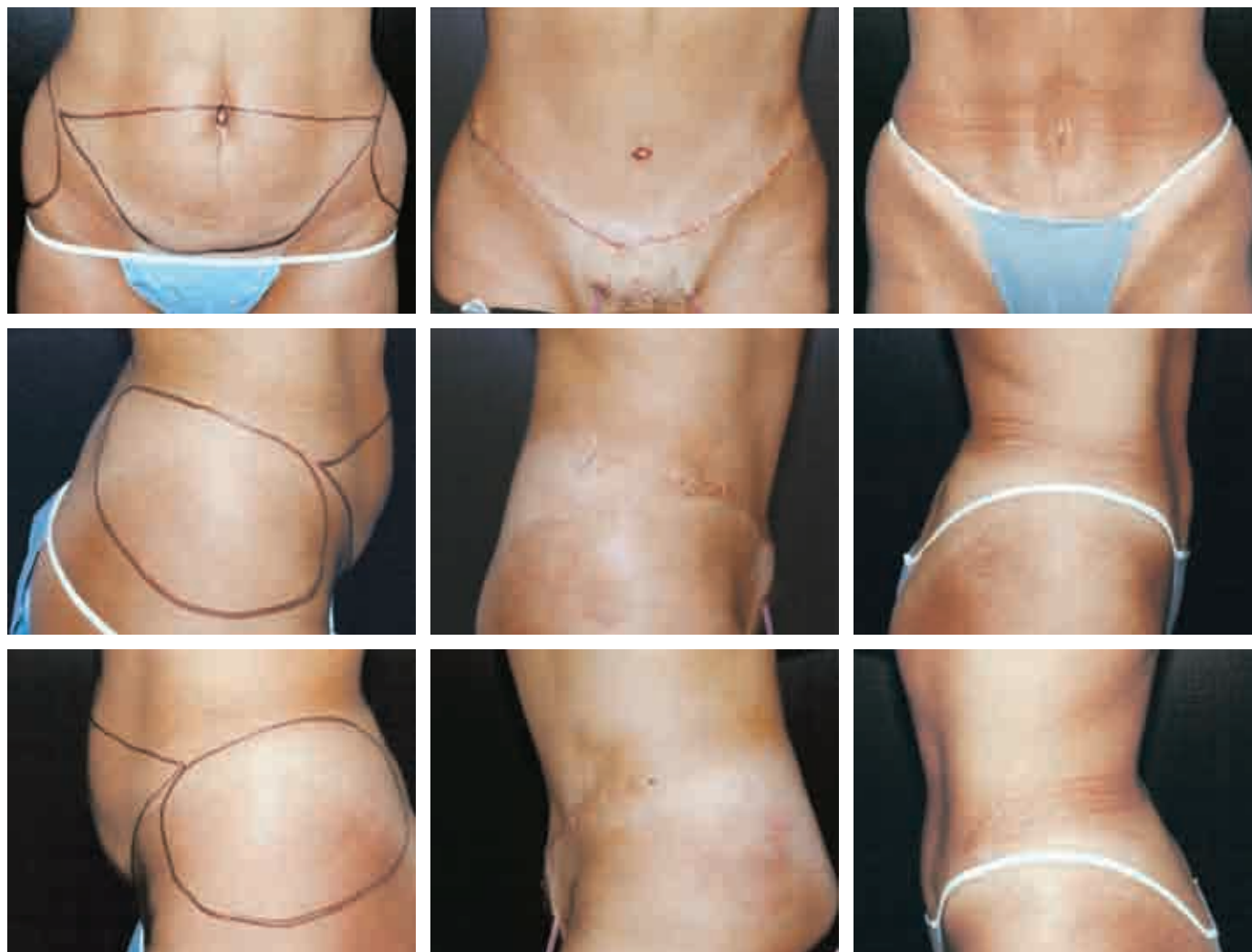## Results



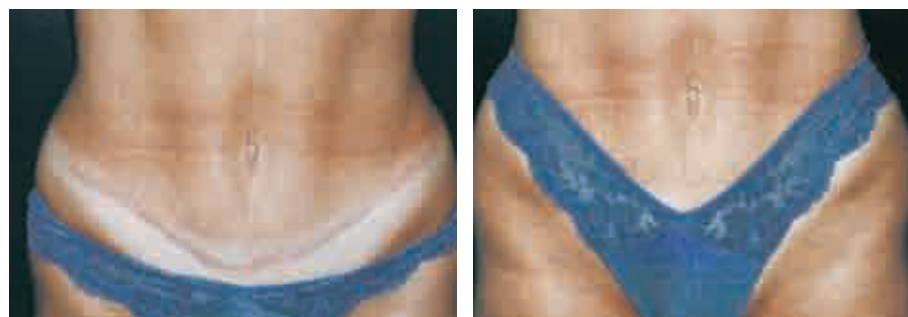In this photograph of the patient's appearance on postoperative day 1, the patient is erect and drains are in place. Drains were removed on postoperative day 3, when drainage was less than 30 ml per 24 hours.

Patients often ask how the benefits of abdominoplasty would be affected by future pregnancy and childbirth. To my knowledge, this is the only patient in my practice who had a child after abdominoplasty. In this instance, because she controlled her weight and exercised during and after the pregnancy, the benefits of the abdominoplasty persisted. (Obviously, one needs to be careful in drawing conclusions based on a single case.)

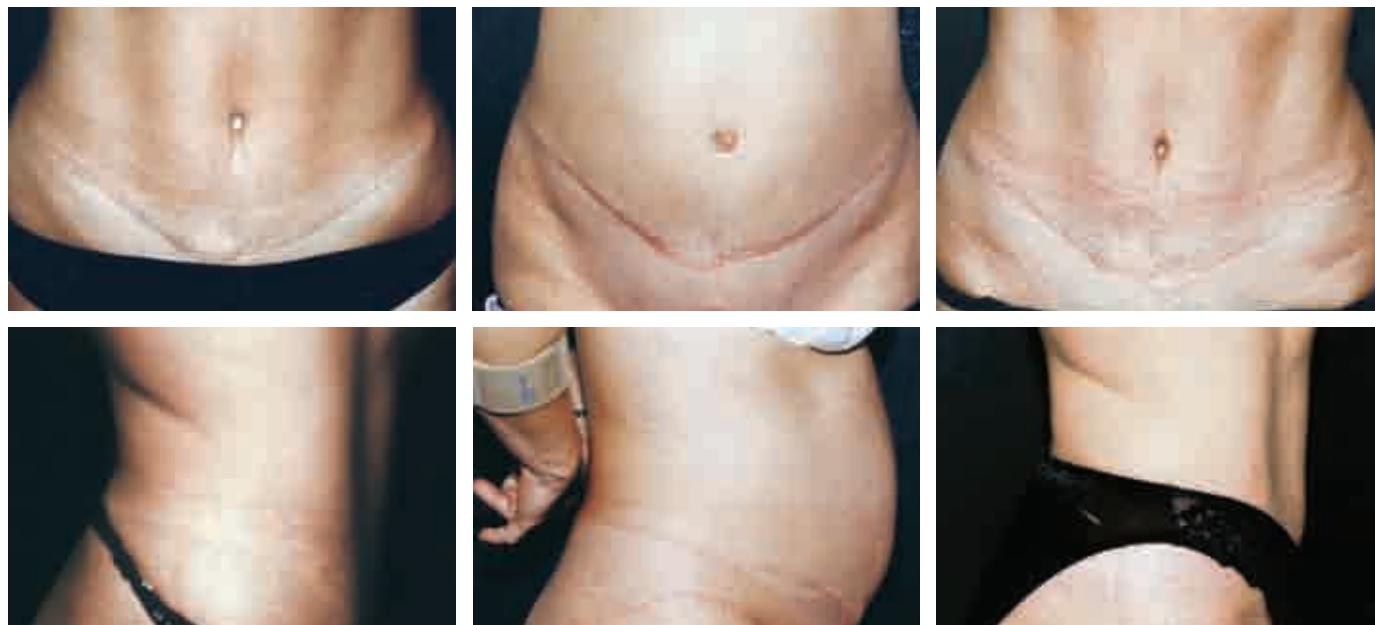



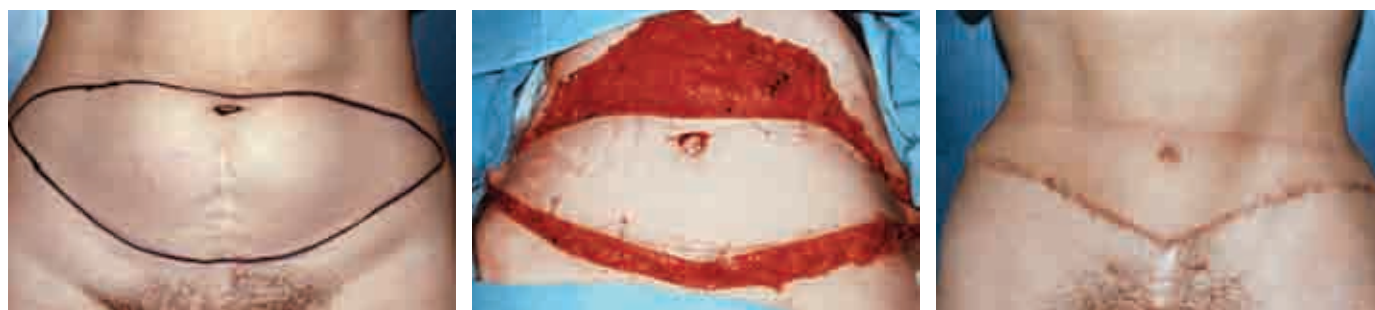
The patient is shown preoperatively, 1 day postoperatively, and 1 year postoperatively in all three views. Note the shape of the umbilicus in the three anteroposterior photographs.



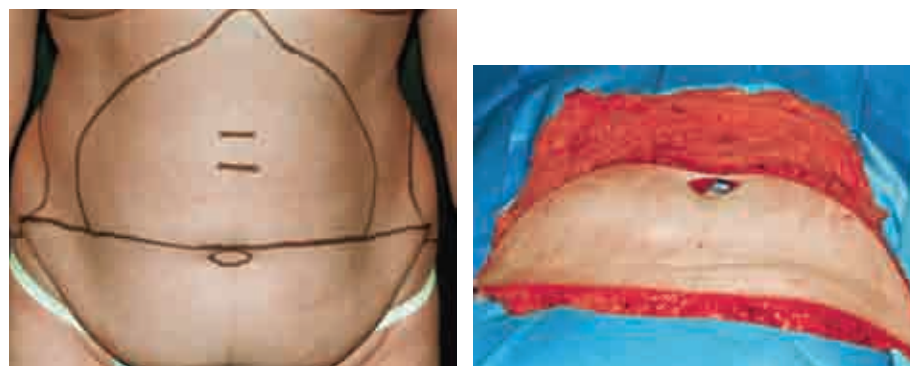
The scar is seen and concealed at 2 years postoperatively.



The patient is shown 3 years postoperatively, 1 year later when she is 6 months pregnant, and 7 months after that (4 months after vaginal delivery of a 7-pound, 2-ounce boy).



Another patient is shown to demonstrate the dramatic improvement achieved in abdominal flattening and waist contouring.

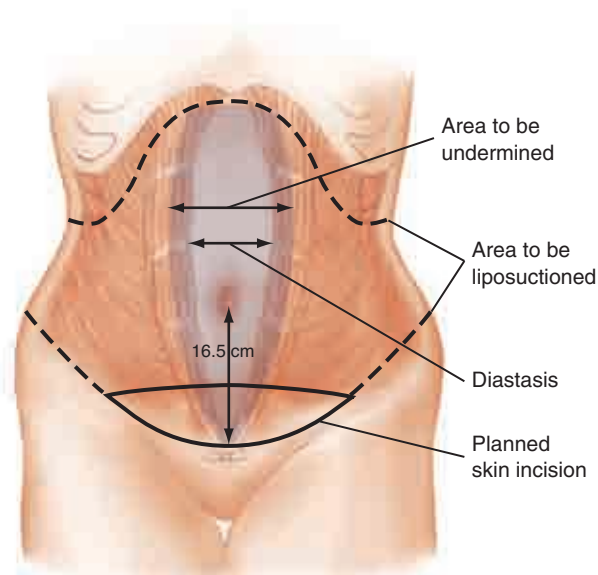
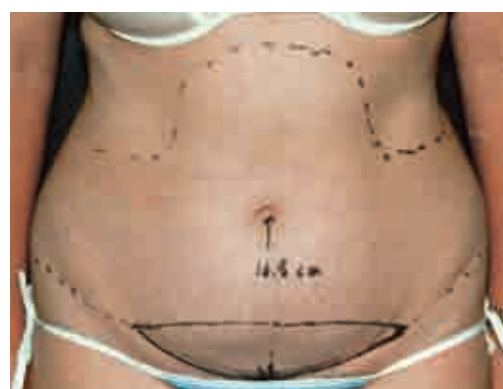

This patient's preoperative markings and tissue specimen demonstrate the extensive removal of fat deep to Scarpa's fascia. This fat excision, in my opinion, is a safer way of thinning the upper flap compared with suctioning, because it preserves the blood supply to the skin through the subcutaneous fat that is superficial to Scarpa's fascia.

## Limited Abdominoplasty

GILBERT P. GRADINGER

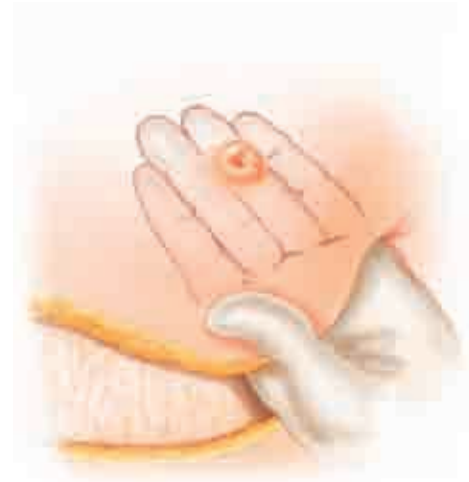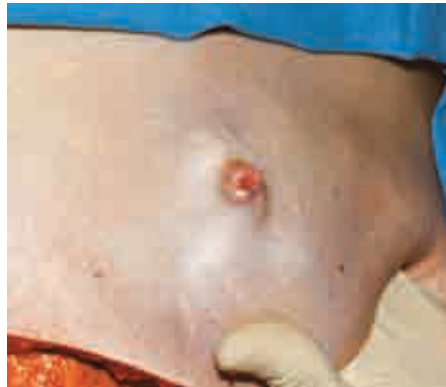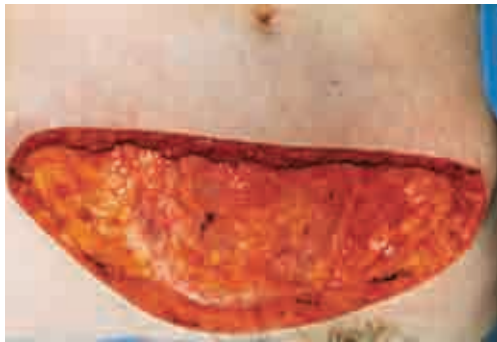
In some patients it is not feasible to remove all of the skin between the umbilicus and the pubic area: a patient who has a relatively high umbilicus, and a patient who has a low suprapubic scar that dictates where the lower incision should be placed. Both factors may coexist in some patients.



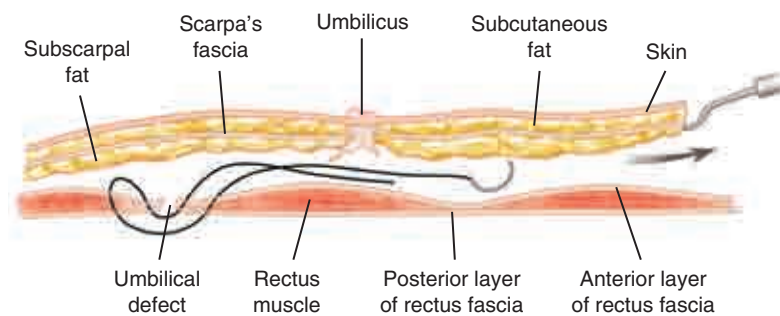
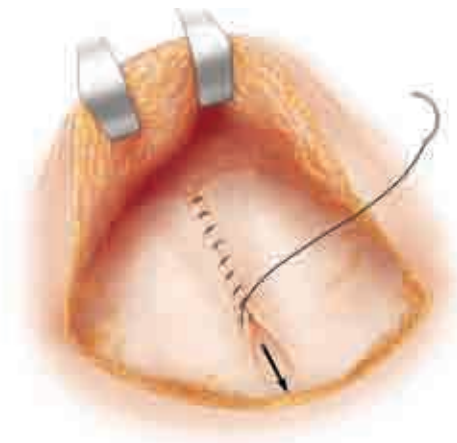
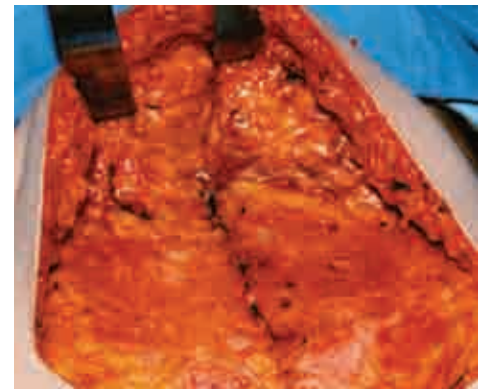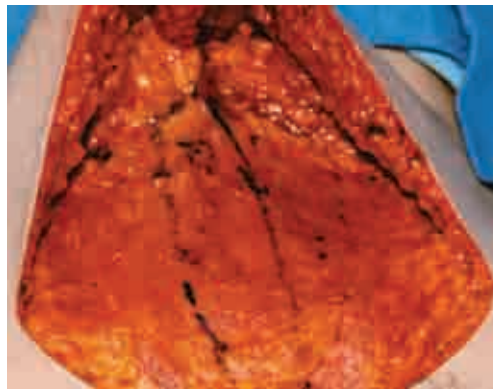
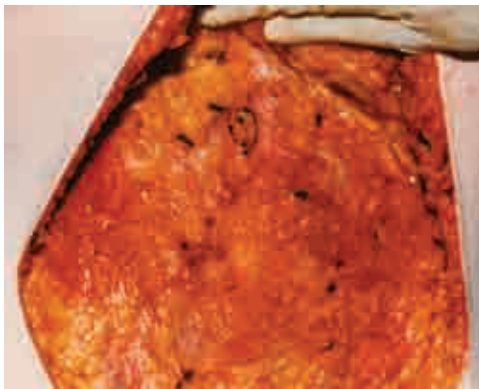
This patient had a low surgical scar; the distance from the scar to her umbilicus was 16.5 cm, approximately the same distance as from her xyphoid to the umbilicus. To reach the pubis, the skin of the upper abdomen would have to be stretched to double its normal length.



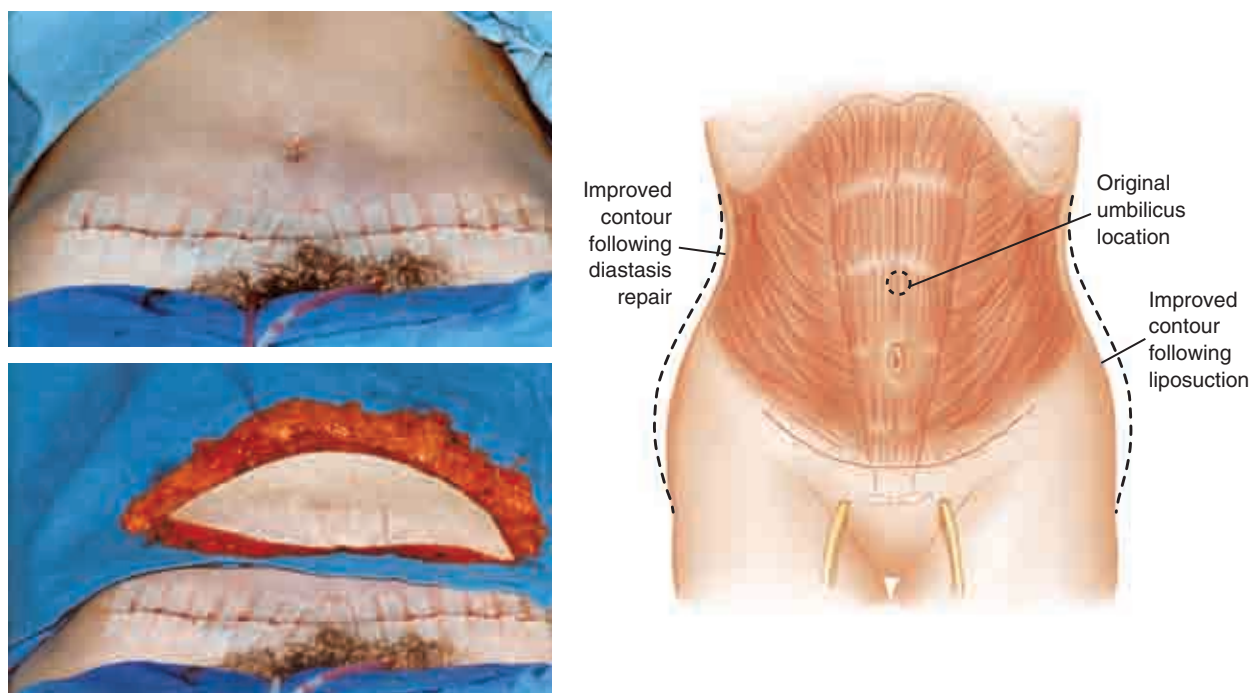
## Operative Technique



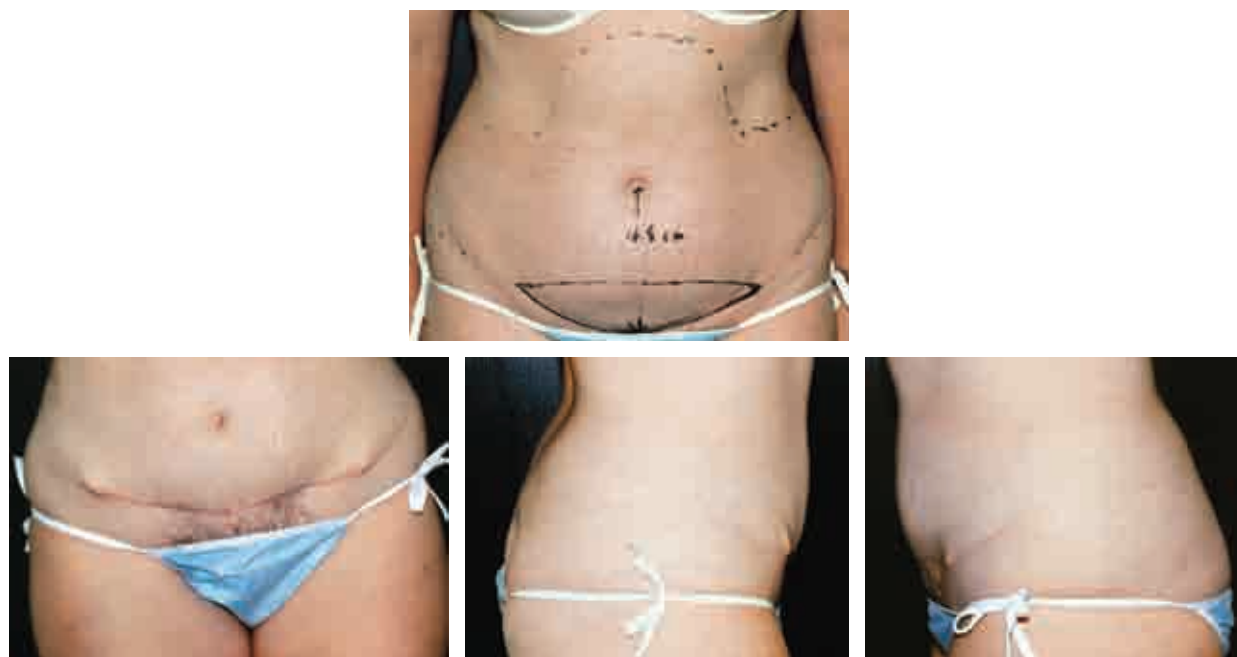The abdominoplasty was modified, with more-conservative excision of skin and fat, and instead of leaving the umbilicus attached to the abdominal wall, it remained part of the flap—its stalk having been transected at the level of the anterior abdominal wall fascia (demonstrated with the surgeon's hand interposed between the flap and the fascia).



The umbilical fascial defect and diastasis were identified and sutured.



The flap was advanced inferiorly carrying the umbilicus, and the incision was sutured. The umbilicus can be seen to be lower on the abdominal wall than it was preoperatively. Drains have been placed and the surgical specimen is seen.



The patient is shown 18 months postoperatively. Because of the tension on the flap created by the closure, the umbilicus is stretched; it is more vertical than it was preoperatively. Unfortunately, the result is compromised by the presence of “dog-ears” (faulty surgical technique). This complication could have been avoided if suturing had been begun at the lateral ends of the incision instead of medially.

## Comprehensive Abdominoplasty: High Lateral Tension Abdominoplasty With Complementary Fleur-de-Lis and Reverse Techniques

LORNE K. ROSENFELD



83-1 Comprehensive  
abdominoplasty

The abdominoplasty can be deceptively easy to perform yet maddeningly inconsistent in its results. The plastic surgeon is challenged to excise all the excess anterior trunk skin and fat through the shortest possible incision and to ensure optimal healing with an inconspicuous scar. To begin to rise to this challenge requires one to become a student of the abdominoplasty. By continuously honing one's surgical planning and execution, a more balanced technique can be realized that is both reliably safe and aesthetically successful. The high lateral tension abdominoplasty, with some "2.0" modifications, is such a technique.

Traditionally, the primary goal of any abdominoplasty has always been to excise the central lower abdominal excess skin or pannus and plicate the abdominal fascia through a suprapubic incision. Unfortunately, this traditional abdominoplasty may often fall short of this goal: a scar that may ride too high; persistent skin and lipodystrophy at the pubis, thighs, flanks, and hips; and a consistent incidence of mid-line skin necrosis or wound dehiscence.

The HLTA addresses these shortfalls. It may be defined as a more complete treatment of the lower trunk aesthetic unit from the abdomen to the pubis, hips, and thighs, with a greater overall aesthetic result as well as a greater margin of vascular safety. What follows outlines the techniques and tools to accomplish these superior results safely and consistently.

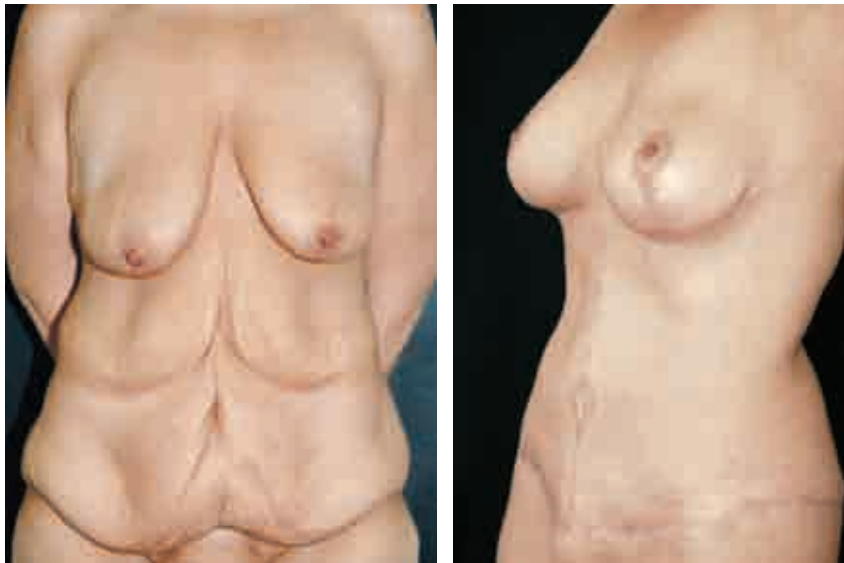### Evolution of the Modern Abdominoplasty

The abdominoplasty technique has evolved significantly over the last four decades. The modern abdominoplasty was born in South America in the 1960s. The basic surgical tenets have always been to conduct a rectus plication, with maximal excision of the central skin excess by extensive undermining of the entire abdominal wall. The closure is often under some tension and is therefore of necessity conducted with the patient in significant flexion. When liposuction was introduced in the 1980s, it soon became apparent that blithely and aggressively adding this modality to the abdominoplasty led to an unacceptable incidence of flap ischemia and skin necrosis. Liposuction then evolved into a more conservative adjuvant treatment.

Although there were indeed fewer physiologic problems with this technique, the aesthetic results were once again more constrained.

Then in the early 1990s Lockwood published a series of seminal articles that single-handedly changed the tack of the abdominoplasty technique. Based on his extensive experience with body-contouring surgery, he decisively demonstrated and definitively modified the surgical principles of abdominoplasty and reported greater safety and improved aesthetics. He enumerated several surgical tenets that were in many ways diametrically opposed to those of the classic or traditional abdominoplasty: the undermining of the central skin flap only to facilitate plication and *discontinuous dissection elsewhere* (to enhance vascularity and allow *judicious* concomitant liposuction) and the *initial* resection of the *lateral* excess skin, with more-conservative resection of the central skin flap to accomplish a more complete and natural repair, and the use of a planned and controlled *high-tension closure*, with diligent use of the underlying superficial fascial system. Thus was born the high lateral tension abdominoplasty.

## The High Lateral Tension Abdominoplasty: A “2.0” Version



For a result to be called truly successful, three strict standards must be balanced equally: the case has to demonstrate the greatest degree of *safety* (zero tolerance for complications), with the maximal *aesthetic* result (correction of all “deformities”), and a *consistent* reliability (regardless of patient presentation). As a result, several important expanded principles of the high lateral tension abdominoplasty validate this 2.0 advancement.



*The surgeon performing an HTLA procedure should not slavishly follow the otherwise arbitrary mandate that all the skin between the pubis and the umbilicus must be excised.* This approach will only truly work in a patient with an enormous pannus. Otherwise, the excisional marking must be placed above the pubic hairline to accomplish closure of the wound, often with an overly tight closure. This approach may result in an excessively high scar and superiorly retracted pubis, an unnaturally flat hypogastrium, and, more seriously, an exaggerated rate of wound dehiscence and skin necrosis. Instead, any redundant pubis should be corrected with excision, rather than be used to help close an overly tight suprapubic wound, as is often the case with a traditional abdominoplasty. The pubis is then closed under no tension and rests in a lower, more inconspicuous location. As a result, it is most often necessary to close the original umbilical site, since all the skin between the pubis and the umbilicus may not be excised. The surgeon must resist the temptation to remove even a few centimeters of intervening abdominal skin for fear of recreating the usual overly tight closure. This small scar is a reasonable tradeoff when compared with the traditional closure, which can lead to complications.

*Any abdominoplasty should consider not only what is above the future incision (the traditional pannus) but also what is below; that is, the pubic excess, anterolateral and medial thigh redundancy, and buttocks laxity.* Otherwise, the tissues below the incision may appear distractingly untreated postoperatively, and the full effect of the HTLA may not be realized. This tenet underlines one of the greatest benefits to the HTLA that is not usually considered possible with the traditional abdominoplasty: one can realize a true “body lift” effect through an anterior incision only. Therefore this procedure is really simply a “tension abdominoplasty,” with sequential tension placed from lateral to medial.

This notwithstanding, *the goal of the design and placement of the future scar should primarily be to hide the scar.* Lockwood originally described a very high (“French-cut”) lateral closure, probably because that style of clothing was more fashionable at the time, and a more oblique vector of pull does more efficiently treat the upper abdominal excess, as described above. However, considering how fashion changes, and that a hidden scar will usually trump some residual excess skin, the surgeon should mark the patient *within* the margins of her preferred clothing. This becomes particularly relevant when the patient favors low-cut jeans.

The *location and extent of the remaining subcutaneous fat* must be evaluated and respected. This assessment represents an age-old plastic surgical battle between “beauty and blood.” That is, at what cost to the blood supply does the surgeon attempt to remove all remaining excess subcutaneous fat? Lockwood originally described a reasonable detente: liposuction should only be conducted beneath tissues that have not been undermined. However, most recently, the pendulum has swung back: published articles are once again advocating more aggressive full truncal lipo-

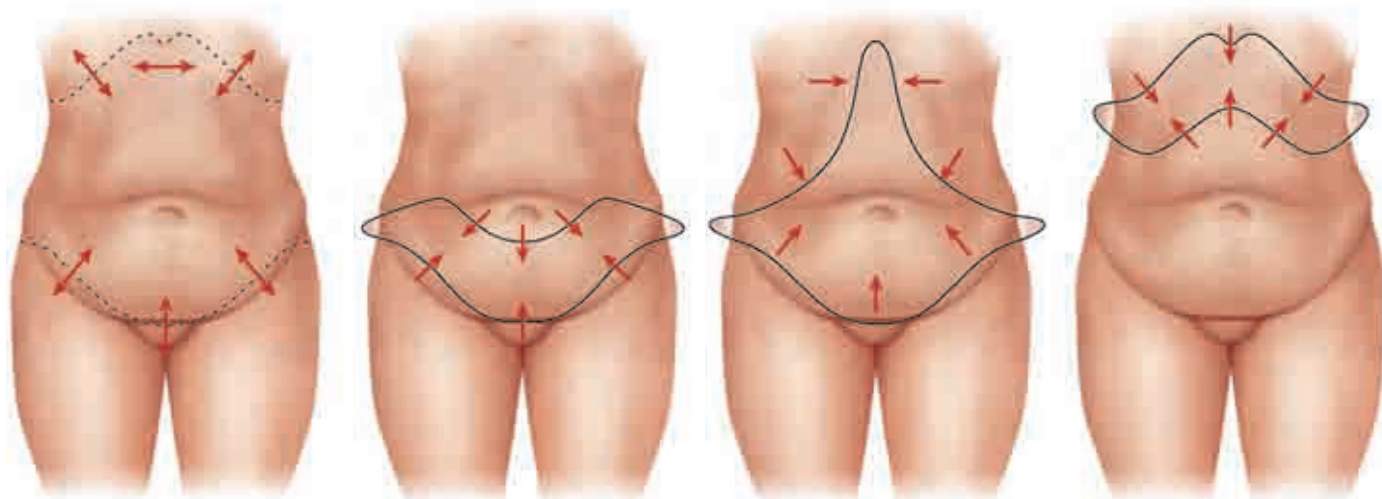
suction at the time of the abdominoplasty. This recommendation is predicated on the idea that if one follows the original Lockwood admonition to restrain the flap dissection only as much as needed to conduct a fascial plication, enough perforators will be preserved to allow for this aggressive liposuction. However, as stated earlier, Lockwood also warned that despite this conservative undermining, liposuction of the remaining central skin flap should not be done for fear of skin flap necrosis. And realistically, some of these same precious perforators are often sacrificed to repair the more protuberant abdomen. This principle should be respected when one considers Lockwood's extensive experience.

If the premise is to preserve the central flap's blood supply by undermining only centrally to allow fascial plication, it may indeed be self-defeating to then disrupt the very same flap with liposuction. Ironically, the only patients who might be candidates for such an aggressive approach would be those without a significant amount of fat in the first place; that is, patients with a low BMI. Otherwise, the usual abdominoplasty patients with higher BMIs could undergo liposuction at the waist and hip rolls, but a *second-stage* liposuction 6 months to a year later should be planned for the central skin flap. Only then can a zero tolerance for skin flap necrosis and dehiscence be realized.

It has always been important to evaluate *the magnitude of excess skin to be excised*. But to actually design the most "efficient" length and direction of the incision, *it is critical that the extent and orientation of the skin left behind also be assessed*. At once, the surgeon must ensure that the remaining skin is both sufficient to close the defect and efficiently relieved of its own redundancy. This principle may be applied to both the central and lateral closure. Specifically, laterally, the excess skin at the hip and thigh is often neglected by the traditional abdominoplasty. This primarily *obliquely* oriented excess tissue is efficiently removed through the *oblique* incision/vector of the HLTA. Centrally the superfluous skin at the epigastrium is in fact a primarily *horizontal* excess (that has migrated from the chest) that can neither be efficiently removed nor "used" to close a lower abdominal defect through a *horizontal* incision. Therein lies the potential flaw in the traditional abdominoplasty as well as the efficacy of the high lateral tension technique. An incongruent consequence may occur: the wound closure may be too tight despite the apparent epigastric redundancy, which can in turn be left behind, and the lateral excess cannot be effectively treated because the remaining abdominal flap has been primarily used for the central closure. To reconcile this paradox, *less skin should be excised centrally and more skin must be removed laterally* through an HLTA-oriented incision and repair. These concepts are illustrated on p. 2970: Using "vector analysis," the lateral tissue above and below the incision is redundant in a more oblique vector and so should be removed through an opposing oblique incision. Serendipitously, this matches the relative direction of the desired HLTA lateral scar placement. In addition, this oblique vector also treats the more horizontal excess in the epigastrium. Similarly, this same

concept can be applied to the fleur-de-lis and reverse abdominoplasties. *Thus the more a procedure follows the vectors of excess of both what is taken and what remains, the more efficient the treatment of all redundant skin.*

Equally, the abdominoplasty should not only consider the obvious suprapubic pannus, but also *the deformity of excess tissue in the epigastric/midline, subcostal, and lateral chest*—zones that have generally been neglected by the modern abdominoplasty. This problem is significantly exaggerated in post-weight loss patients compared with average abdominoplasty candidates. However, the challenge cannot be ignored, and indeed, experience with post-weight loss patients brings significant clarity and urgency to addressing the issues. In fact, the good corrective techniques originally described many years ago have been equally neglected: the fleur-de-lis and reverse abdominoplasties. The solution is to reharness these procedures as a *complement* to the high lateral tension approach and in so doing, forge a more *comprehensive abdominoplasty*. Then, the inclusion of a vertical incision to the high lateral tension procedure makes a better fleur-de-lis abdominoplasty, and the staged application of a full submammary incision to the results of the HLTA creates a more powerful use of the “reverse” abdominoplasty. In effect, the abdominoplasty becomes a true rejuvenation procedure of the *entire* abdominal aesthetic unit.



This potential marriage of procedures is illustrated above. The vectors of skin laxity at the abdomen are marked and applied in each complementary variation of abdominoplasty. As one can see, *the more a procedure follows the vectors of excess, the more efficient the excision of redundant skin.* In turn, *the more vectors of excess that are addressed by surgery, the better the results.* Thus by building a suitable procedure using these harmonizing techniques, a more comprehensive abdominoplasty emerges.

To summarize, the primary advantage of these variations on the theme is the more inclusive repair of the entire anterior trunk. These procedures are entirely predicated



on careful discontinuous undermining and proper use of the superficial fascial system. Then one is assured of viable flaps and a secure and predictable final closure and scar.

However, the more extensive surgeries can be a disadvantage. These cases require more surgical time, longer and often a greater number of incisions, and planned but nonetheless greater closure tension, with the attendant increased risk of dehiscence.

Traditionally, the primary goal of any abdominoplasty has been to excise the suprapubic pannus and plicate the abdominal fascia through a relatively hidden incision. Unfortunately, this established abdominoplasty can fall short of this goal: a scar riding too high; persistent skin and subcutaneous lipodystrophy in the midline, thighs, flanks, and hips; and midline skin necrosis.

The comprehensive abdominoplasty addresses these shortfalls. It may be defined as a more complete treatment of the entire anterior trunk aesthetic unit from the submammary and lateral chest area to the pubic, thigh, and buttock zones, with a greater overall aesthetic result and margin of vascular safety.

## Pertinent Anatomy

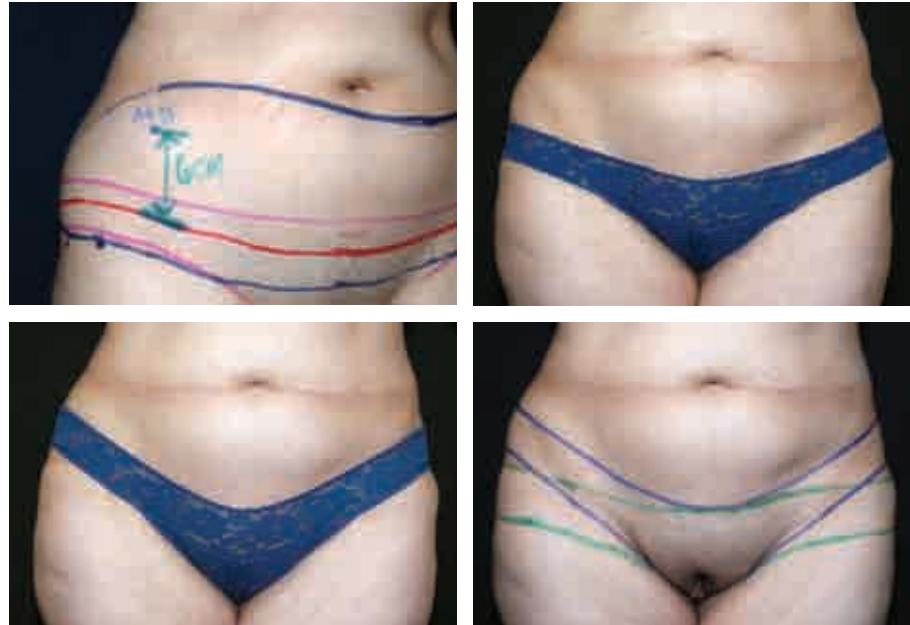The general abdominal anatomy is well described in the section of this chapter by Dr. Farzad Nahai. Therefore I will highlight the specific anatomy most relevant to the understanding and application of this high lateral tension abdominoplasty. There are three critical anatomic points that should be understood and respected when planning and performing the HLTA:

1. The superficial fascial system: this layer must be identified and utilized fully to harness the full lift that this technique can provide and to prevent wound dehiscence.
2. The perforator blood supply: the abdominal flap's viability is predicated on the preservation of as many fascial perforators as possible.
3. The zones of adherence: these various points of skin attachment must be released, at least bluntly, to realize the maximum "translation" of pull of the remaining skin envelope, particularly at the anterolateral thigh region. There is often what may be called a "waist band of adherence" at the patient's midsection that can significantly inhibit this same translation.

## Markings

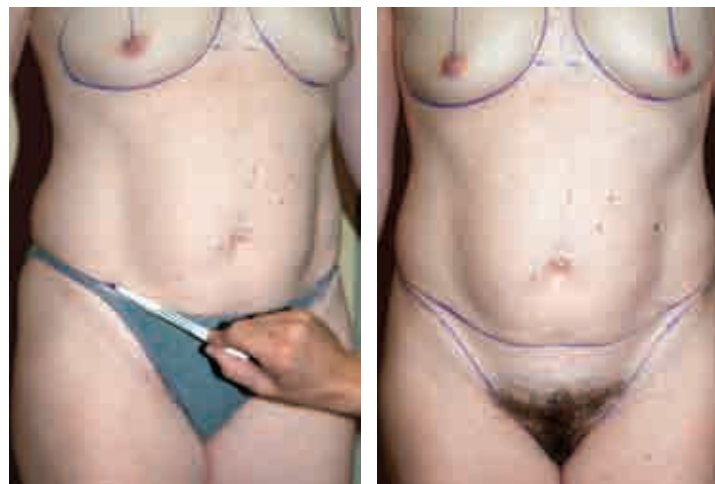The marking starts and is entirely driven by the delineation of the final position of the scar. The 2.0 modification ensures that the scar will rest within the patient's underclothes. The next marking outlines the extent of excess skin *below* the incision (if any) relative to the final scar, and the final marking is simply an estimate of the excess skin *above* the incision.

Marking is performed with the patient in an upright position against a wall so that she can be supported as necessary during the “tension” marking.

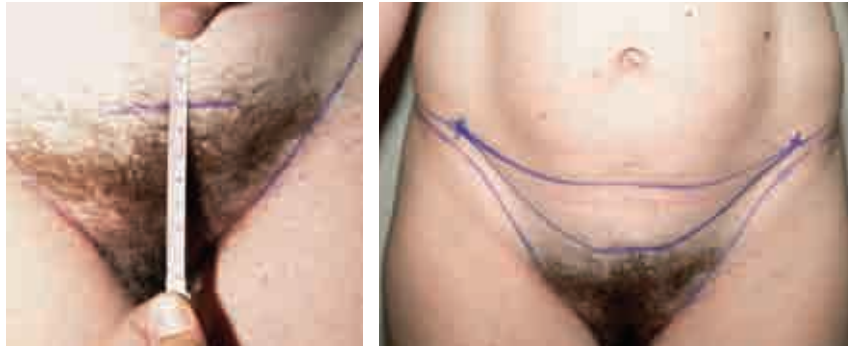

The placement and length of the lateral scar are discussed with the patient; this decision should be made by balancing the merits of the best surgical approach to treat the problem with the patient's preferences in clothing styles. The surgeon must consider the planned procedure with the patient wearing his or her most revealing clothing: underwear, a one- or two-piece swimsuit, and low-cut jeans. The incision will rise or fall at the hip markings, depending on the style of clothing.

### *Location of the Eventual Scar*



**Boundary marking:** First, the outline of the patient's preferred clothing is drawn (underwear, low-cut jeans, or a swimsuit).



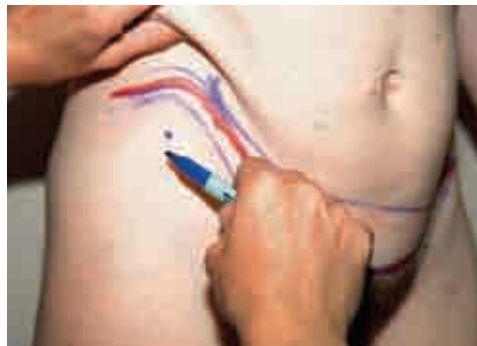**Suprapubic marking:** Next a point 6.5 to 7.5 cm measured superiorly from the upper incisura of the vagina or base of the penis is marked on the skin as it rests.

**Lateral limit marking:** A vertical line is marked on each side at the lateralmost extent of the excess skin (pannus).

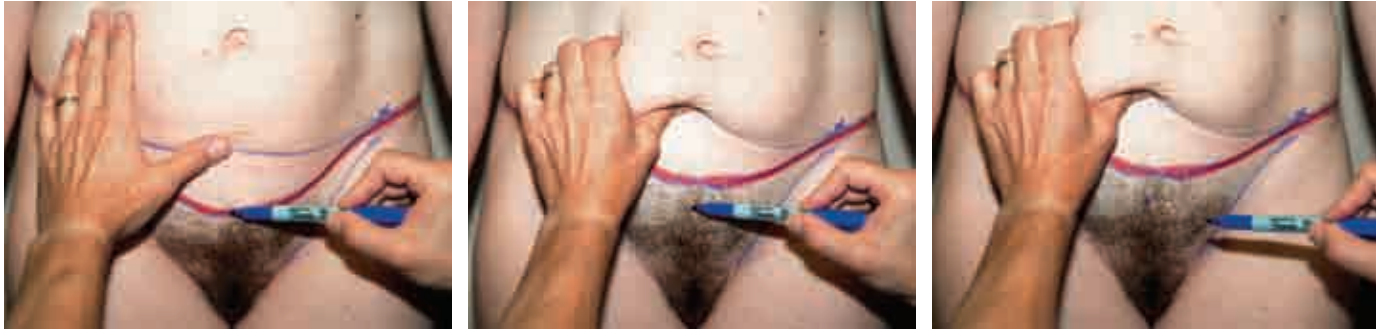**Closure marking:** Finally, the pen is moved superolaterally from this suprapubic mark on each side to meet somewhere along the lateral mark, always staying within the borders of the outlined clothing. This line usually rests between the natural inguinal and abdominal wall gullies. NOTE: One can measure the distance between the fixed point (anterior superior iliac spine) and this marking to aid in an intraoperative cross-check and adjustment of the final resting place of the closure.

To ensure a harmonious scar, particularly in a very “ptotic” patient, it is useful to extend the marking to include the design of a posterior body lift that may be planned or desired in the future.

### *Defining the Lower Margin of Excision*

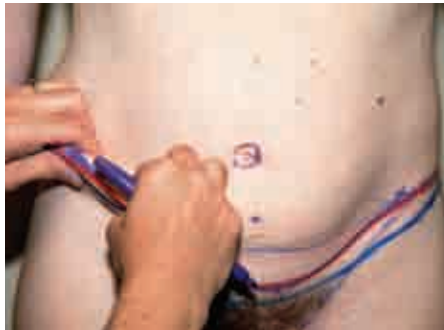

The marking pen is placed over the line of future closure, and this position is maintained while pulling the excess skin is vigorously pulled upward until taut (this is the “tension” in the HLTA); then the surgeon marks the skin that is now below the tip of the pen.



This maneuver is performed across the width of the abdomen as needed to define the lower incision. NOTE: Because the maneuver can and should be quite forceful, it is helpful to have the patient lean against a wall during the marking.

### *Estimating the Upper Margin of Excision*



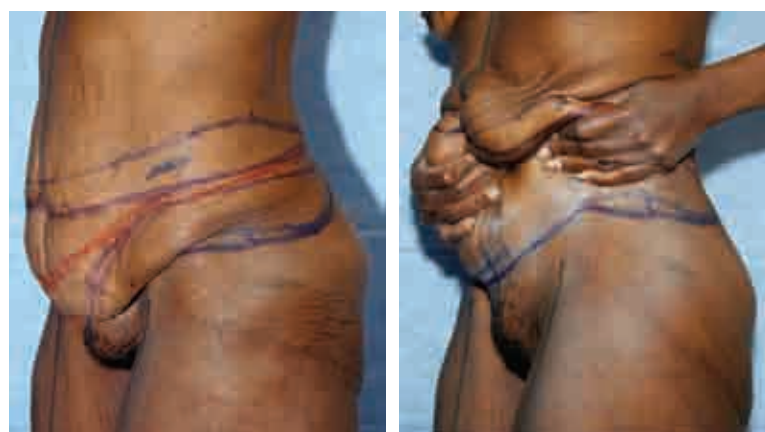The excess skin is pinched with the thumb on the lower incision line and the fingers at the superior extent of the excess, while maintaining the premarked final closure line visible at the middle of the skin roll. Marking begins laterally and extends medially. The resultant line will usually rest several centimeters above the level of the umbilicus laterally and a few centimeters below the umbilicus centrally.

### *Deciding How to Treat the Umbilicus*

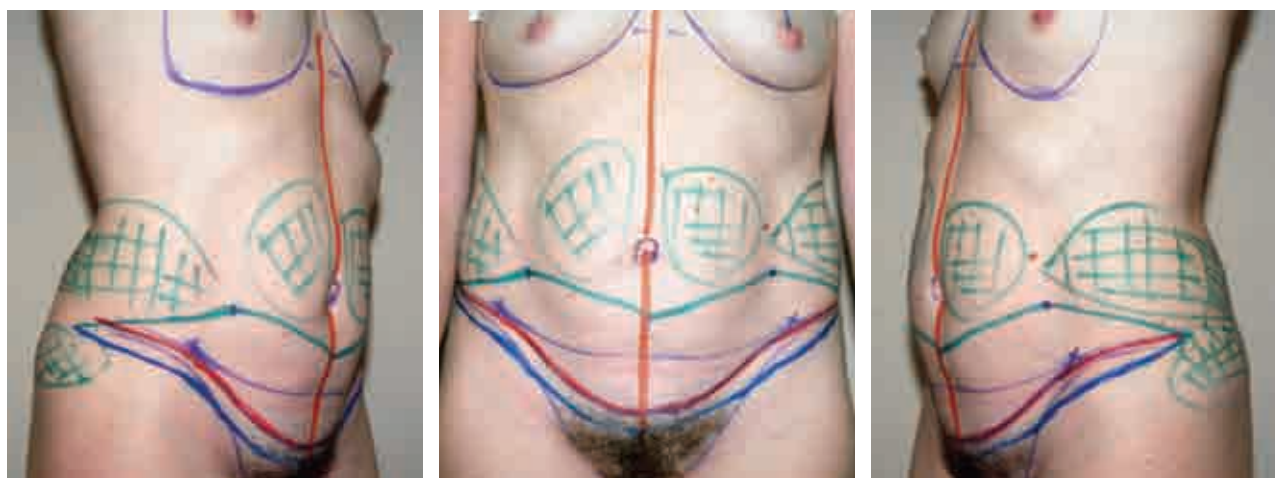
Depending on the patient's body habitus, the umbilicus should be about 9 to 12 cm above the superior margin of the pubis. The umbilicus should rest slightly above the latitude of the superior margin of the iliac crests. However, in the final analysis, as with many challenges in plastic surgery, a critical eye should ultimately drive the surgeon's decision.

The treatment of the umbilicus is determined by two factors: The amount of *excess* skin above and below the umbilicus and the *location* of the umbilicus in conjunction with the *length* of the abdomen and waist.

- If there is no excess above and mild excess below, the excision may be conducted with the umbilicus left intact, as a mini-abdominoplasty.
- If there is moderate excess below the umbilicus and little to no excess above, and the umbilicus appears high-riding on the abdomen, it can be maintained in situ and stretched on its stalk for a couple of centimeters.
- If there is moderate excess of skin below and above and the umbilicus is relatively high-riding, the umbilicus may be “floated” inferiorly with release of its stalk, again for a few centimeters.
- If there is a large excess, above and/or below the umbilicus, then it must be circumscribed and translocated.



The areas for liposuction are marked as needed, including the hips, waist, pubis, and thighs. Finally, the surgeon checks the surgical plan markings and reconciles expectations by simply instructing the patient to reproduce the desired result by performing an “examination room lift” (*right*). This maneuver is particularly valuable with a weight-loss or postpartum patient.



Green line: estimated upper incision

Red line: planned location of final closure

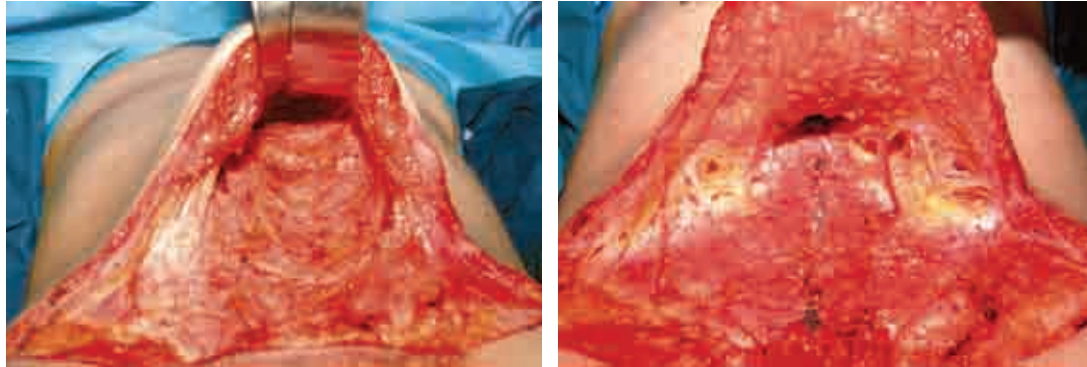
Blue line: defined lower incision

The final markings are shown above.



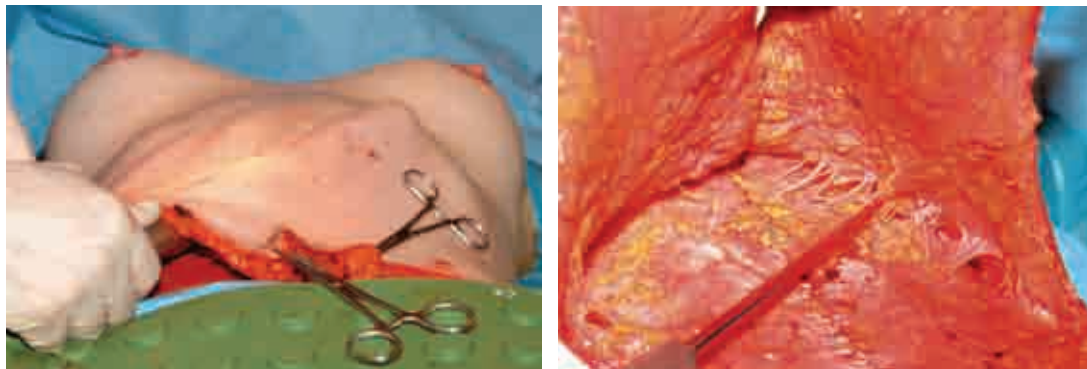
## Operative Technique

The patient is positioned supine on a warmer, an antiembolic compression device is applied, and a Foley catheter is usually inserted. With a needle and dye, the quadrants of the umbilicus are marked; the center point of the pubis and the estimated location of the future umbilical site are also marked.



The lower markings are incised and the skin flap is elevated off the deep fascia, just wide enough to allow plication of the rectus fascia. One should also attempt to leave behind as much of the fascial and particularly inguinal “lymphatic” tissue as possible.

Plication of the midline abdominal wall fascia is then accomplished using a heavy stitch (0 or 1-0 PDS) in a running pattern. The surgeon should try to avoid capturing any of the underlying muscle. A second running suture is performed to reinforce and allow for further plication of the fascia as necessary. Additional plication may be carried out in an oblique or horizontal vector at the anterolateral abdominal wall to narrow the waist and further flatten the abdominal wall.

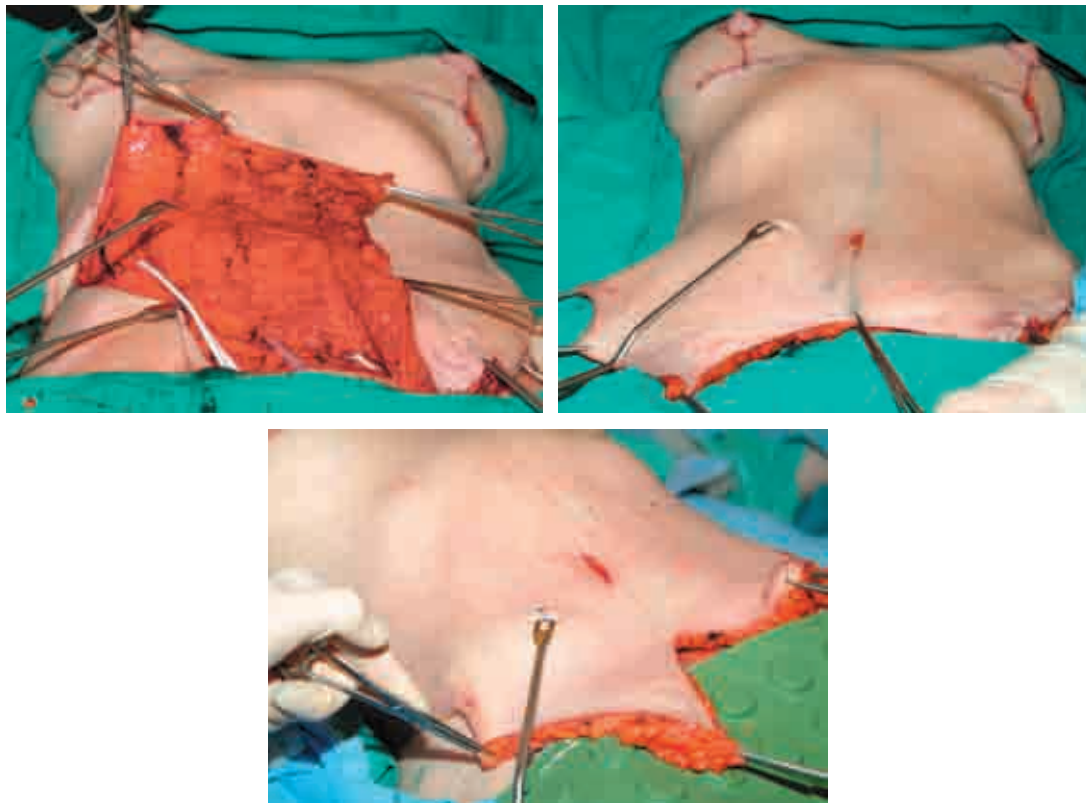


Further mobilization of the flap and release of the skin flap adhesions may be conducted cautiously beyond the midline. The guiding principle is to preserve as many perforators as possible. The surgeon could use either a measured, vertically oriented

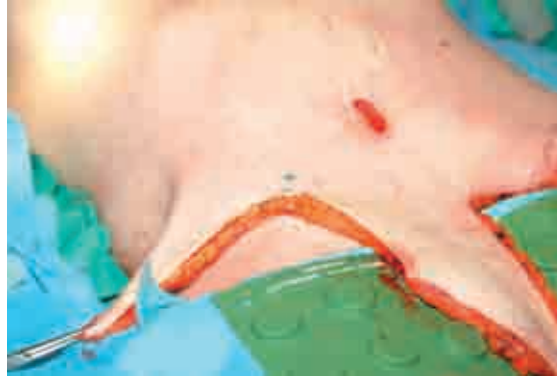

spreading of a large Mayo-like scissors or a gentle penetration with one or more fingers, oversized suction cannula, or, as I prefer, a Lockwood underminer cannula (Byron Medical, Tucson, AZ).

With a Lockwood abdominal demarcator (Byron Medical), a modified D'Assumpção-type clamp, the excess skin is marked for resection. This must be performed from the lateral aspect of the abdomen toward the center to truly carry out a high lateral tension resection. As an insurance maneuver, the preoperatively determined desired distance between the anterior superior iliac spine (ASIS) and the future closure can be checked intraoperatively and appropriate adjustments made (and more or less skin removed).



First, Kocher clamps are placed on the upper flap and the skin clamp tongs are secured into the skin edge of the lower margin of the incision. Then with simultaneous pulling of the Kocher clamps on the flap and the pushing of the Lockwood instrument at the lower incision, the excess skin is marked. The vector of pull of the flap is decidedly inferior and lateral.



The tip of the demarcator is pulled back a centimeter or so and the incision is skived to maintain a little more skin than subcutaneous tissue. In this way, when the deep closure is performed, the tension will be more on the fascia, and the skin will “heap up,” with virtually no wound tension.

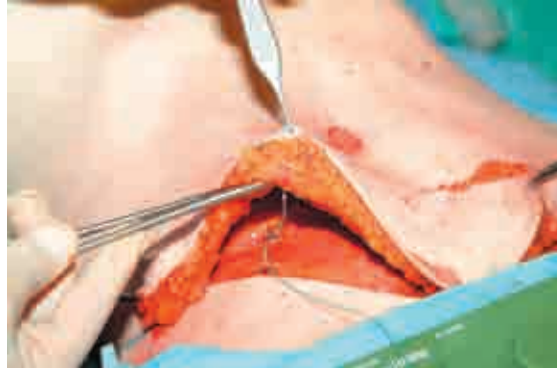An effort should be made to avoid closure over the ASIS itself to prevent additional tension to the wound. And contrary to the traditional approach, it is not necessary or desirable to place the operating table in a “lawn chair” position, because the Lockwood technique does not mandate the excision of all the infraumbilical skin and thus excess tension on the suprapubic closure and the resulting side effects are prevented.

As planned, not all the skin between the umbilicus and the pubis is usually excised, so depending on the amount of skin resection, the umbilicus can be stretched in place, allowed to float, or circumscribed and translocated with the original umbilical site closed vertically when necessary. As needed, a triangular segment of mons pubis can be excised if there is significant horizontal excess.

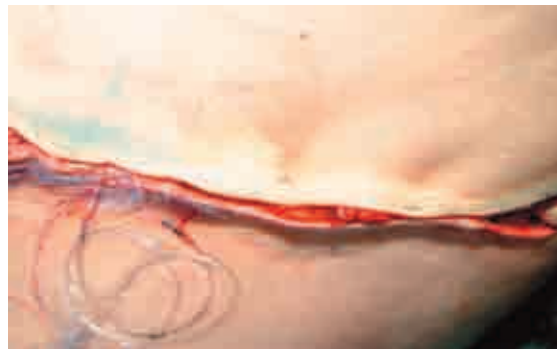Once skin is excised and tacking sutures are placed, tumescent fluid is suffused and liposuction conducted at the waist, hips rolls, pubis, and thighs as planned. The areas that deliver the greatest reward, yet are most often neglected, are the waist and the pubis.

The new umbilical site, when needed, is then incised in a *vertical* direction, since this wound will be pulled open to an appropriate shape with the significant lateral pull of the high-tension approach. A small elliptical excision of skin on either side of the vertical incision may be conducted as needed to increase the width of the umbilicus.

Three or four 10 mm flat drains are placed before closure, along with a bupivacaine catheter for postoperative pain control.



Bupivacaine may also be injected directly into the fascia for immediate postoperative relief. Using 1-0 or 0 PDS suture, the superficial fascial system is reapproximated every few centimeters. This is probably one of the most important steps in the whole operation. *The more confident one is of the fascial closure, the more definitive and aggressive one can be of the skin traction/resection.* The final closure is then made with 2-0 Vicryl for deep dermis and 3-0 Monocryl for superficial dermis.



The closure should have a decidedly rolled border, indicating no skin tension. Shortened Steri-Strips (to prevent edema-induced blisters) are placed. Fluffs are applied along with an abdominal binder to complete the dressing.

## Postoperative Care

Immediately after surgery, the patient is placed on a hospital bed in a “lawn chair” position, with the Foley catheter in place. The patient is transferred to an outpatient facility for 1 to 3 nights to ensure proper pain control and hydration, assistance with ambulation, showering, and so on. A spirometer, antiembolic pumps, and TED-like hose are all ordered for continuous use until the patient is ambulating regularly. The Foley catheter is usually removed at that time. Patients are given stool softeners once they are taking food by mouth. The pain-control catheter is removed in 4 or 5 days. Drains are left in place for 5 to 14 days, depending on the amount of drainage. The patient wears a Velcro binder as much as possible for up to 2 weeks; then the patient is encouraged to wear some form of commercial girdle-type compression undergarment for an additional 6 weeks.

## Complications

The entire purpose of the HLTA is to deliver the optimal correction with the lowest complication rate. Just as with Lockwood's original opus on the subject, the 2.0 upgraded version described here is predicated on a zero tolerance for complications. As well, many of these outcomes are not really complications but rather planned trade-offs for better or safer results. When a patient is informed of an expected residual deformity, he or she will then consider it as part of the surgical plan rather than as a complication; that is, the patient will then appreciate a secondary surgery as a stage rather than a revision. Otherwise, complications may include aesthetic mistakes, which may be irreversible, as well as physiologic misadventures, which can be devastating. These are discussed next, with a brief description of methods of prevention and treatment.

### *Aesthetic Complications*

#### **Abdominal Scar Too Long**

The scar can only be “too long” if the patient was not clearly informed of its often requisite length. The lateral scar is the primary literal footprint of the HLTA; that is, if any tension lifting is attempted at the lateral thigh and hip area, the incision will inevitably be longer. *Therefore the surgeon should critically evaluate this anatomy preoperatively and decide, with the patient's input, whether there is enough laxity to warrant extending the incision.* Otherwise, experience would indicate that as long as a scar is of good quality, corrects the deformities, and, what is most important to the patient, is hidden, the patient will always accept a lengthier repair.

#### **Lateral Scar Too High or Too Low**

In general, the greater the excess skin present, the more unpredictable the scar placement can be. This outcome is usually caused by a poor marking design; that is, an overestimation or underestimation of the magnitude of skin redundancy below the incision. There are several ways to avoid this problem, depending on the magnitude of redundant skin:

- If there is significant excess below the incision, there is a real danger of unpredictable scar placement (usually riding too high), and during the marking the surgeon must be certain to place the skin on maximum tension and, like any good tailor, measure twice and cut once—that is, recheck the markings and “test” them by having the patient recreate the lift by pulling up the excess tissues to the desired location.
- If there is not a notable excess below the incision (usually in the thicker, less mobile skin envelope), the scar could be predictably too low if too much inferior skin is removed. Therefore the surgeon should place the skin on less tension when marking.

- Intraoperatively, the preoperative measurement of the distance between the fixed ASIS and the desired level of the final wound may be used as a guide. It is best to be conservative with any additional resection (especially in a more adipose-filled flap), since the thigh skin below may drift inferiorly postoperatively.
- Finally, after surgery the surgeon should always critically assess the preoperative markings against the final result to properly hone his or her tailoring techniques.

### **Pubis Too Tall or Too Short**

A pubis with an incongruent height is usually the result of inaccurate estimation of the true redundancy of the pubic area. The surgeon must put the pubis on maximum stretch during marking and leave at least 6.5 cm of pubic height. The pubis can also be too wide, with the tension surgery potentially worsening the aesthetic effect. If necessary to prevent this appearance, a wedge resection of the pubis can be done concurrently or at a later stage. Again, the surgeon should always revisit and the preoperative markings and compare them with the postoperative scar placement.

### **Poor Umbilical Closure Scar**

Poor umbilical closure is often the most feared (more by the surgeon than the patient) but least realized complication. These scars uniformly resolve into short, thin, white lines. Rarely, a steroid injection or revision will be necessary. Even so, as the patient is made aware, this 1-inch scar is a small price to pay for the alternative: a 1½-foot-long abdominoplasty scar that rests too high, pulling the pubis along with it.

### **Residual Fat at the Suprascar and Central and Superior Abdomen: The Inverted-T**

This “complication” is more accurately a deliberate “neglect” of this subcutaneous fat in an effort to preserve the maximum blood supply to the central flap. The surgeon must decide what his or her individual tolerance is for the very real complications that may ensue from an attempt to remove this fat. Otherwise, patients are simply informed that they may be best served with a second-stage, unfettered abdominal liposuction procedure.

### **Residual Skin at the Upper Abdomen**

Residual skin is a complication not really unique to the HLTA. In fact, there is a good argument that because this technique has a more oblique vector of pull, it can efface more of this redundancy. However, the patient with significant excess (a second pannus) should be informed preoperatively of its probable persistence. Only a fleur-de-lis or reverse abdominoplasty can treat this zone definitively and should otherwise be considered in the first place.

### **Lateral Dog-Ears**

The best way to avoid lateral dog-ears is to fully liposuction this area and to intrepidly extend the incision as necessary, particularly the more tension-filled the lift.



**Epigastric Recurrent/Residual Protrusion**

Because of the more conservative dissection in the upper abdomen with an HLTA, in a patient with a very protuberant abdomen it is possible that a less than complete repair will be performed. Consequently, there can be some degree of epigastric recurrence/residual deformity postoperatively.

***Physiologic Complications*****Superficial Fascial System Stitch Abscesses**

The stitches used for the tension closure of the fascia are per force of large caliber with abundant knots. Therefore, stitch abscesses may arise postoperatively (surprisingly very late) particularly if permanent suture is used. This problem is far less likely with well-buried, absorbable sutures.

**Seroma**

Because there is far less dissection and no central liposuction with an HLTA, the annoying problem of seromas should be rare. For the same reason, the idea of flap adhesion stitches is not really applicable to the HLTA. When a seroma does occur, a consistent set of aspirations usually solves the problem within a few weeks. The primary modes of prevention include maintaining the web of lymphatic-containing tissue overlying the fascia and groin when elevating the flap, and placing multiple drains (three or more).

**Deep Venous Thrombosis and Pulmonary Embolism**

Volumes of analysis and advice have been written on this subject, particularly in the last few years. Clearly, with good patient selection, consistent use of antiembolism pumps, and early mobilization, the incidence of this problem should remain rare. As for chemical prophylaxis, considering the still unsettled status of this approach, the surgeon should always refer to the latest recommendations in the literature.

**Skin Necrosis**

Skin necrosis is a dreaded complication that can occur if the surgeon pushes the envelope during surgery: the usual culprits are maneuvers of overaggressive flap mobilization in an effort to remove the maximum amount of redundant skin (particularly from the upper half of the abdomen) and excessively zealous flap fat removal (by liposuction or direct excision) to thin the flap as much as possible. Unfortunately, the patients who would need these additional efforts to be taken are often the candidates that present the greatest risk, with high BMIs and massive excess of fat and/or skin. And for the patients who fall in between, there is no accurate selection mechanism to determine who will do well with these more-invasive techniques; therefore surgeons must decide for themselves between “blood and beauty.”

## Outcomes

The essential advantage of this technique is the ability to deliver consistently superior and safer results:

- The incision is maintained low and hidden within the patient's clothing.
- More skin is removed below the incision both laterally (which, in effect, results in a significant "lift" of the anterolateral thighs) and centrally (which promotes a lift of the pubis and anteromedial thighs).
- There is little opportunity for flap ischemia because a maximal blood supply is maintained: local perforators are preserved with judicious and discontinuous undermining, and the flap's integrity is respected with restraint of any liposuction or direct fat removal from the flap itself.
- There is less tension at the lower central abdomen, resulting in a lower incidence of flap ischemia and a more aesthetically pleasing mild convexity at the hypogastrium.
- The excess skin in the horizontal plane of the abdomen, particularly in the upper poles, is more effectively treated with the oblique vector of excision.

Any residual fat, particularly within the abdominal flap itself, can be treated aggressively, with relative impunity, as a second-stage procedure within 6 months to a year of the abdominoplasty.

If there is residual skin resting laterally and posteriorly, this can be addressed at a second-stage procedure with a posterior extension of the abdominal incision for a completion posterior body lift. If there is remaining skin superiorly at the epigastric and subcostal areas, this can also be treated later with either excision through submammary incisions or with a proper reverse abdominoplasty.

If the lateral scar rests slightly outside the patient's preferred clothing, the scar can be easily moved up or down by excising the appropriate amount of skin with the patient under local anesthesia.

## Fleur-de-Lis Abdominoplasty

Dellon first popularized the fleur-de-lis technique in 1985. He pointed out that his technique was an extension of Regnault's classic "W" technique. For a longer historical perspective, the fleur-de-lis, as Dellon describes, is really a direct, albeit melded, descendant of the transverse resection technique described by Kelly in 1910 and the vertical resection approach considered by Babcock in 1916.

The basic principle and power behind the fleur-de-lis approach is the ability to definitively excise not only the traditional lower abdominal pannus but also much of the aforementioned redundant upper abdominal tissue. Put another way, this approach realizes a more complete resection of not only the vertical but also the horizontal vector of excess. But it is important to realize that this technique, in contrast to its original description, can now be “supercharged” with the addition of the high lateral tension procedure. The corollary would be that the fleur-de-lis is really an HLTA with the addition of a vertical incision. Thus the fleur-de-lis approach becomes even more potent at correcting the entire abdominal unit. In fact, if a reverse abdominoplasty is also included, either conservatively at the time or in a staged repair, this trio of techniques can make the most complete and impressive correction.

In combination with the high lateral tension technique, the fleur-de-lis can deliver far-reaching effects: in addition to recontouring the upper abdominal zone with direct excision, there is an indirect corset effect of the entire anterolateral chest, the flank, and the back. In fact, this technique can truly address the residual excess skin rolls beyond the pannus, tissues often left untreated by any “regular” abdominoplasty. This advantage is particularly relevant in weight-loss patients. In fact, in these patients, when the surgeon has completed a proper fleur-de-lis resection, the extent of skin resection can expose most of the anterior abdominal wall. Then, dramatically, the peripheral “waistcoat” of skin, lying in the wings, advances to close the defect.

## Markings

The basic principle behind the marking of the fleur-de-lis is to evaluate, measure, and mark the horizontal excess independent of the vertical redundancy.

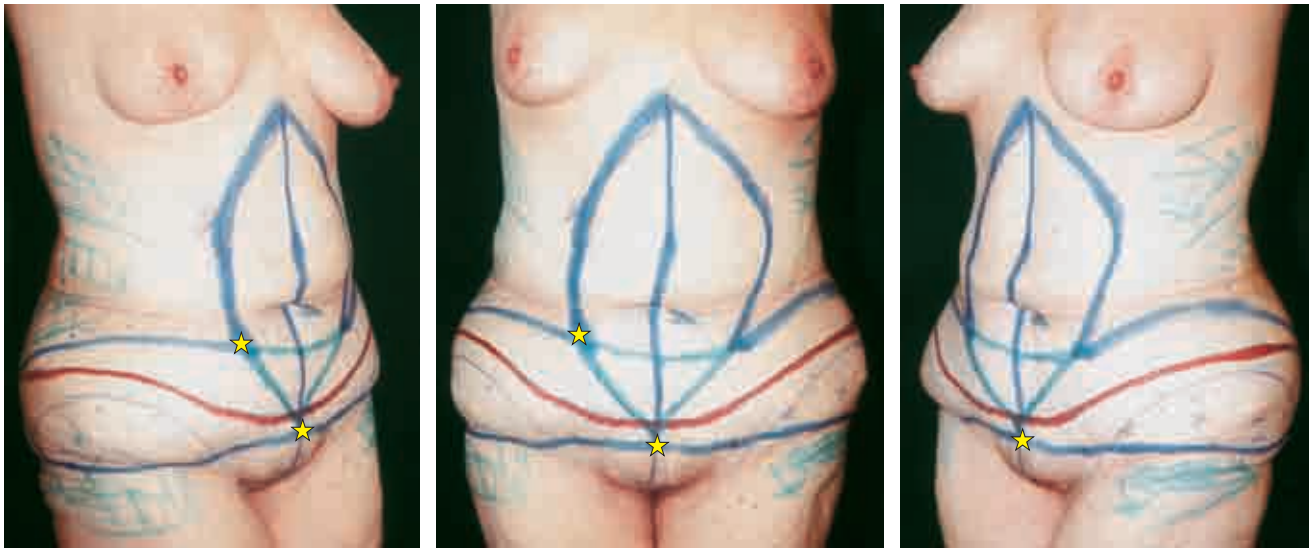
**Horizontal marking:** With the patient standing, HLTA marking is performed as though it were to be the only procedure planned.

**Vertical marking:** Next, with the patient supine, the horizontal excess is outlined, again as though it too were the sole surgery to be conducted. The surgeon simply gathers the excess skin with an aggressively wide pinch, marks the margins, and “connects the dots” to realize the vertical marking.

**Fleur-de-lis design:** With these two apposing markings, the outline of the fleur-de-lis is actually realized. The outline of the intersecting markings is drawn to define the borders of the fleur-de-lis abdominoplasty.

**Key point:** The pivotal point in the marking is the intersection of the horizontal and vertical markings laterally. This is the best estimation of the location of the wound edge that will ultimately contribute to the inverted-T closure.

**Marking test:** The excess skin is inverted and the T closure is reproduced. Clearly, the thinner the patient, the easier and more accurate this maneuver will be. The primary objective of this step is to estimate the adequacy of skin for comfortable closure of the T wound. Otherwise, one runs the risk of an excessively tight closure that in turn can lead to problems ranging from an unaesthetic, constricting, high-riding scar and pubis to a devastating skin necrosis.

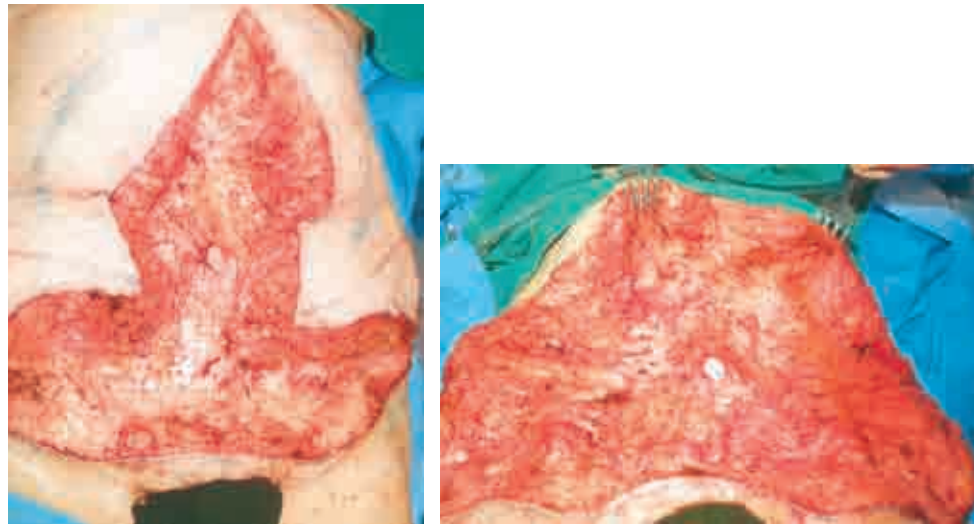


The final markings are demonstrated. The yellow stars indicate key points marking the tips of the upper flaps and the midline of the suprapubic area. The blue lines are the estimated margins of the fleur-de-lis. The red line is the estimated future site of the scar.

**NOTE:** The only marking that is actually used in surgery is the lower horizontal line of the HLTA portion of the design, with the rest of the outline acting as guideposts. *The important point is to reserve final judgment regarding the margins of excision until surgery.*

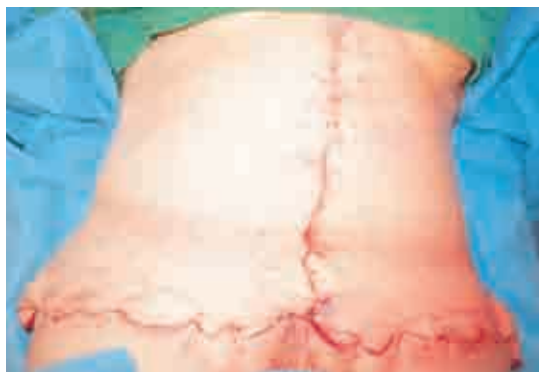It is very important to *resist marking the superior pole of the incision much above the xiphisternum*, which could cause the final closure to rest between the breasts (and even worse, cause symmastia). That is, one should expect the upper wound to ride up several centimeters with the removal of the heavy abdominal skin and closure of a very wide wound.

## Operative Technique



The horizontal and vertical premarked incisions are performed down to the underlying fascia.

The skin flaps are raised cautiously, roughly within the boundaries of the premarked fleur-de-lis template, to preserve the maximum blood supply. Routine abdominal plication is then performed using a 1 or 0 Ethibond type of suture in running, locking fashion.

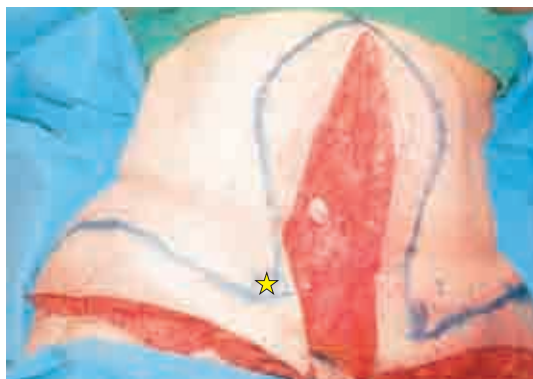

Then, using a large staple gun or suture and an assistant's help, the surgeon vigorously tailor-tacks the wound by rolling the excess skin below the flaps. *As described previously, it is critical that one begin this tailoring at the suprapubic inverted-T wound to confirm that there is adequate skin for closure.* In effect, this medial commencement of tacking is opposite the traditional Lockwood abdominoplasty in which the excision is estimated and conducted starting laterally.

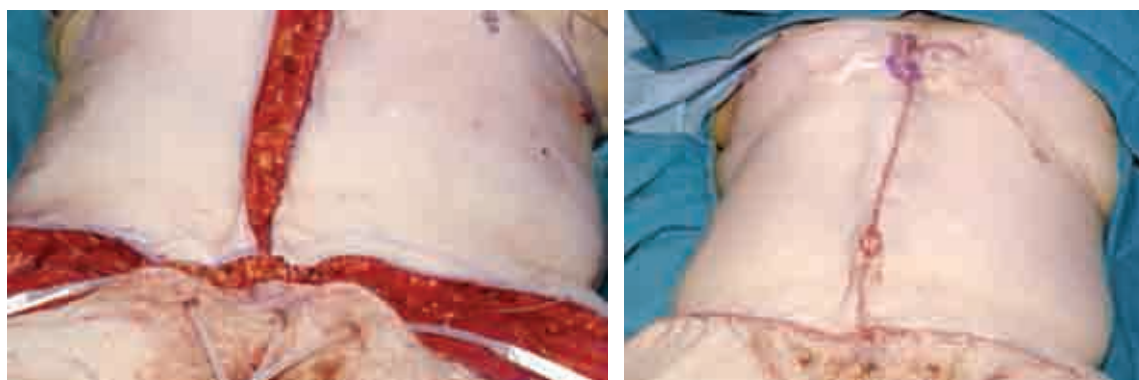
Once the lower midline closure is estimated, the tacking should continue alternately between the midline toward the xiphisternum and laterally toward the hip, in an at-



tempt to evenly distribute the estimated excision of the excess. As noted earlier, *the surgeon should not tailor-tack the vertical closure superiorly any higher than the xiphisternum* to ensure that the eventual scar lies on the abdomen rather than between the breasts.



The excess skin is then marked at the margins of the tailor-tacking, and the skin is excised through both the vertical and horizontal incisions.



Then the T closure is tacked again to guarantee the adequacy of the skin for closure. At the vertical wound, one can often tailor-tack and excise skin a second time, especially in a patient with very thick or excessive skin. Any remaining skin at the horizontal wound should be removed, as one would with an HLTA using the Lockwood skin clamp.

The closure is then performed in the same manner as in a routine abdominoplasty. An ellipse of the wound margin from each flap is excised at the site of the umbilicus, which is then inset.

With experience, particularly in thinner patients, the surgeon can consider just tailor-tacking the skin at the inverted-T closure only, directly excising the vertical marking and then applying the Lockwood abdominoplasty to the lower excess.

## Problems and Complications

The midline scar can extend too far superiorly with the creation of some synmastia unless care is taken to prevent its migration. The primary tactic to avoid this problem is marking the repair deliberately no higher than the xiphisternum and resisting the impulse to chase the excess skin superiorly onto the chest. Also, if the tacking or excision itself is not symmetrical, the vertical scar can be crooked. If this is noted at surgery, an attempt at correction should be made with the necessary skin resection from one side or the other.

## Outcomes

The effects of the fleur-de-lis procedure can be the most dramatic of all abdominoplasties: because of the significant recruitment of skin from the lateral trunk, an impressive correction is made at the waist, back, and flank folds. With excision of most of the horizontally redundant skin, particularly at the upper abdomen, the result is clearly more complete. Additionally, because of the wide exposure of the fascia, the abdominal wall deformity can be fully corrected with this technique. This is especially true in the epigastric area, where the repair can be otherwise constrained by the HLTA's narrow tunnel of dissection.

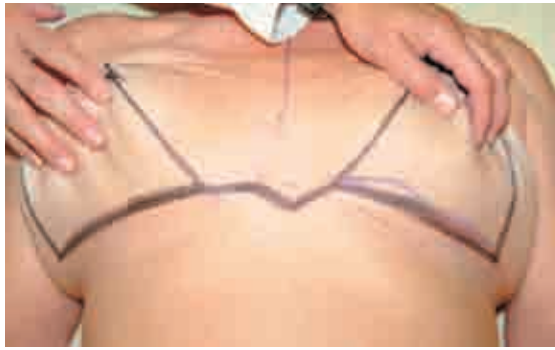The inverted-T scar heals surprisingly well and becomes a thin white line. Despite the impressive dissection, since primarily all the undermined skin is excised (especially the suprapubic swath of skin), flap ischemia is not a major concern.

## Reverse Abdominoplasty

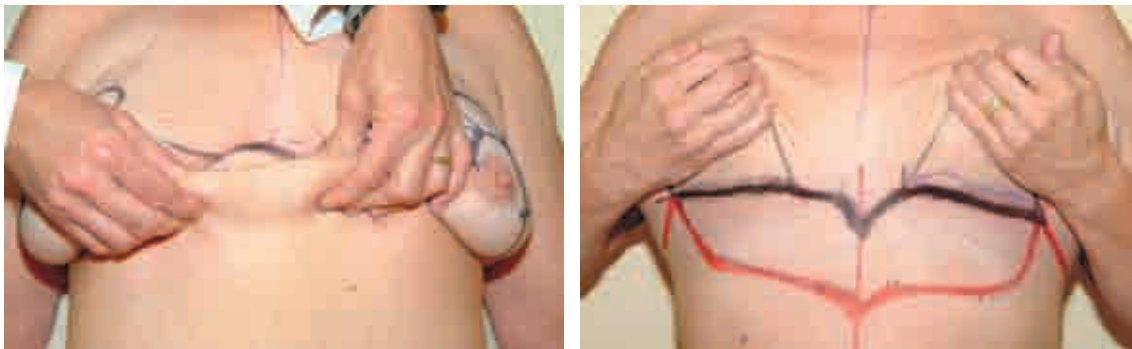The reverse abdominoplasty was initially described in 1972 by Rebello and Franco in the South American literature. In 1979 Baroudi et al published the first paper in the United States describing the technique in combination with reduction mammoplasty. The reverse abdominoplasty is most efficacious when combined with the other abdominal contouring surgeries already described; that is, the principal indication for reverse abdominoplasty is for cleanup of the residual redundant tissue at the superior abdominal pole after any lower abdominoplasty. This approach is particularly relevant when treating weight-loss patients. Even after proper application of the high lateral tension technique, a reverse abdominoplasty should be anticipated as a second stage. Otherwise, this technique is indicated in the relatively rare patient who presents with skin excess and abdominal protuberance primarily in the upper pole of the abdomen. The utility of this approach is even more compelling if the majority of striae and surgical scars are also principally confined superiorly. A reverse abdominoplasty may be easily married to a Wise pattern breast procedure, since joining the two submammary incisions entails only a few centimeters of additional scar.

Otherwise, with more limited skin excess, direct excision of skin through separate submammary incisions could be considered, particularly in a Wise pattern type of breast surgery.

## Markings



The patient is marked in the supine position. The upper margin of the skin resection is outlined initially. The mark should start as far lateral as the excess skin demands, always maintaining the final closure within the bra strap line. The markings then continue along the submammary line, with the two sides meeting at the epigastrium as a V. If there is to be concomitant breast surgery, the mammary markings should be conducted first.

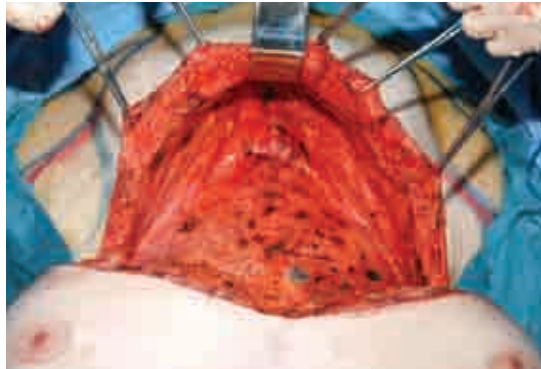


The excess skin at the upper pole of the abdomen is then pinched and pulled superiorly, and an approximate line of redundancy is marked. The extent of excision is guided by observing the maximum tautness of the upper abdominal skin.

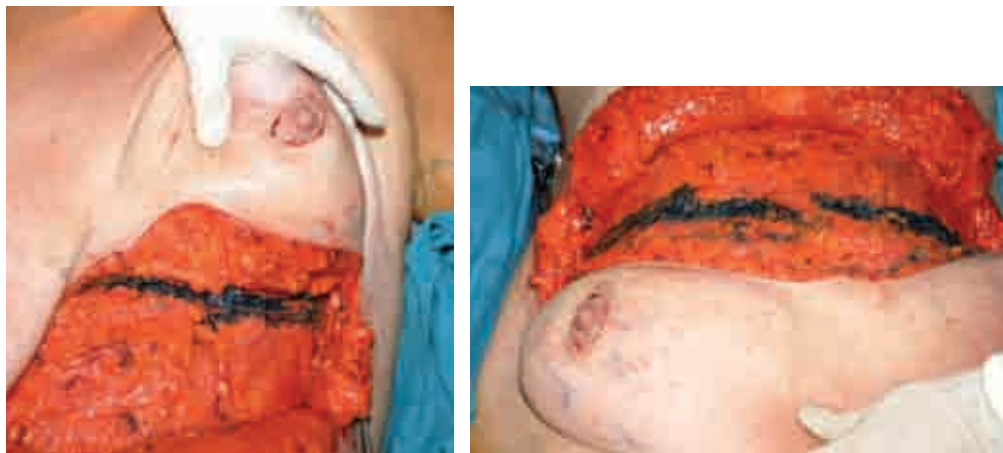The mobility of the inframammary crease is gauged. The more ptotic the breast, the greater the potential inferior displacement of the crease. Thus the crease must be secured at the time of surgery.

The laxity of the umbilicus (the length of its stalk) must also be assessed. The surgeon should attempt to prevent excessive superior displacement of the umbilicus with advancement of the upper flap.

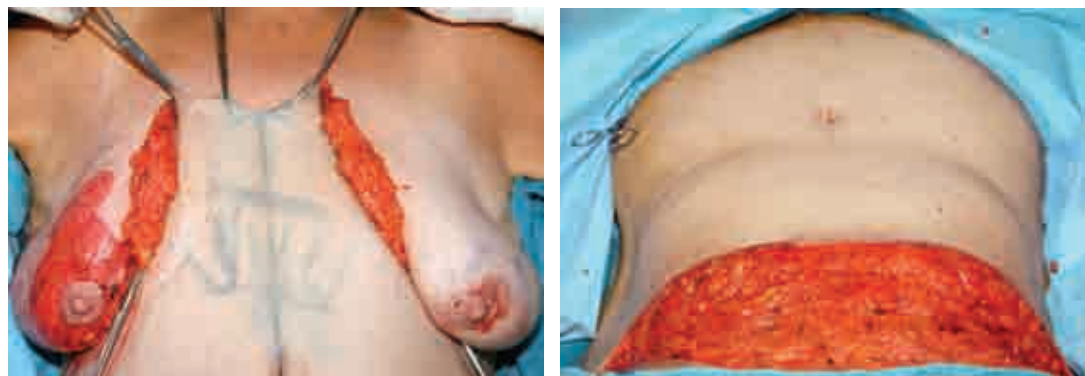## Operative Technique



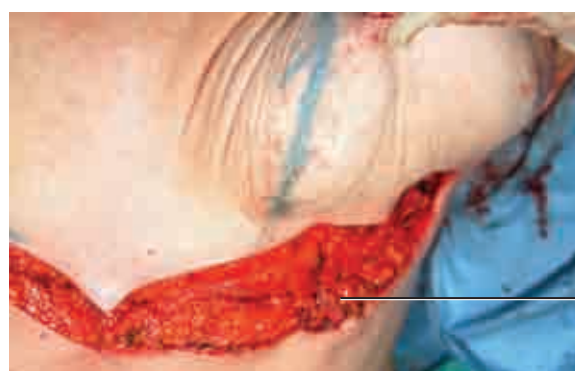The upper incision is made and the abdominal flap elevated several inches beyond the skin redundancy. This dissection should be no farther than several centimeters from the umbilicus to block the potential excessive advancement superiorly.



The most critical step in this technique is to define the inframammary fold at the appropriate level so that the skin excision can be more accurately estimated. This is accomplished by first marking the position of the future breast fold on the chest. This should be done with the patient in the upright position to more accurately determine the natural coordinates of the inframammary fold. Otherwise, in the supine position, the fold can rise unnaturally by several centimeters, and the eventual crease could then be sutured too high.



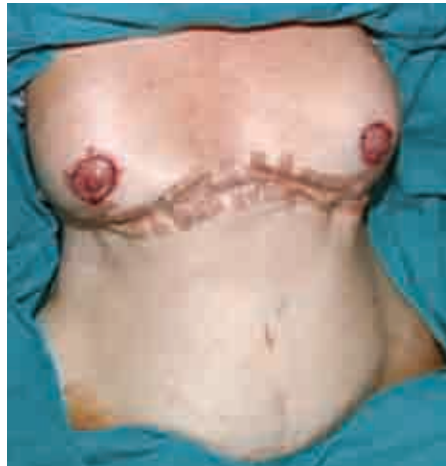Using Kocher clamps and upward and slightly lateral traction, the surgeon marks the excess and sequentially excises it. As with the abdominoplasty, skin excision is made 1 or 2 cm more proximal to the marked excess point to prevent too much wound tension. The resultant wound can be as much as 6 to 8 inches in height.



Superficial fascial system sutures

The upper abdominal flap is then inset along the now “tamed” inframammary crease. The deep fascia is employed to ensure a secure closure, along the length of the chest using 0 or 1-0 PDS-type suture. As with the abdominoplasty, the suture should be placed in the superficial fascial system approximately 2 cm behind the upper margin of the abdominal flap to ensure a rolled, tension-free skin closure. If a breast lift or reduction is to be performed at the same time, it is preferable to perform the reverse abdominoplasty first. This surgical order creates a solid shelf on which the breast can then be built. Otherwise, a completed breast repair may be compromised by the possible recruitment of some of the lower breast skin when the abdominal flap is inset.





Final closure is similar to that for routine abdominoplasty, using 2-0 Vicryl for the dermis and 3-0 Monocryl for the skin. Two 10 mm drains are placed before closure.

## Problems and Complications

With or without a concomitant breast surgery, the sheer heft of the inset abdominal flap can result in some deformation of the breast shape as the tissues relax. The best measure of prevention is to “overengineer” the repair of the abdominal flap to the defined inframammary crease, with an abundance of sutures.

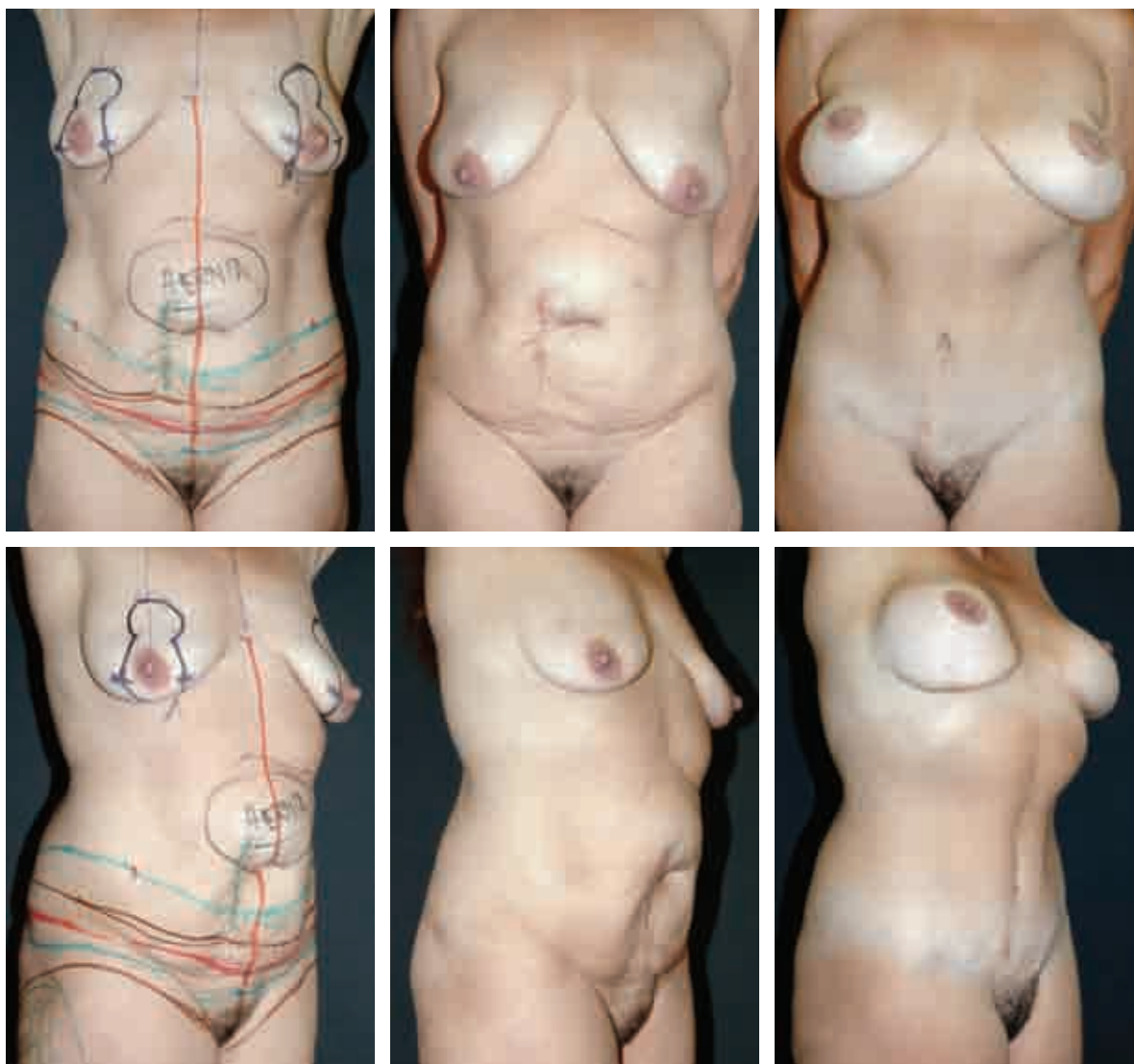
By virtue of the advancement of the upper abdominal flap, the umbilicus can be tethered superiorly. This is particularly true with an umbilicus with a longer stalk. Maneuvers to resist this displacement include reining in such a stalk with direct sutures to the rectus fascia and halting the upper skin flap mobilization several centimeters above the umbilicus.

## Outcomes

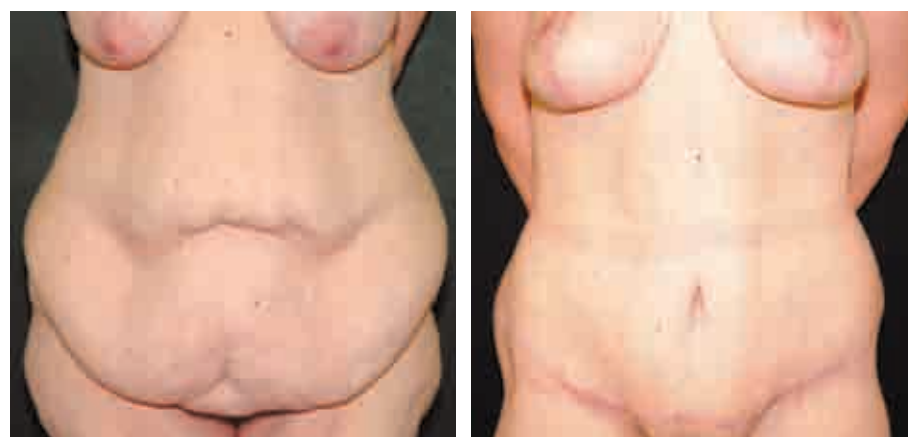With an aggressive application of the reverse abdominoplasty technique, there can indeed be a rewarding correction of the disturbingly persistent excess skin at the upper abdomen after a routine abdominoplasty. The central 3 inches of additional scar resting between the breasts heals remarkably well. It can be even more inconspicuous if it is designed to rest inferiorly in a V shape. Postoperatively the breast should remain in a stable, aesthetic position as long as a secure reinsertion of the abdominal flap is performed at the appropriate inframammary level. Some superior advancement of the umbilicus can occur despite all efforts to the contrary.

## Results

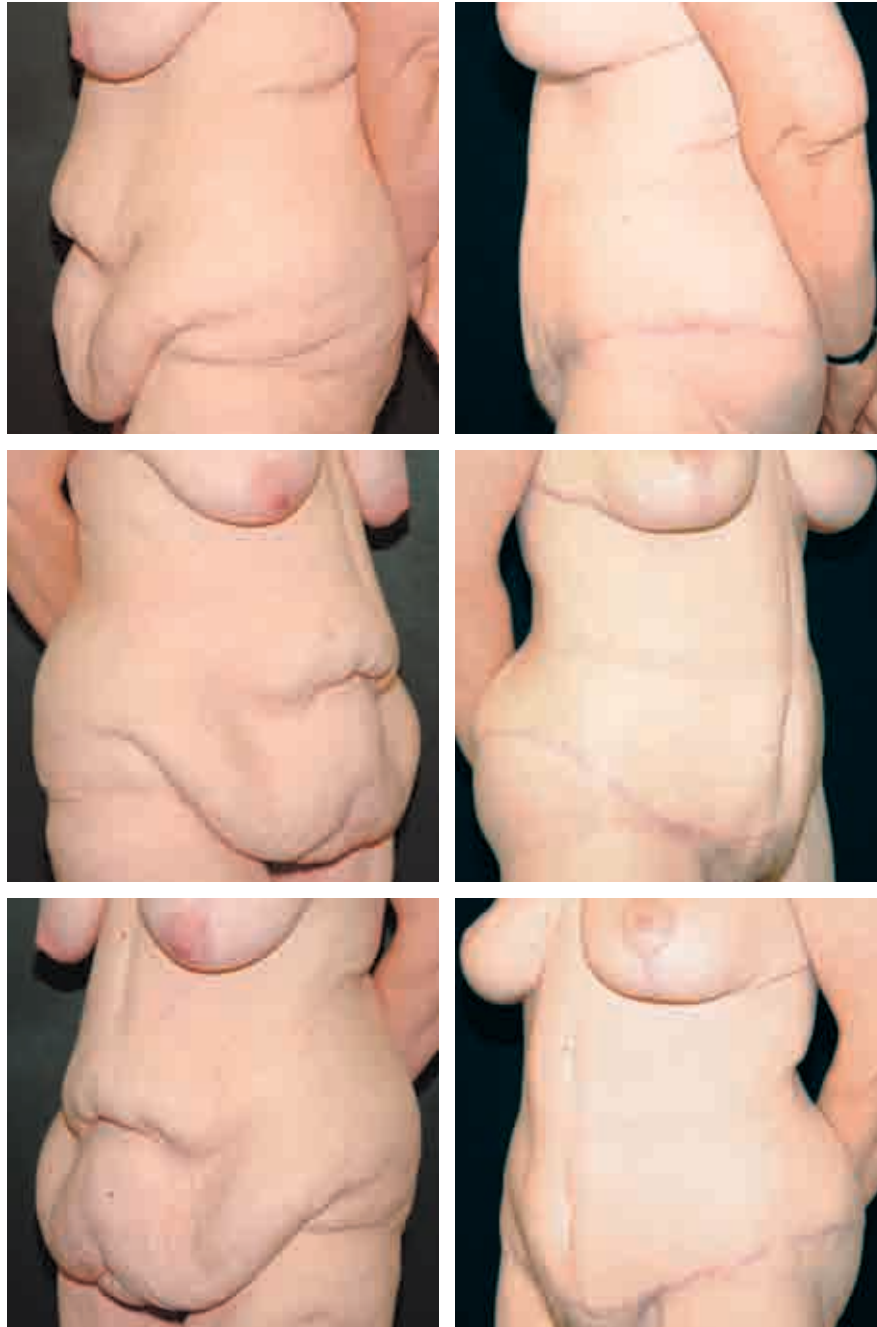
### High Lateral Tension Abdominoplasty

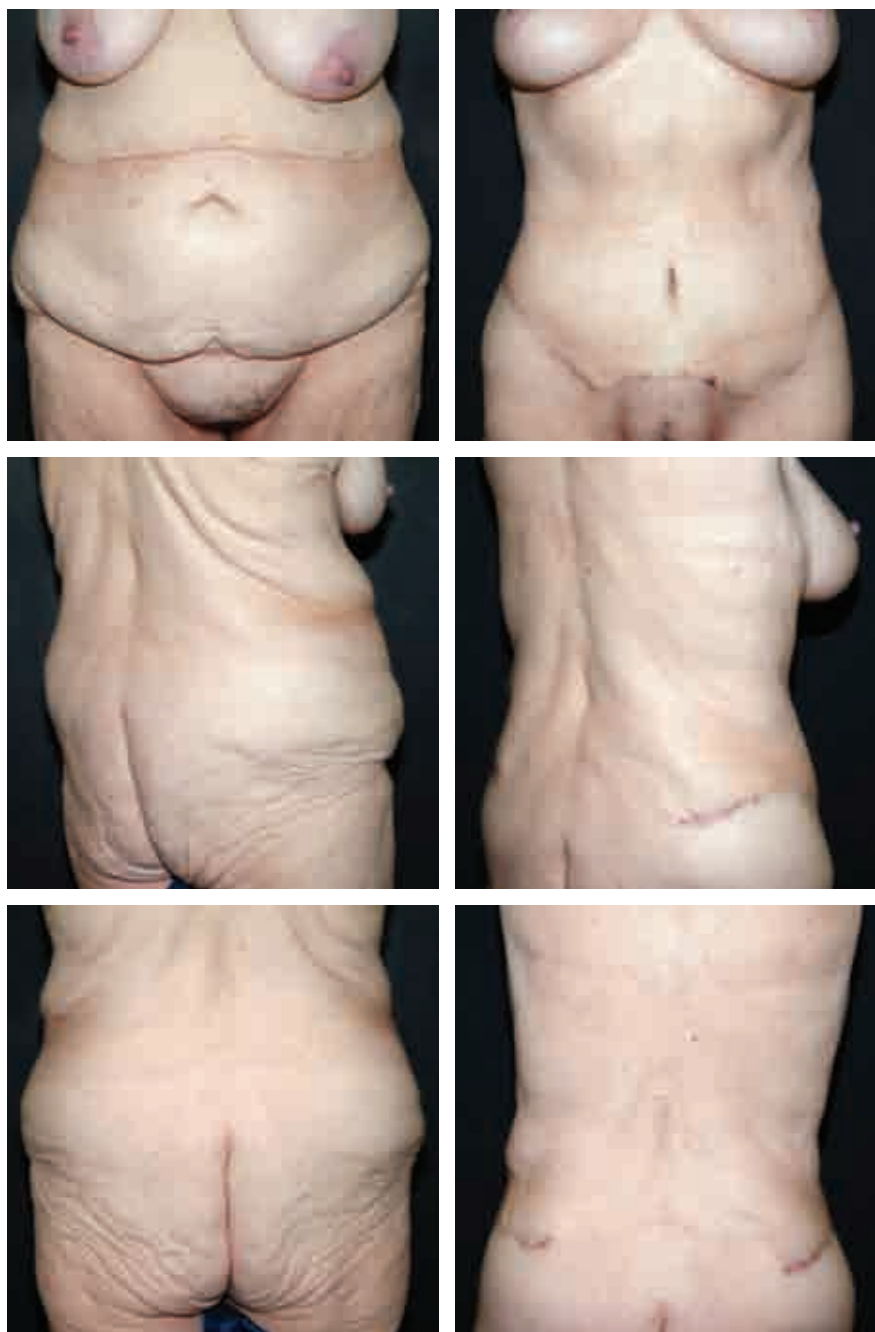

This 46-year-old woman who had had four children requested abdominal repair after her last child was born. A high lateral tension abdominoplasty was performed, along with a mastopexy/augmentation. She is seen 4 years postoperatively, revealing evidence of the significant lateral excision accomplished with this technique, by virtue of the removal of her entire tattoo. The benefits of the HLTA with a more aesthetic waistline and smoother epigastric zone are apparent.



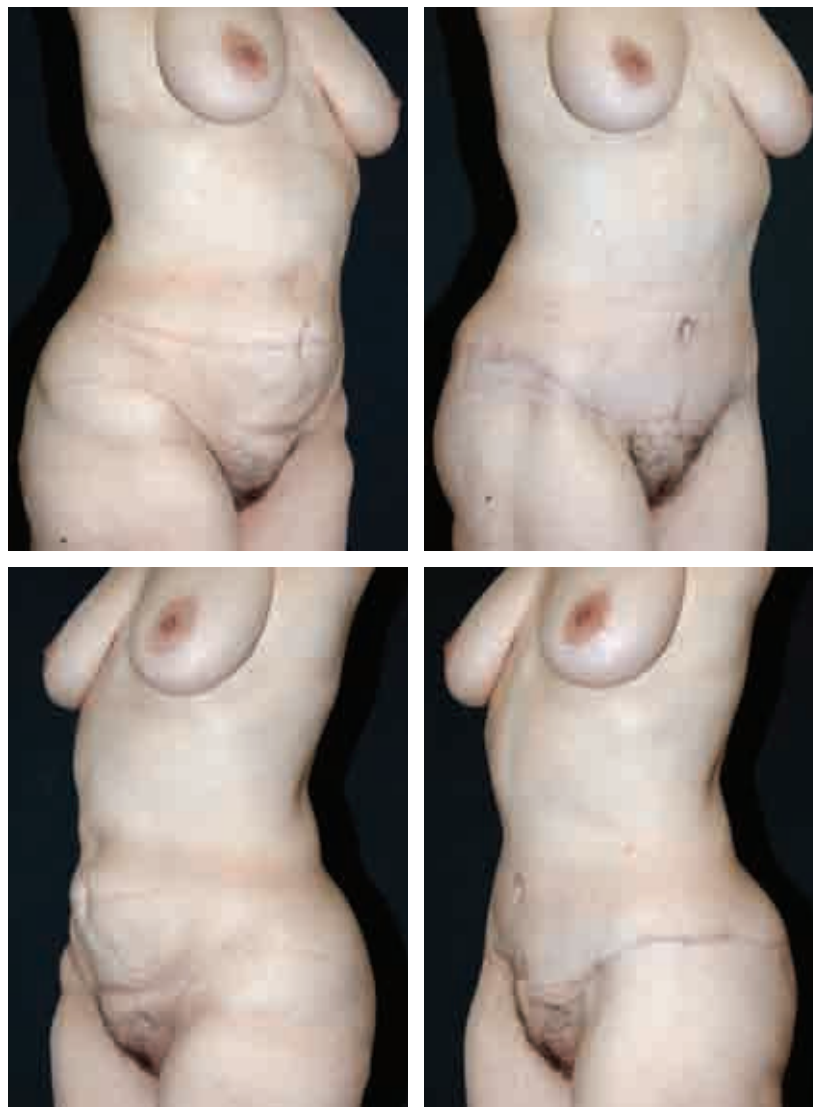
This 46-year-old nulliparous woman was seen after losing 66 kg (145 pounds) following a gastric bypass. She did not want a midline scar, but otherwise desired as much improvement as possible. She underwent a high lateral tension abdominoplasty with liposuction of the hips and lateral thighs. A mastopexy was performed at the same surgery. Note the presence of the supraumbilical line of demarcation carrying the more redundant skin above. Therefore dissection was deliberately discontinuous in this area and the patient was informed of the likelihood of residual epigastric excess postoperatively. She healed without complication. She is seen 8 months postoperatively. Note the correction of the abdominal deformity, even in the epigastric area, because of the oblique vector of its excision. The HLTA's body-lift effect was realized in the anterolateral thigh and buttock areas.



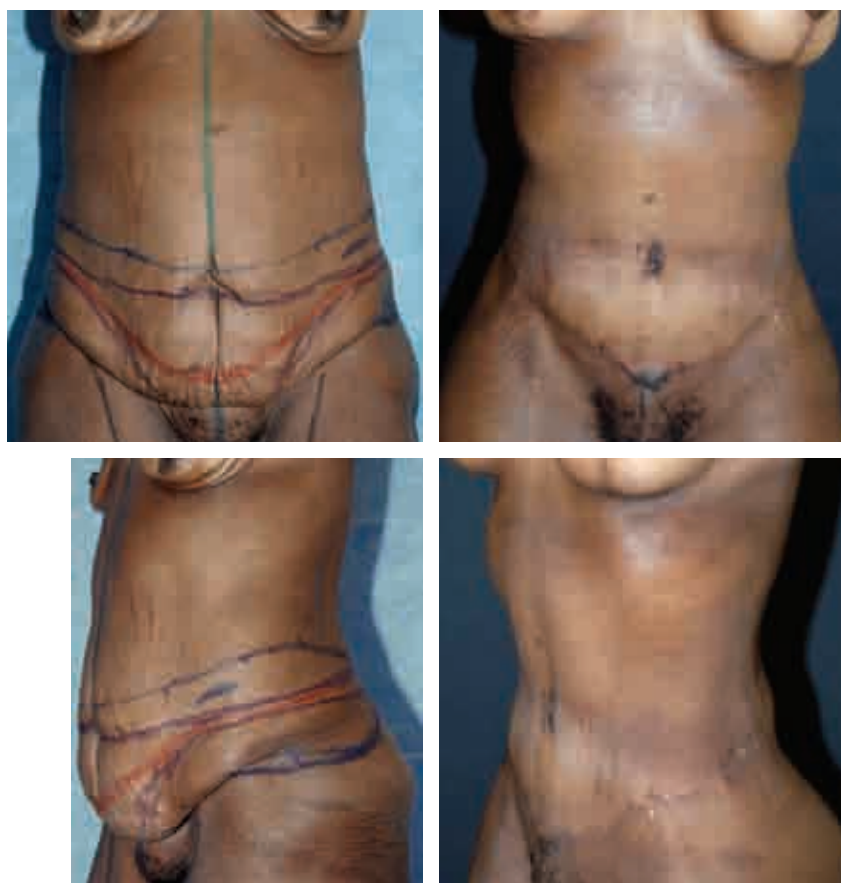

This 57-year-old woman had had two children and had lost close to 45 kg (100 pounds). She underwent an HLTA with liposuction of the hips and thighs and a breast reduction. Note the reconstitution of an aesthetic abdomen and the lifting of the buttocks.

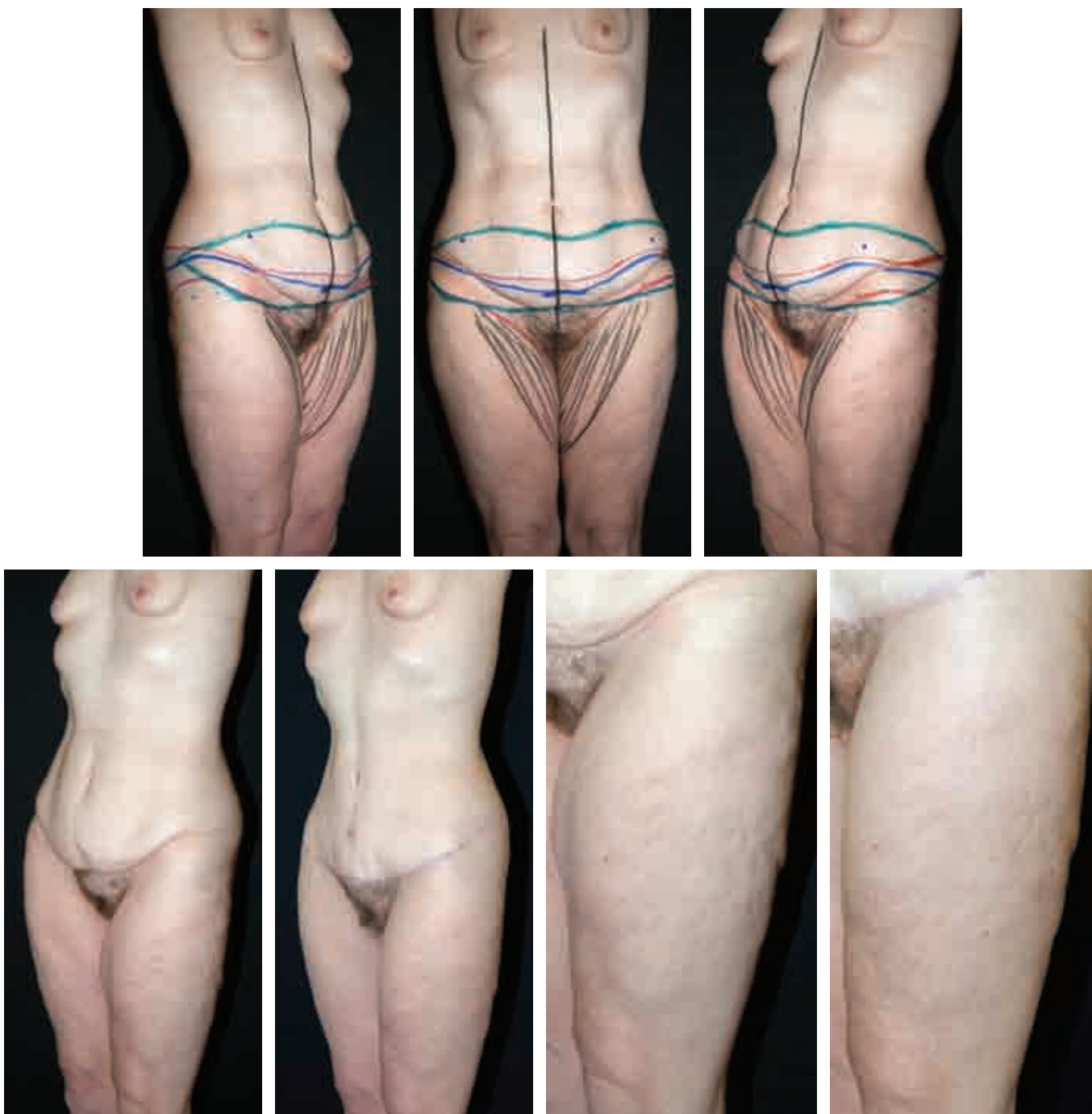



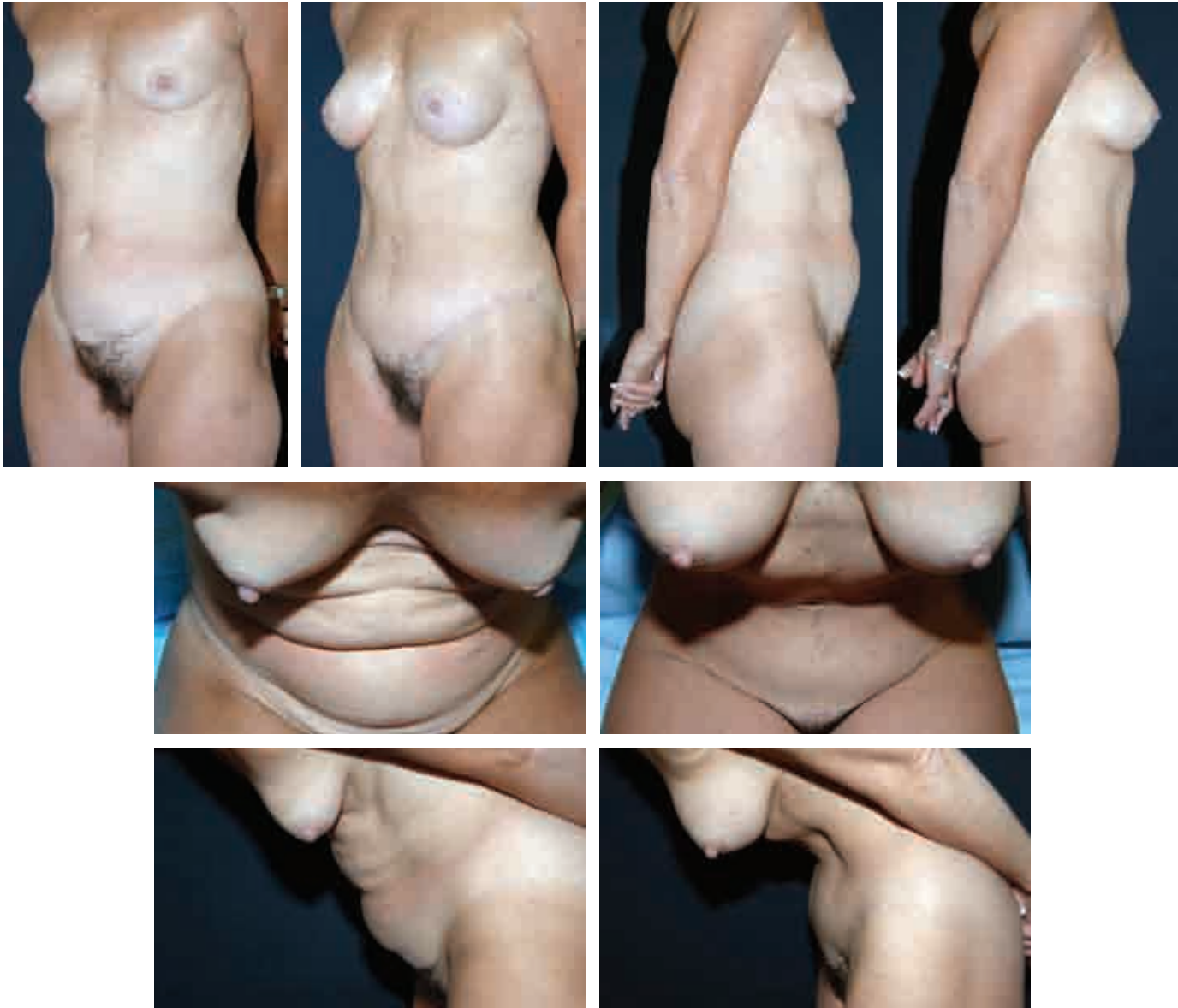
This 43-year-old nulliparous woman lost more than 45 kg (100 pounds) through a gastric bypass procedure. She elected to have an HLTA with liposuction of the hips and thighs. In evidence are the lift and correction of the lateral thigh/buttock region through well-placed scars.



This 39-year-old nulliparous woman had lost 91 kg (200 pounds) through diet and exercise alone. She demonstrated the most desirable skin envelope: thin and mobile. The patient underwent an HLTA using an extended posterior incision so that a more complete excision and lift of the lateral trunk could be achieved, while still properly treating the central tissues. Liposuction of the hips and lateral thighs as well as mastopexy with implantation were also performed.

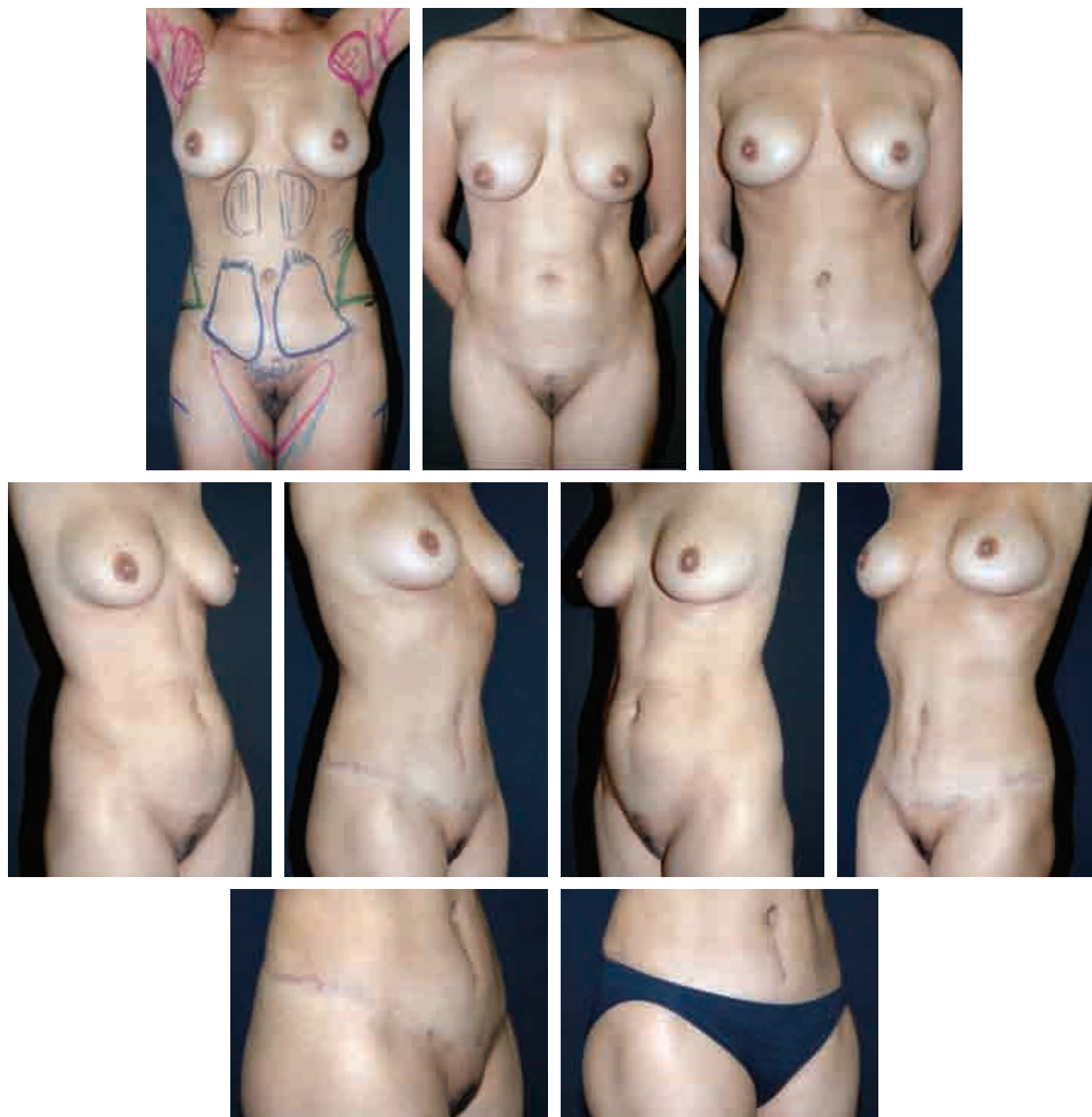


This 43-year-old nulliparous woman had undergone a bypass procedure and achieved a 66 kg (145-pound) weight loss. She subsequently underwent an HLTA and is seen 9 months postoperatively. The hallmarks of the HLTA effects are evident: the scar rests in a hidden position, the suprapubic skin is not overly tight, and the thigh and hip regions have been lifted. The closeup photo of the thigh reveals the qualitative improvement in the skin extending practically to the knee.



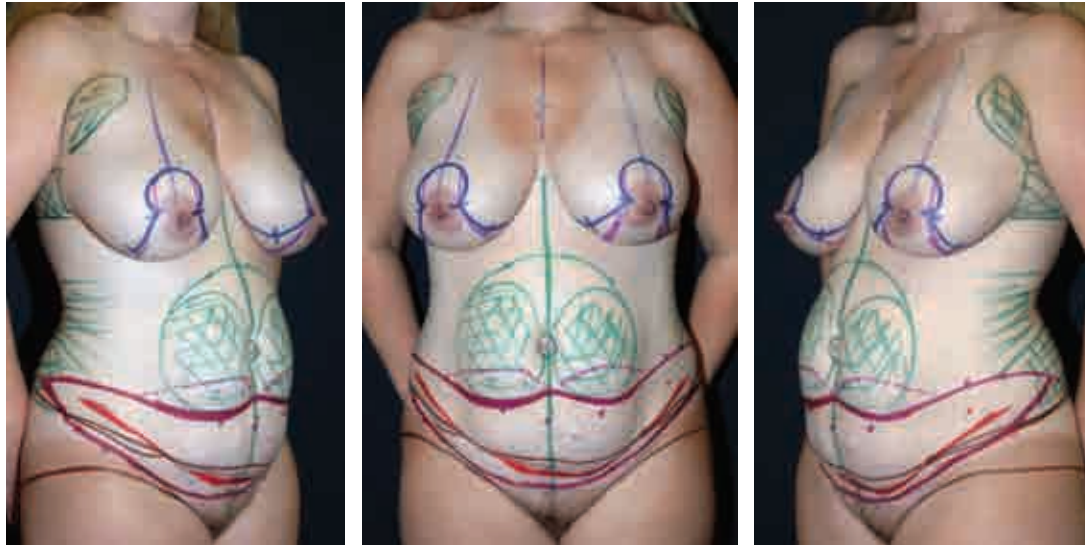
This 50-year-old woman requested rejuvenation of her abdomen; she had had one child. She underwent an HLTA with liposuction of the hips and lateral thighs and augmentation mammoplasty. The pleasing aesthetic of the abdominal repair is realized with a well-placed scar, a not overly tight suprapubic region, and an improved hip-thigh contour. Note the “stealth” skin redundancy, visible when the patient is sitting and bending, and its repair postoperatively. And still there is some residual skin excess in the epigastric area postoperatively.

## High Lateral Tension Abdominoplasty With Staged Liposuction

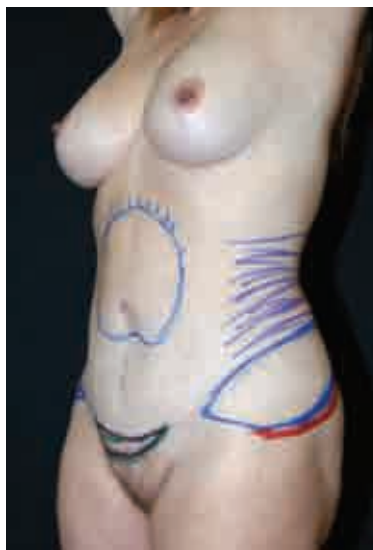

This 35-year-old woman had one child; she desired correction of her abdominal protrusion. She demonstrated a similar excess of skin when bending or sitting. An HLTA was performed with liposuction of the hips and thighs. The benefits of this technique are demonstrated with the return of her prepregnancy contour. As planned, the scar is properly hidden within the patient's underclothes. For safety, a planned second-stage liposuction was performed of the abdominal flap to complete the repair.



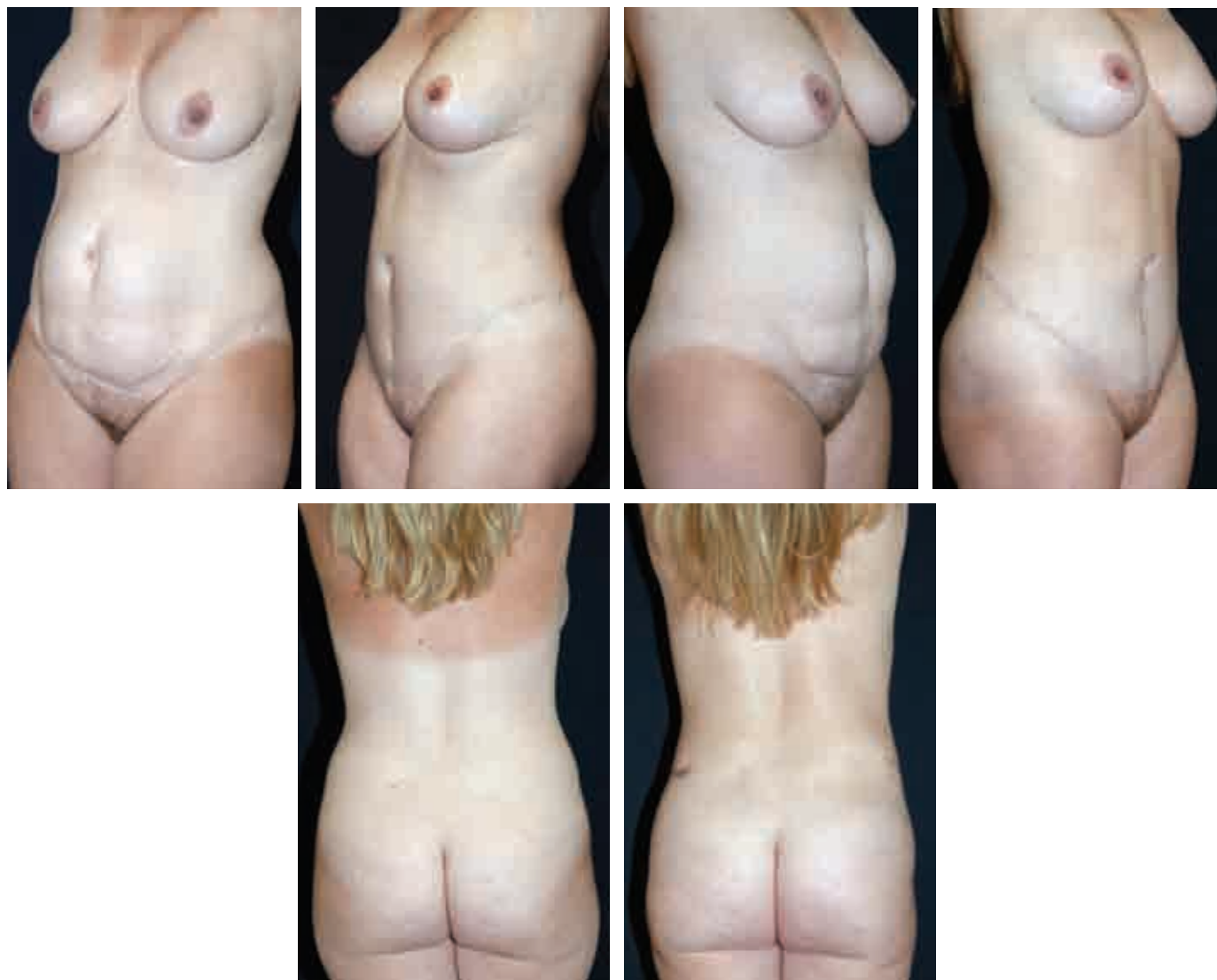

Markings for HLTA

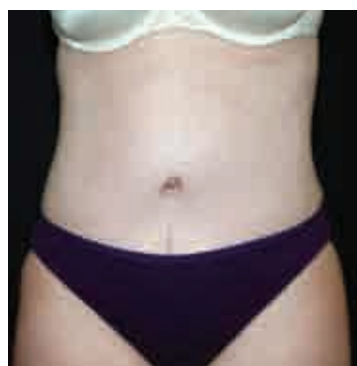

Markings for post-HLTA liposuction

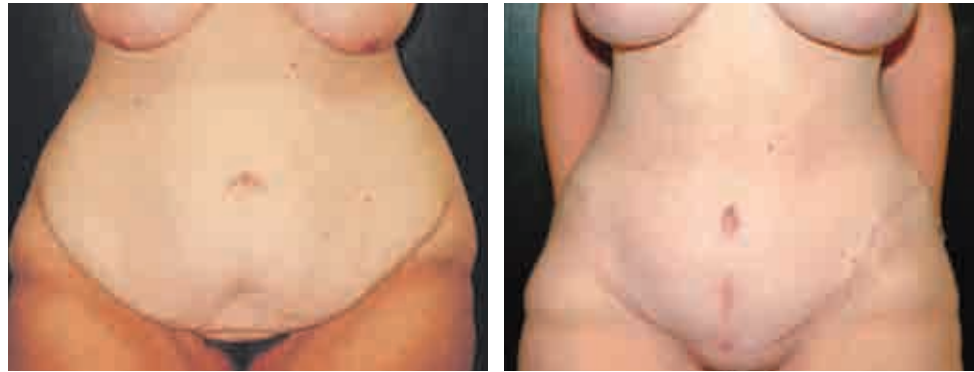This 36-year-old woman, 5 feet 3 inches tall and 70 kg (155 pounds), complained of residual abdominal deformity despite aggressive diet and exercise. She had had three children.



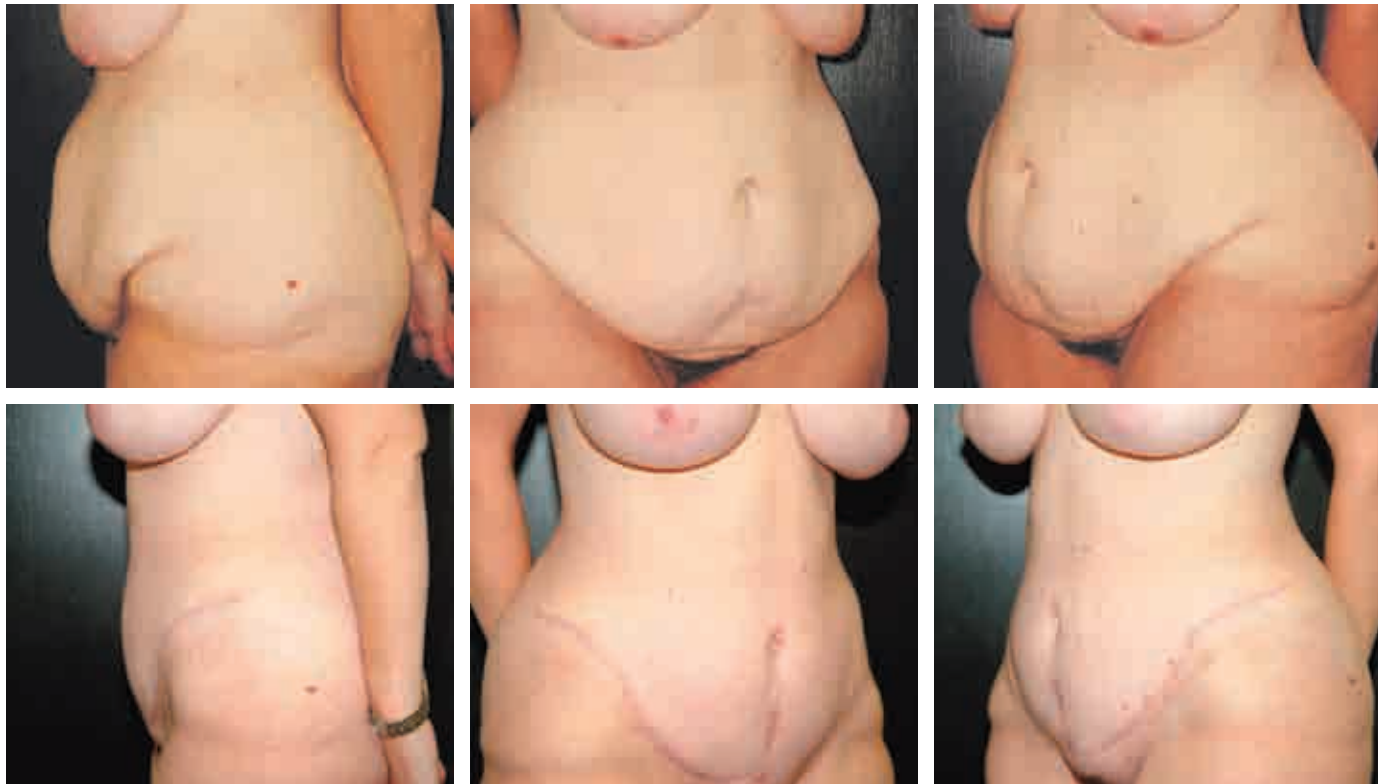The patient underwent an HLTA with aggressive liposuction of her hips and thighs. Note the relative lift of both the buttocks and thighs. Rather than potentially compromising the blood supply at the first surgery, a secondary liposuction of the abdominal flap was performed instead.



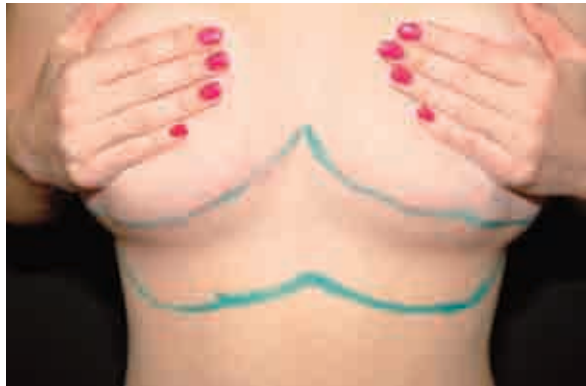As planned, the very productive, although lengthy, scar is hidden within her underwear.

**First Stage: High Lateral Tension Abdominoplasty****Second Stage: Reverse Abdominoplasty With Mastopexy**

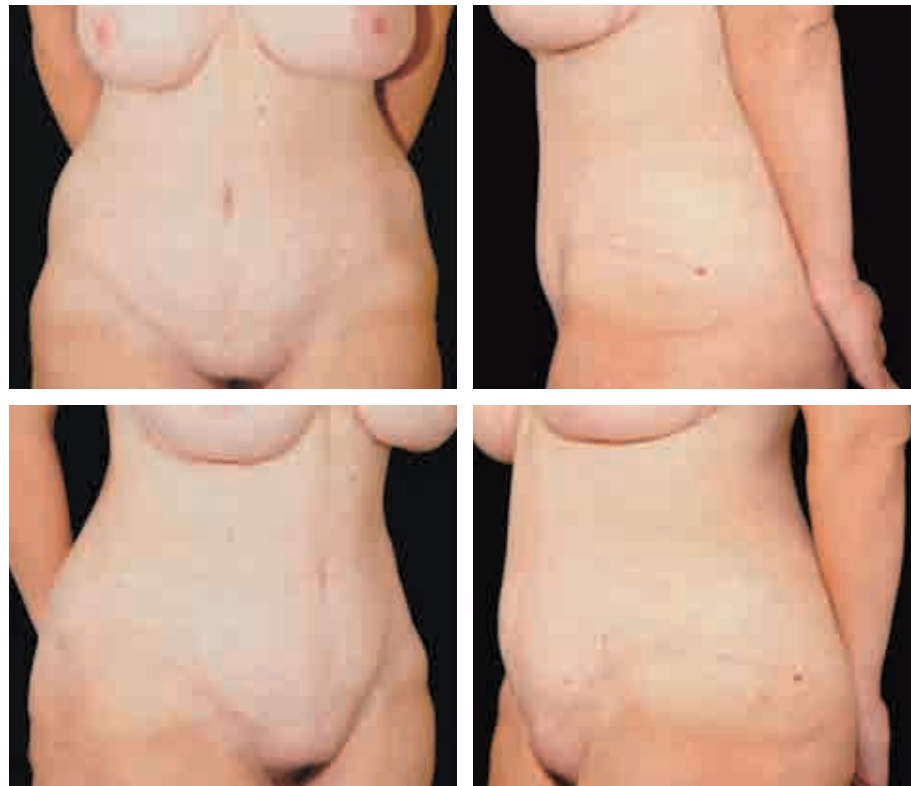This 32-year-old nulliparous woman had undergone a gastric bypass procedure. She had lost approximately 60 kg (132 pounds) and wished to improve the appearance of her anterior trunk, abdomen, and breasts.



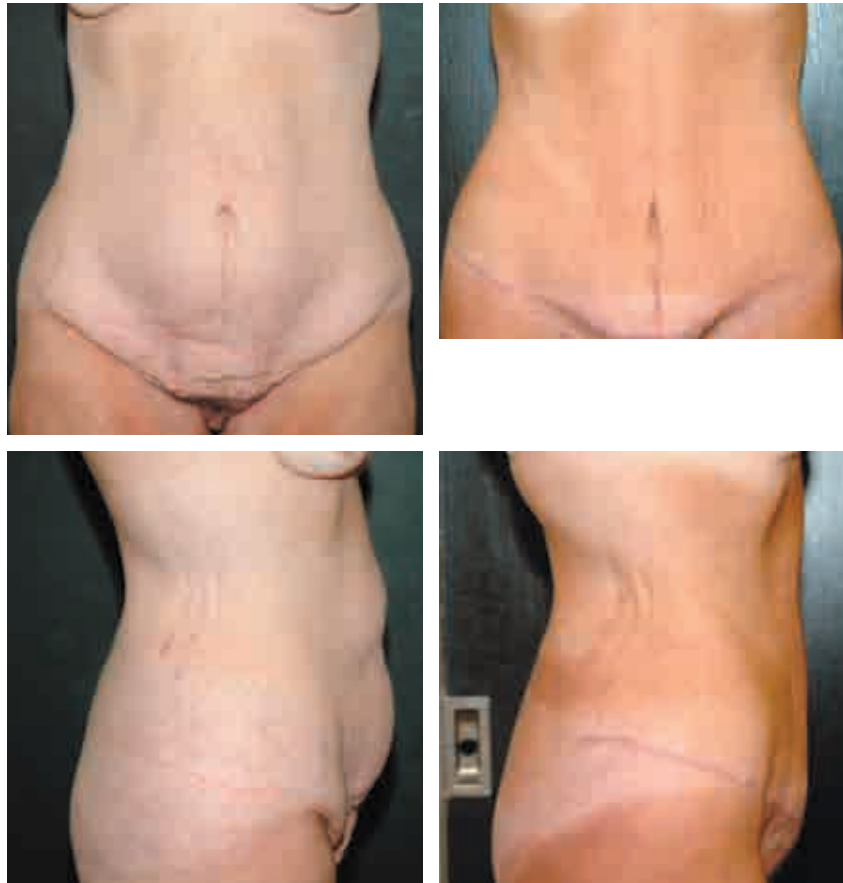A high lateral tension abdominoplasty was performed with a concomitant mastopexy; no implants were placed. In these photographs, taken approximately 15 months post-operatively, improved contours are evident, particularly full correction of the inguinal and hip areas as well as the waist.



The patient then requested correction of the residual redundant tissue at the upper abdomen. Approximately 7 to 8 inches of excess tissue was marked for excision.

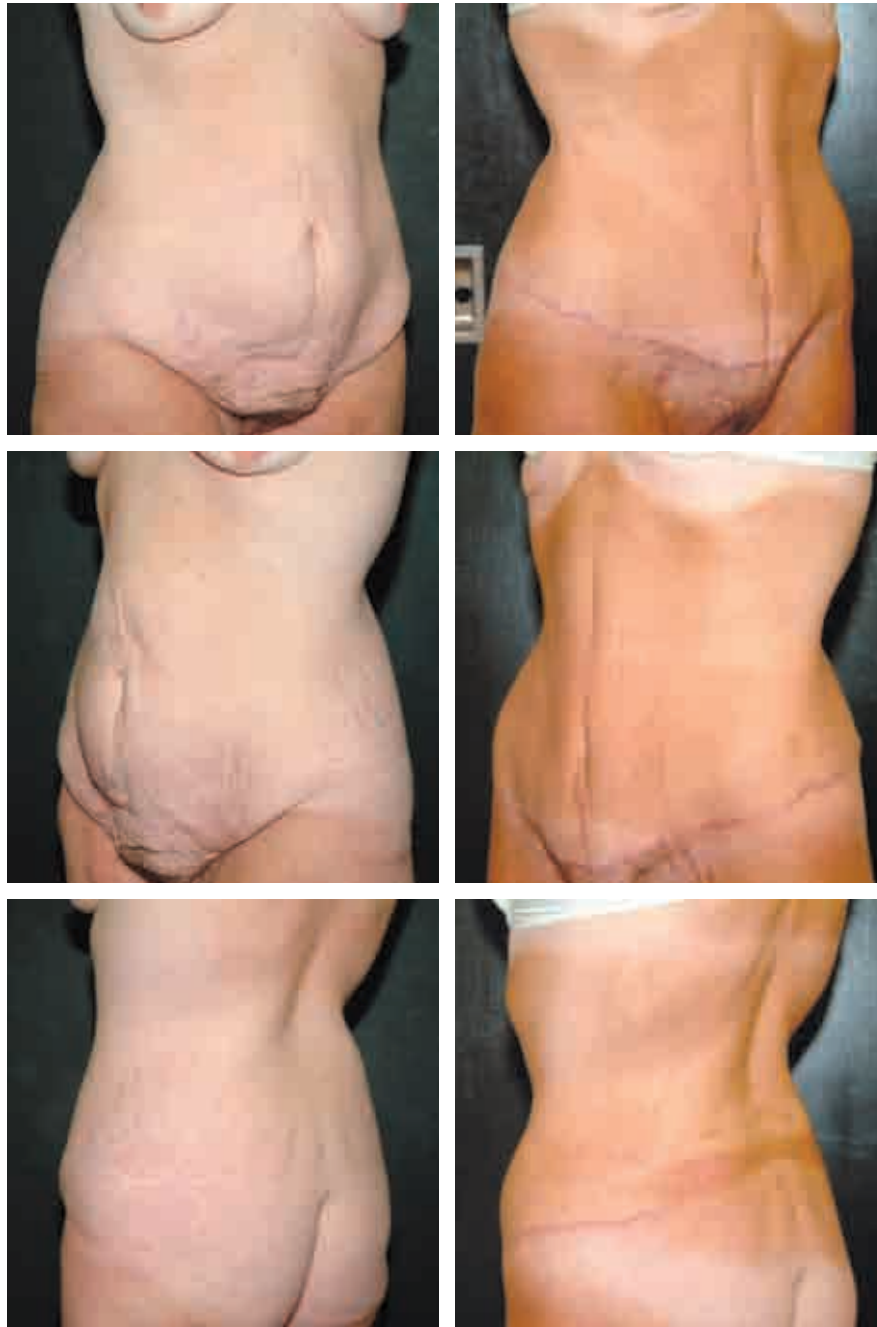

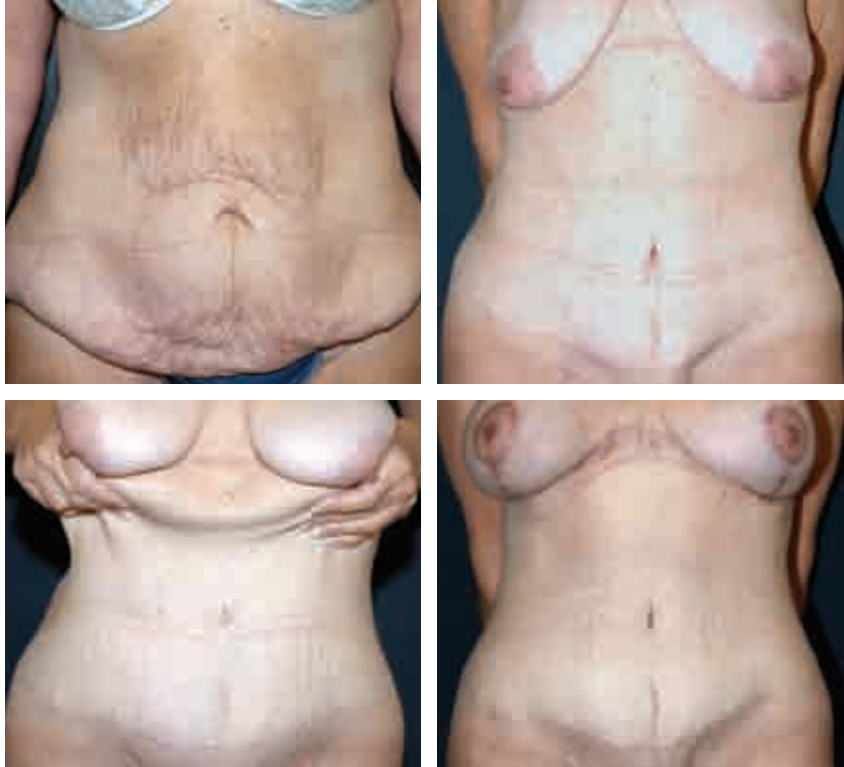A reverse abdominoplasty and synchronous mastopexy were performed. This resulted in a rewarding correction of her upper abdominal deformity. Seen 9 months post-operatively, the appropriate location of the inframammary crease is evident after proper fixation at the time of the abdominoplasty. The photos also demonstrate a slightly overly raised umbilicus, a potential minor stigma of a productive reverse abdominoplasty. As outlined, the surgeon should maintain tissue above the umbilicus undissected and secure the umbilicus to the underlying fascia.



This 43-year-old woman who had had three children underwent a gastric bypass with a resultant loss of 66 kg (145 pounds). She complained of redundant skin throughout her abdomen. Although she would have been an ideal candidate for a fleur-de-lis abdominoplasty, she did not want a midline scar. A high lateral tension abdominoplasty was performed with the ultimate plan of including a reverse abdominoplasty at the time of breast rejuvenation to address the inevitable residual upper abdominal tissue. She is seen approximately 18 months postoperatively. On the oblique views, note the significant reshaping of the hip and lateral thigh contours.



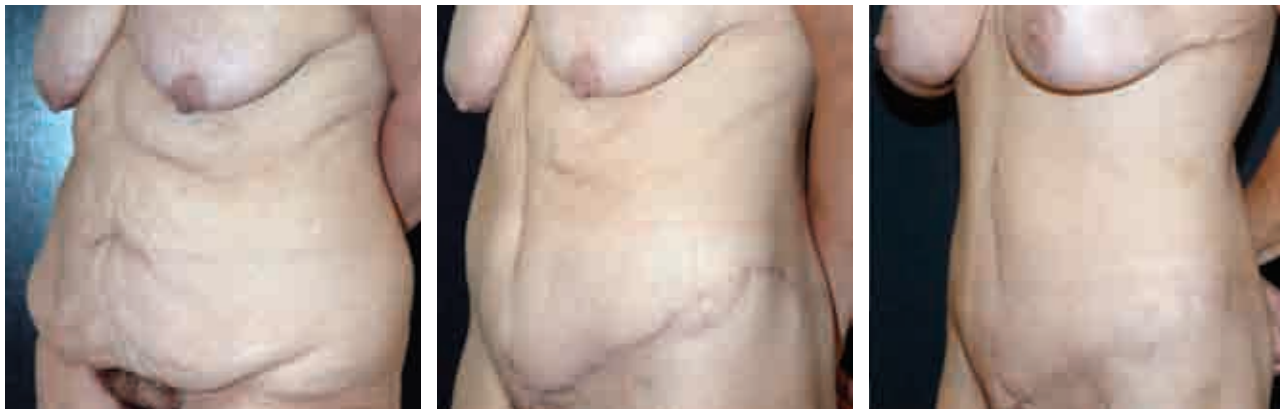



The patient later underwent a reverse abdominoplasty and mastopexy/augmentation to complete her repair. The excess upper abdominal skin remaining after the HLTA is now corrected.

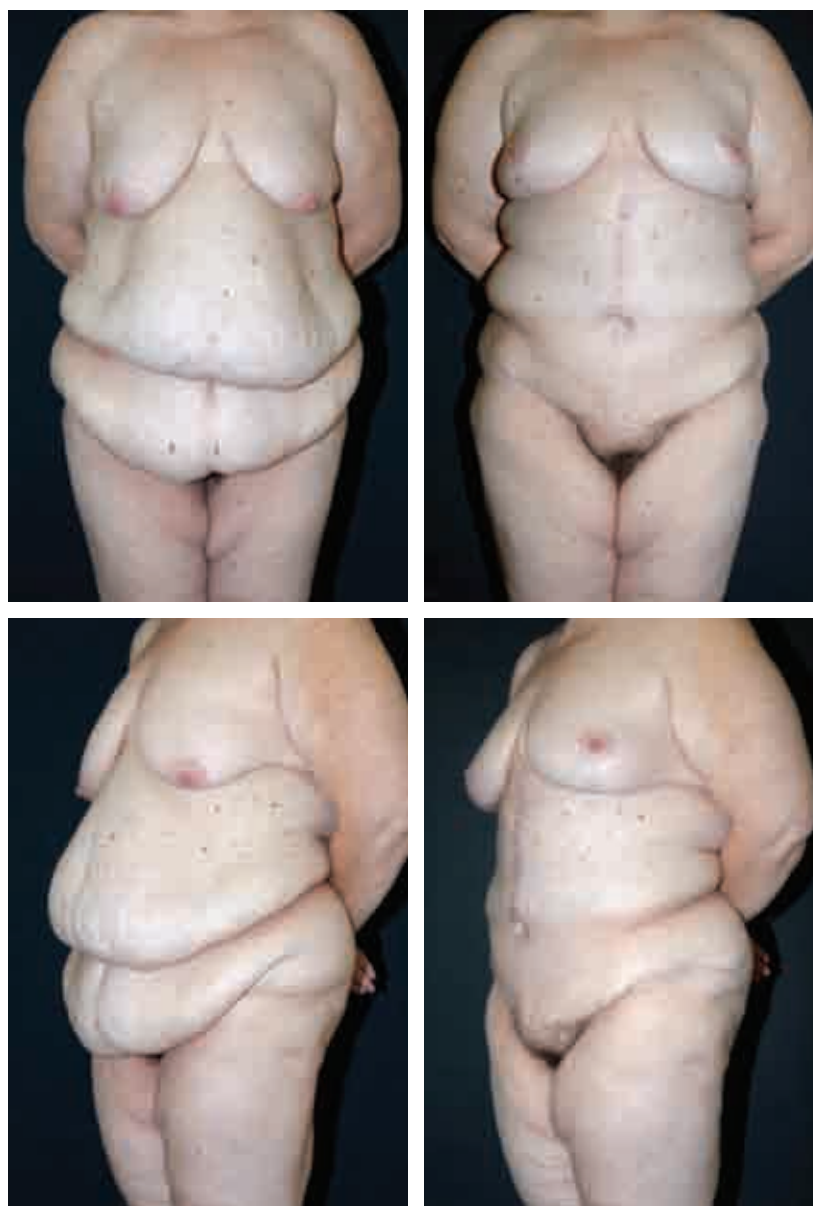
### **First Stage: High Lateral Tension Abdominoplasty**

### **Second Stage: Reverse Abdominoplasty With Augmentation/Mastopexy**

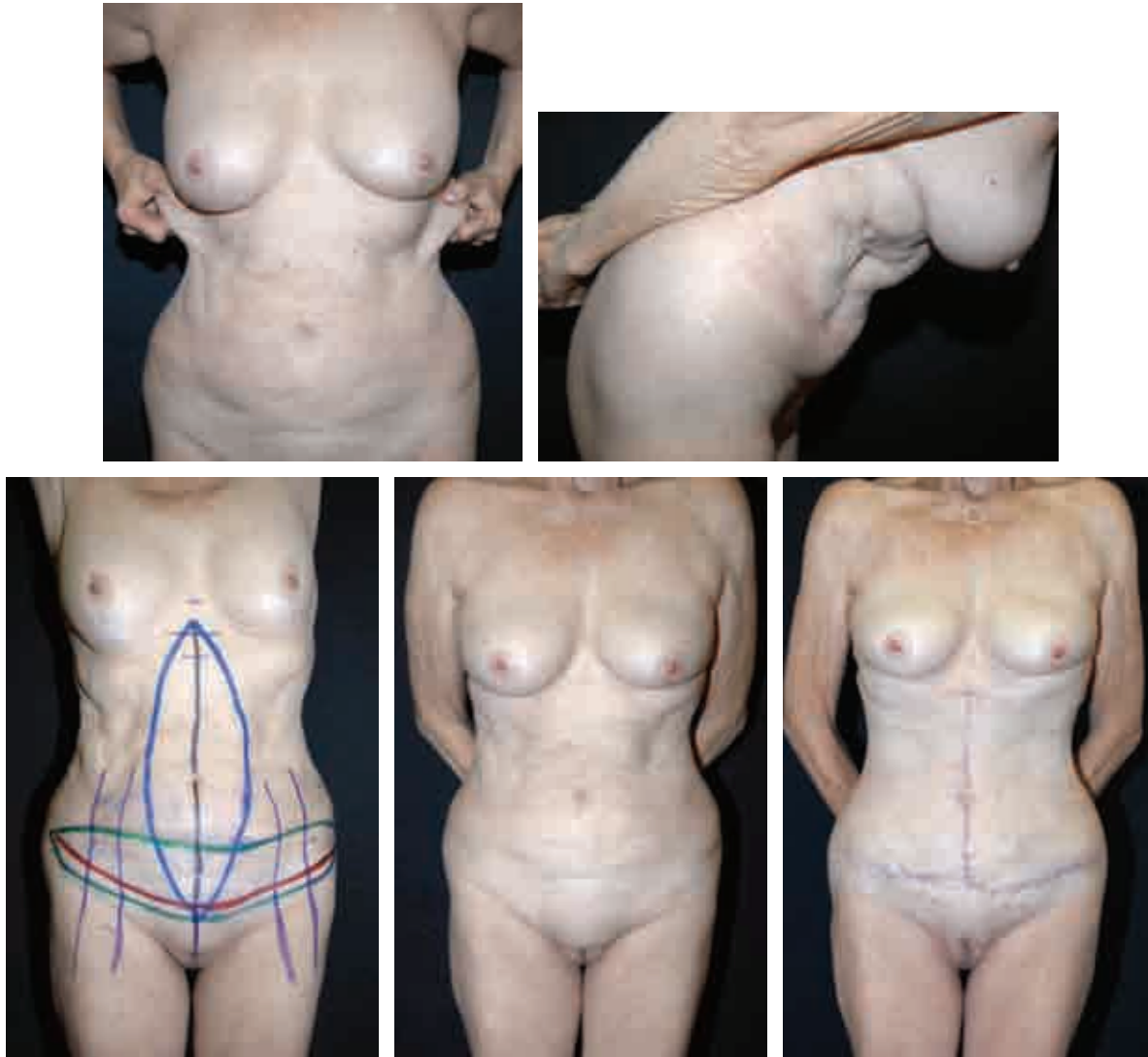


This 46-year-old woman had undergone a gastric bypass procedure. She had an HLTA first and then a staged reverse abdominoplasty for correction of the excess tissue at the upper abdomen and chest. The progressive results are seen.

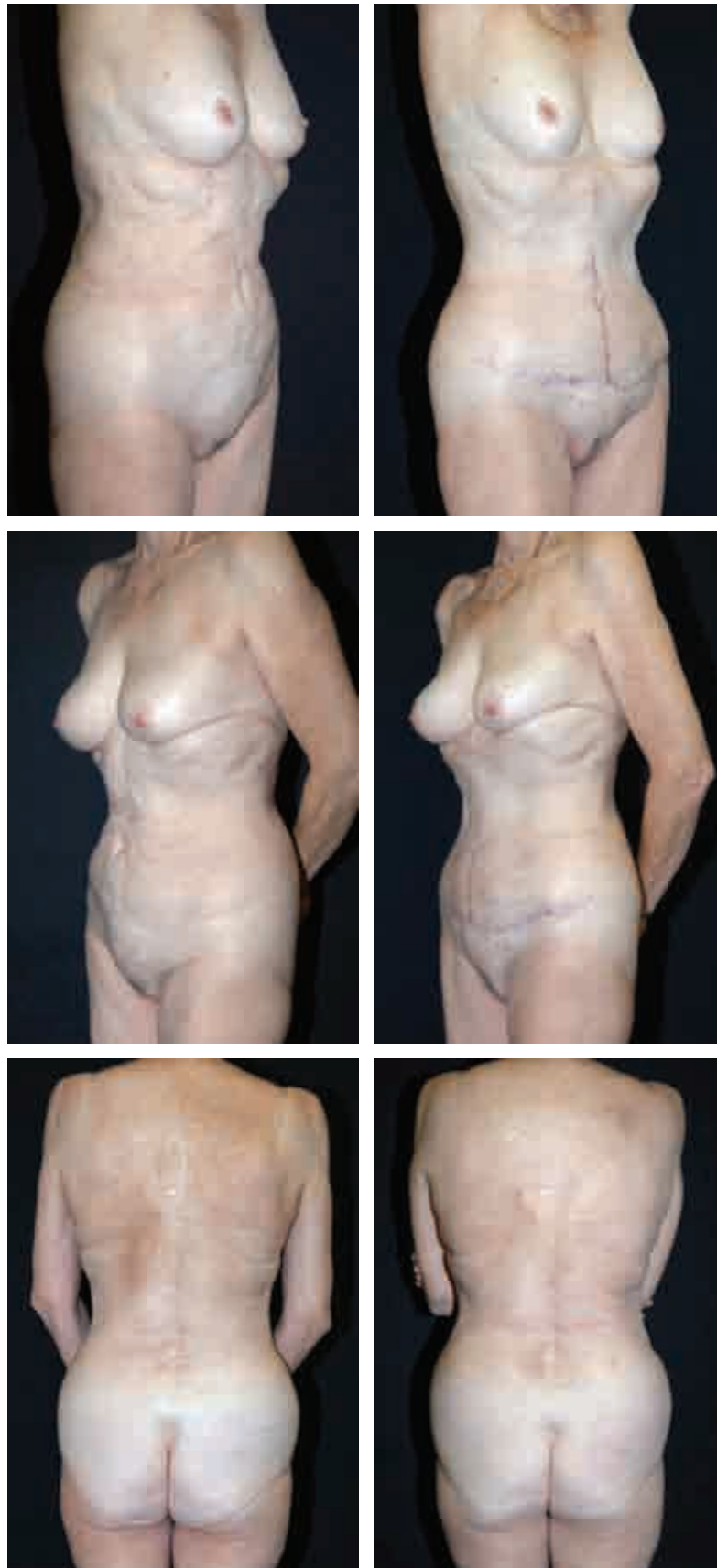
## Fleur-de-Lis Abdominoplasty With High Lateral Tension



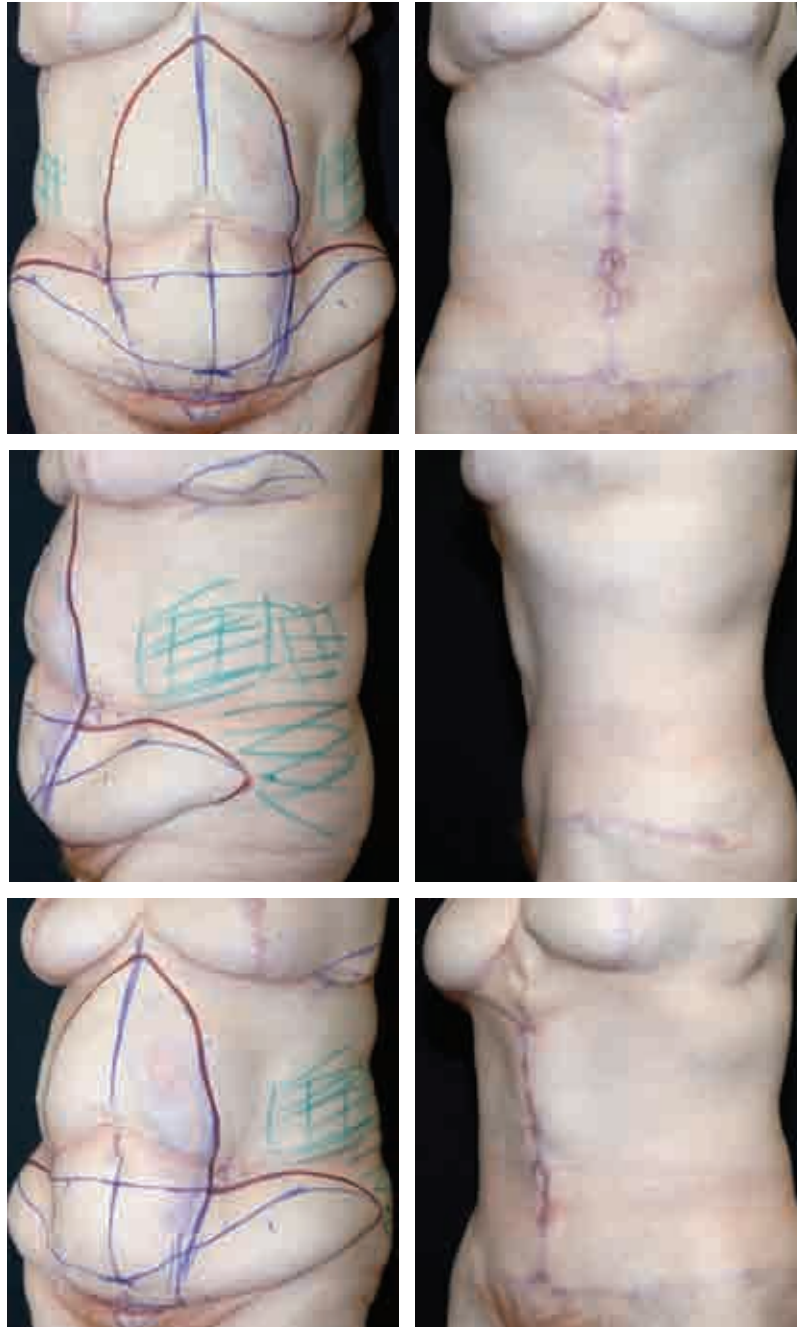
This 41-year-old female achieved a 64 kg (140-pound) weight loss from gastric bypass surgery. Her goal was simply to have the abdominal redundancy improved as much as possible. The patient was otherwise very healthy. The massive upper abdominal “second pannus” could only be properly and safely repaired with a fleur-de-lis technique. Significant body contouring was accomplished despite the patient’s thicker habitus. She also underwent a concomitant mastopexy.



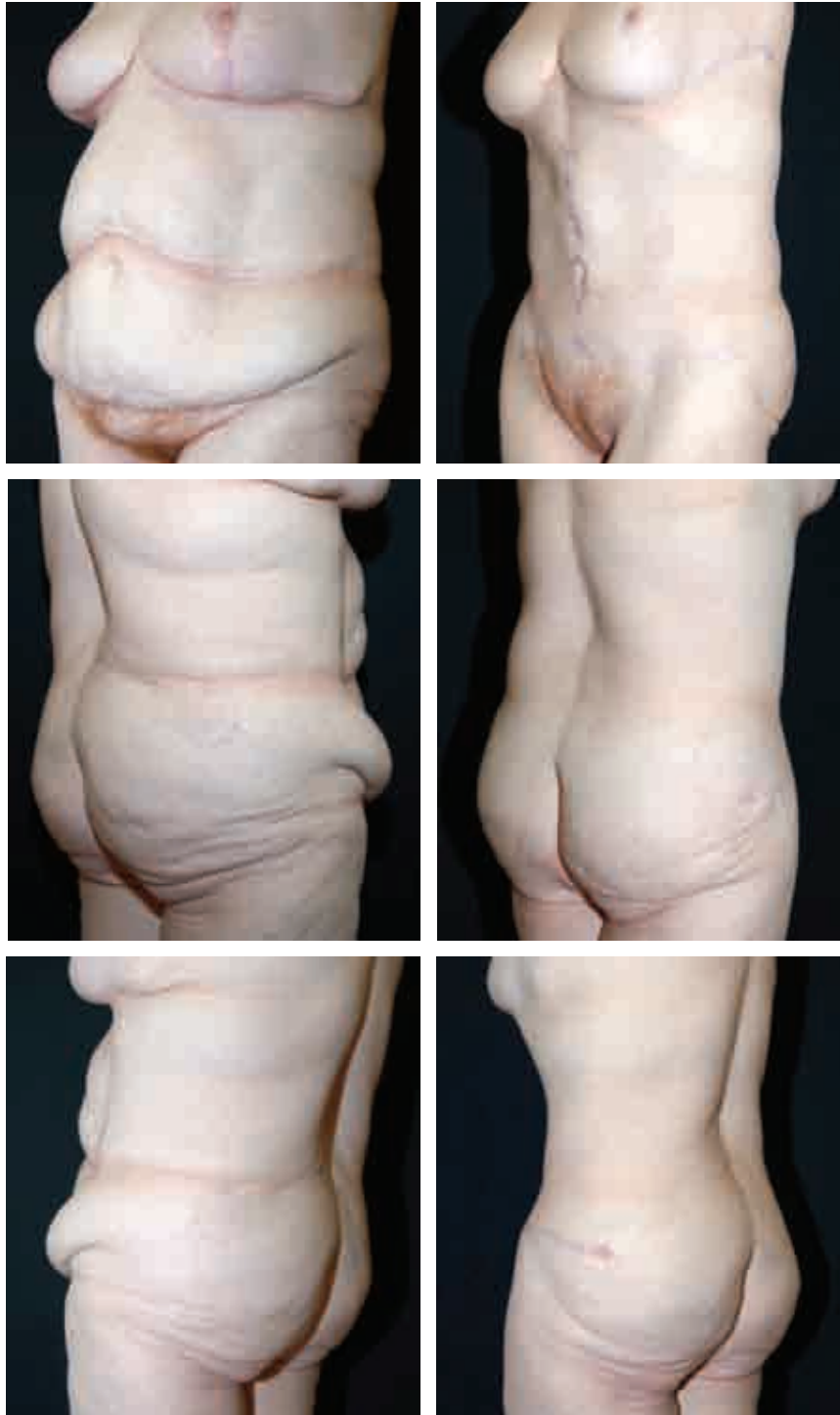This very fit 65-year-old woman desired a better contour with correction of her abdominal redundant skin and protrusion. She had had two children. She elected to have a fleur-de-lis procedure to more fully improve her shape. Note the excess stealth skin that becomes more obvious with change in position or when put on tension. Her aesthetic habitus allowed the full effect of the fleur-de-lis to be expressed with a particularly dramatic improvement in her pubis, waist, upper abdomen, and back folds. In addition, the patient's posture appears to have improved.



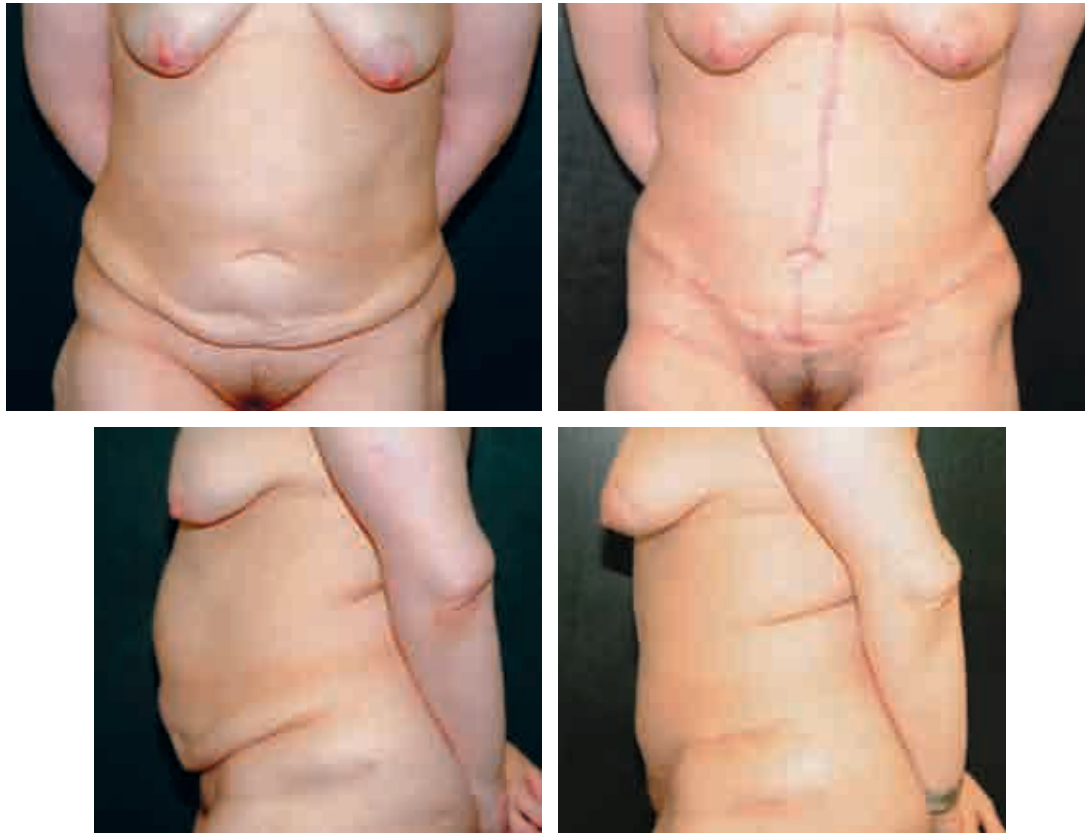




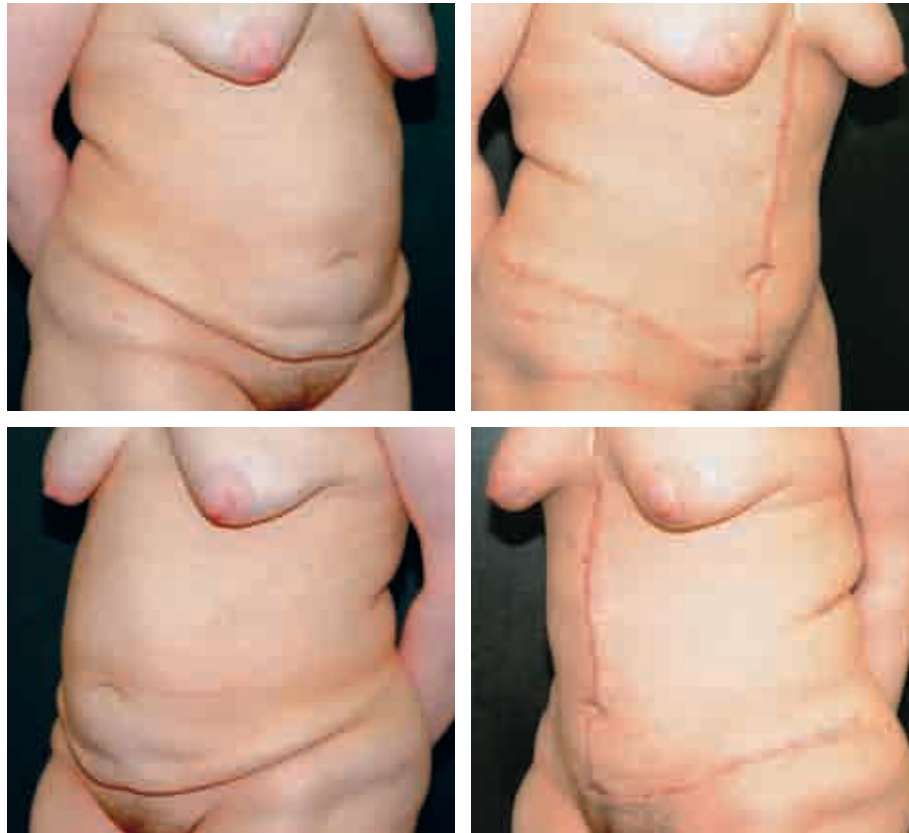
This 59-year-old woman underwent a gastric bypass and a subsequent weight loss of more than 45 kg (100 pounds). She requested abdominal correction, and because of the excess skin in the upper poles of the abdomen, we elected to perform a fleur-de-lis abdominoplasty with a proper high lateral tension approach to the lower abdomen.



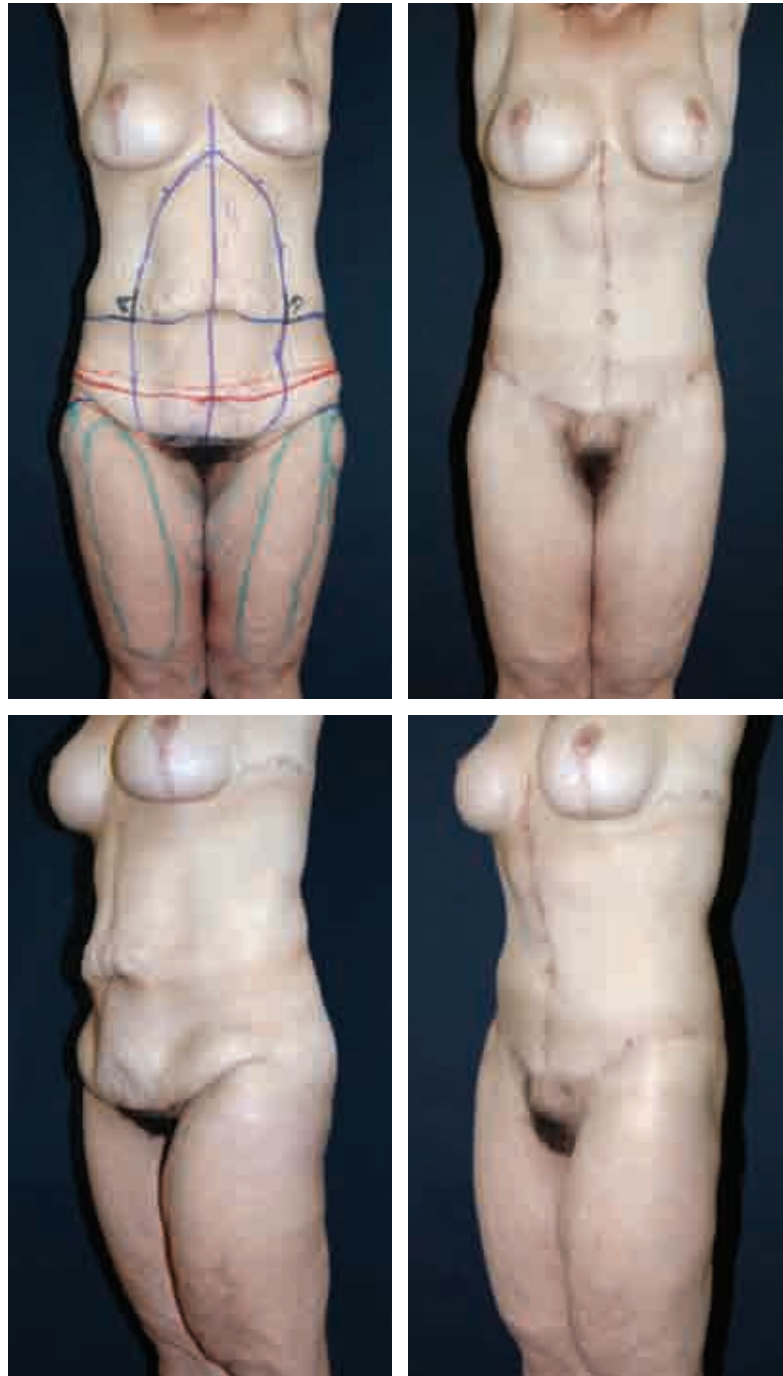
The results demonstrate the rewarding improvement not only of the abdomen, but also a more far-reaching correction of the waist and back (fleur-de-lis) as well as the thighs and buttocks (HLTA).



This 33-year-old nulliparous woman had undergone a gastric bypass and lost 50 kg (110 pounds). She desired as complete an abdominal recontouring as possible in one stage. Therefore she was very accepting of a fleur-de-lis approach and equally pleased with the relatively full repair of her redundant tissue, as seen here 7 months post-operatively.



## Fleur-de-Lis Abdominoplasty With Posterior Body Lift

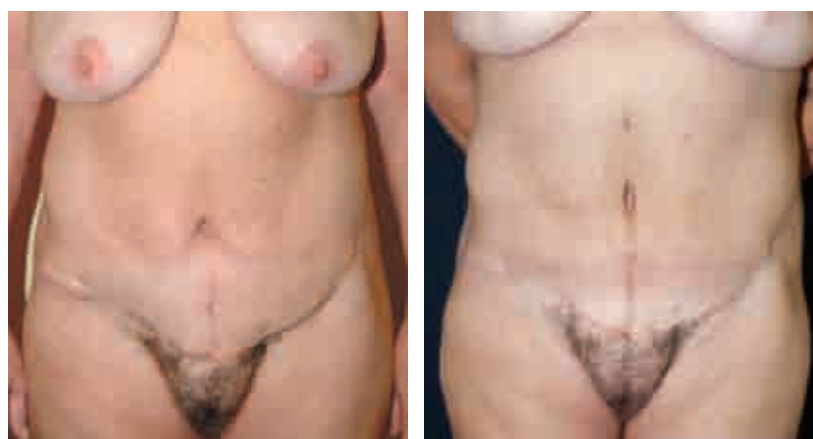
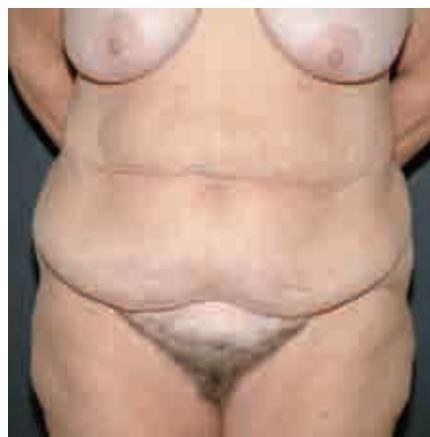

This 40-year-old nulliparous woman had lost 73 kg (160 pounds) as a result of gastric bypass surgery. A concomitant fleur-de-lis abdominoplasty and posterior body lift were performed. Note the correction of both the abdomen and the surrounding aesthetic units.

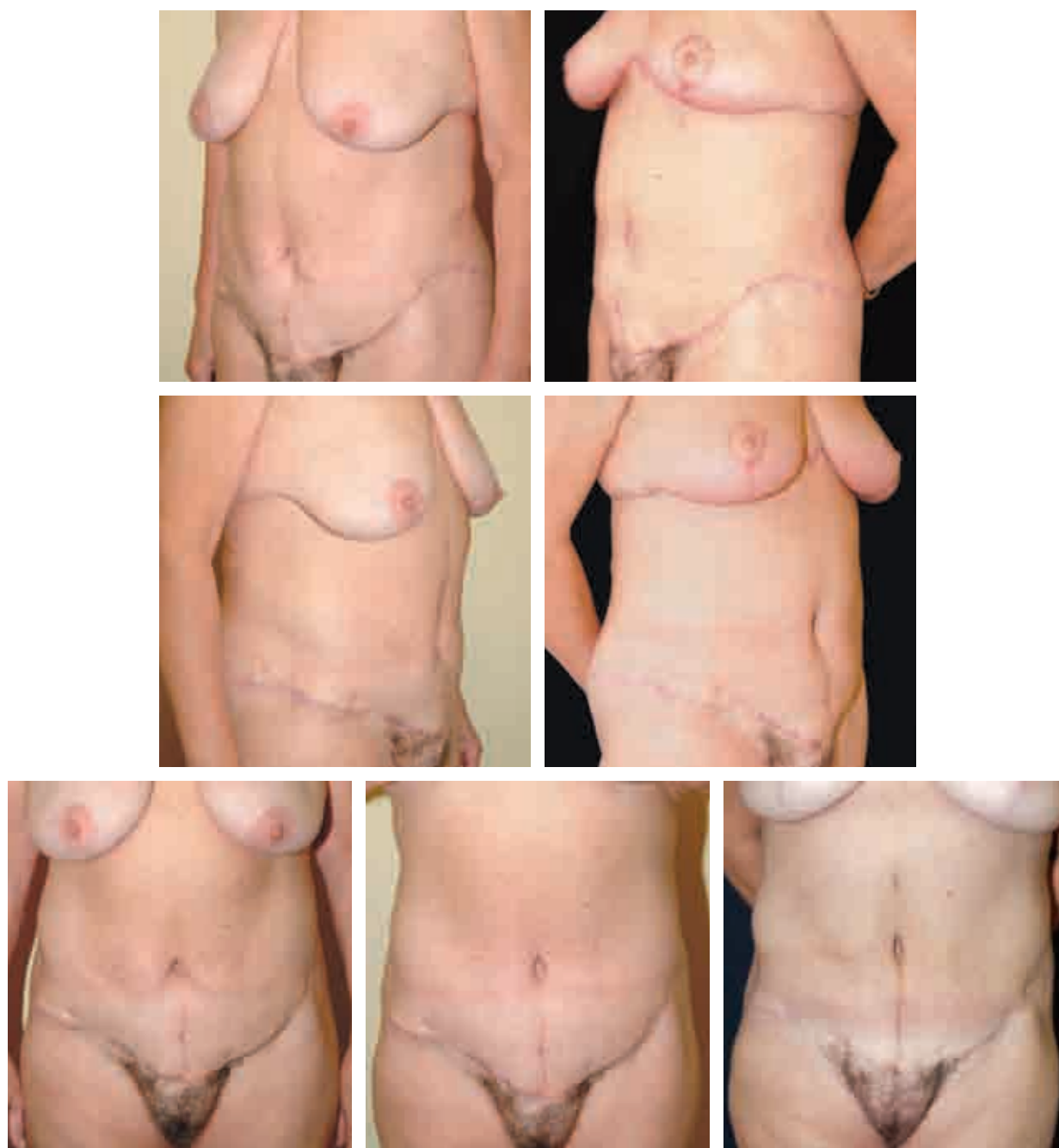


### **First Stage: High Lateral Tension Abdominoplasty With Posterior Body Lift**

### **Second Stage: Reverse Abdominoplasty With Augmentation/ Mastopexy**

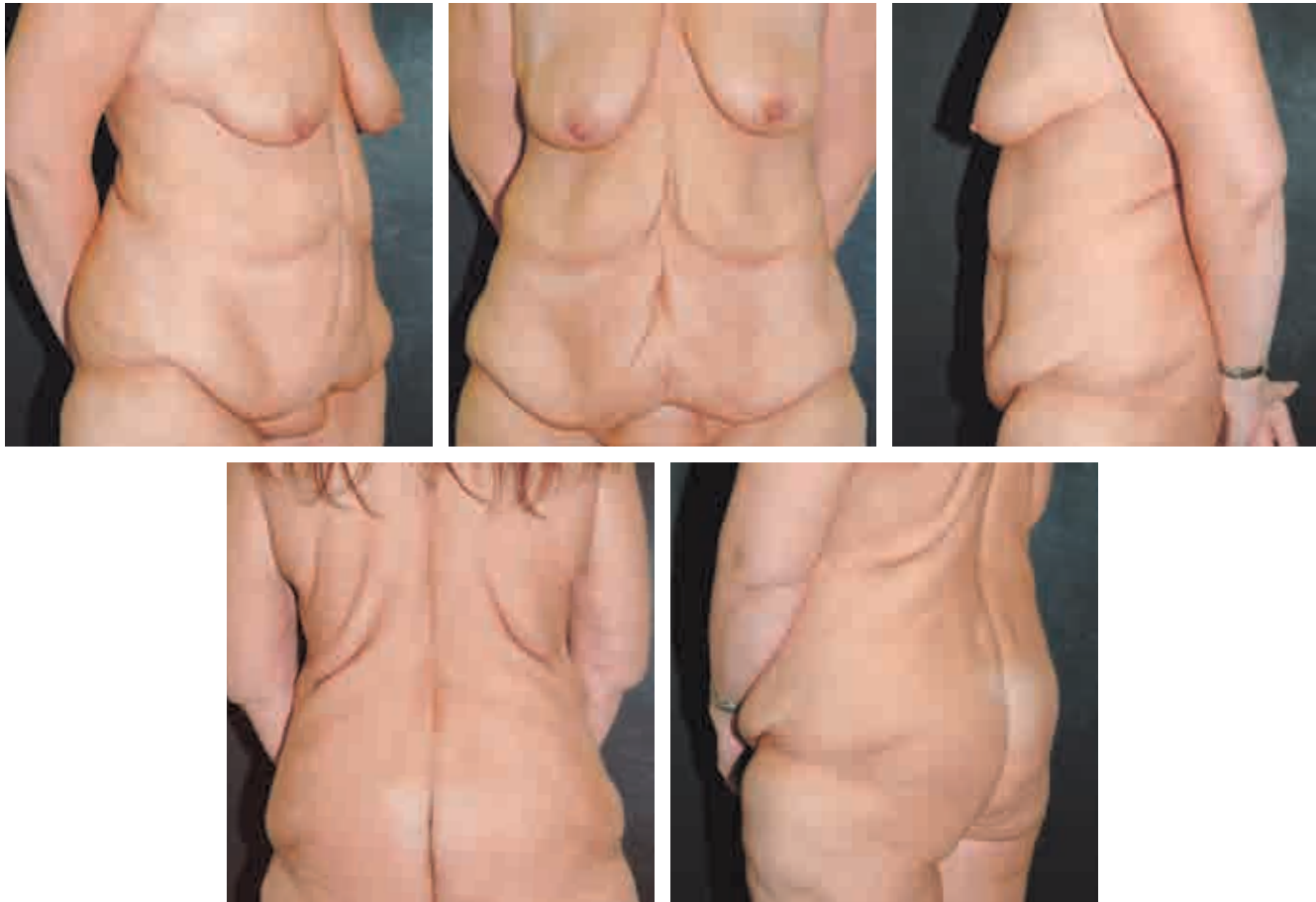

This 53-year-old nulliparous woman had originally lost 50 kg (110 pounds) after a gastric bypass. She was seen 6 months after an HLTA with a posterior body lift and now desired repair of a significant redundancy of the upper abdomen. At the time of the reverse abdominoplasty, a mastopexy with augmentation was also performed. By inseting the abdominal flap before the breast surgery, a definitive breast platform was created. At 4 months postoperatively, note the tight appearance of the upper abdomen. The sequential results are illustrated (see p. 3018).



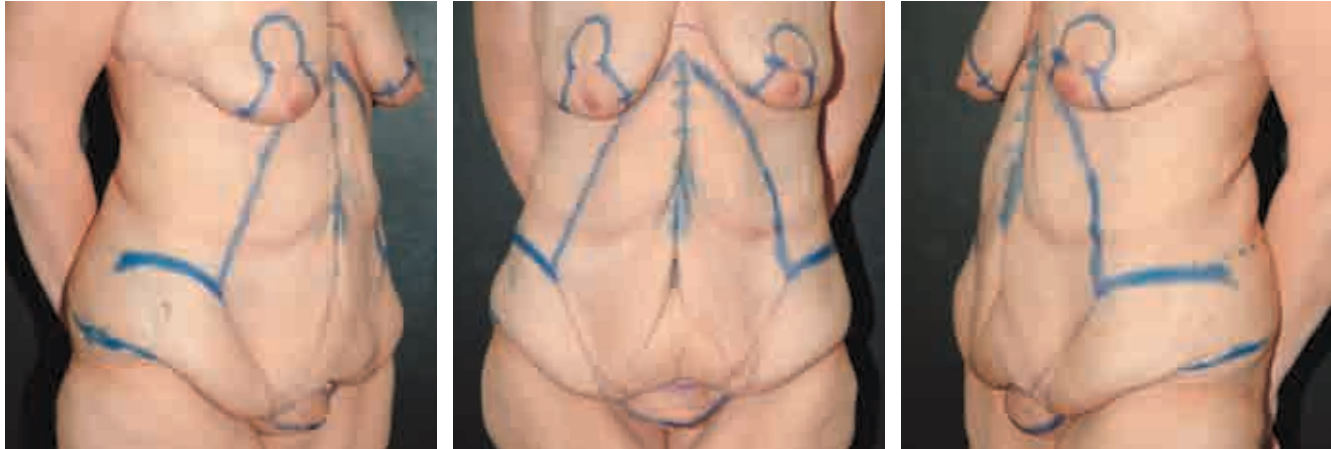
It is instructive to ask the patient to perform an examination room “nonsurgical lift” (see p. 2975) of the excess skin to demonstrate her goals. As can be seen, the results came very close to meeting those goals.

## Fleur-de-Lis Abdominoplasty Using High Lateral Tension and Reverse Abdominoplasty With Augmentation/Mastopexy During One Operative Session

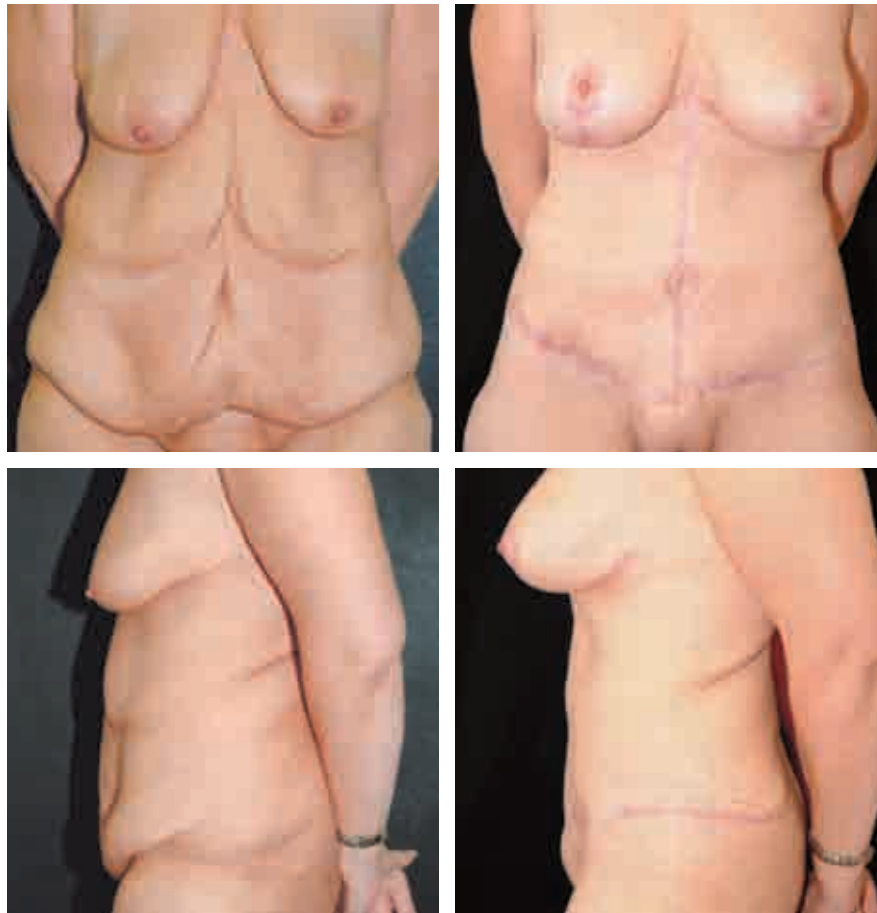


This 35-year-old nulliparous woman was seen after a gastric bypass and subsequent weight loss of 109 kg (240 pounds). She requested both abdominal and breast rejuvenation. As seen in her preoperative photographs, there was a significant amount of excess tissue in the vertical and horizontal dimensions, with cascading skin redundancy at the upper and lower abdomen.

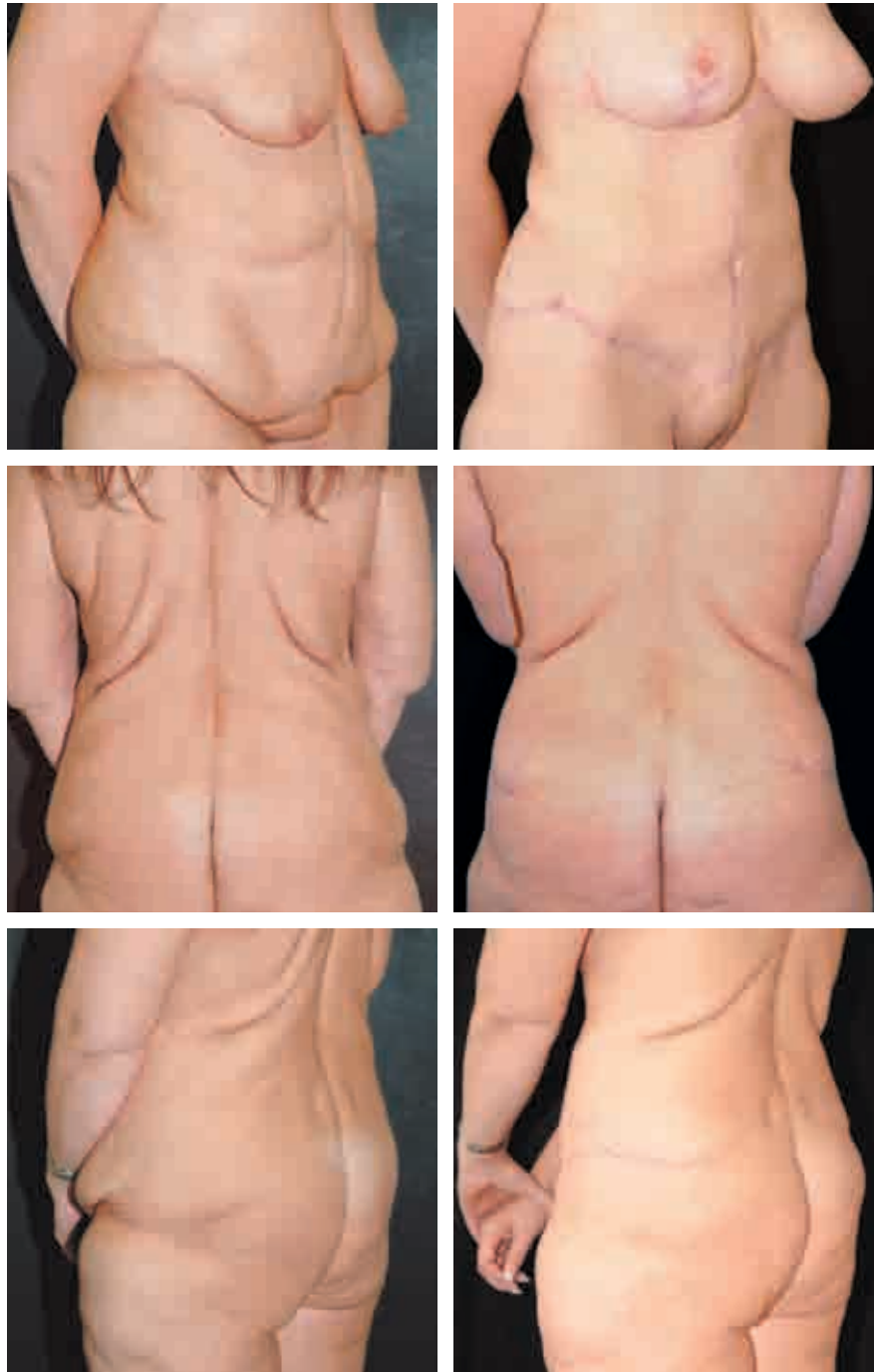This redundancy was present not only at the abdomen but also extended onto the chest, flanks, and back. She had an upper midline vertical scar; therefore a fleur-de-lis approach was designed. Because breast surgery was to be performed, a conservative reverse abdominoplasty was conducted. This entailed direct resection, without undermining, of the abdominal excess skin through the inframammary incisions. *Therefore the patient essentially underwent all three complementary procedures during one operative session.* The fleur-de-lis surgery was conducted before the breast augmentation/mastopexy to ensure the inset of the upper abdominal flap and the definition of a proper inframammary crease on which the breast could be built.



Her preoperative markings are shown.



The postoperative results at 8 months reveal the impressive, almost circumferential correction. The scar is once again low centrally and hidden throughout. The improvement at the upper chest, back folds, thighs, and waist is evident.





## Concluding Thoughts

A well-conceived and well-executed high-tension abdominoplasty, with the addition of the fleur-de-lis or reverse principles, defines a truly comprehensive abdominoplasty, which is a surgical antidote to the shortfalls of more traditional approaches. In essence, comprehensive abdominoplasty is a more complete treatment of the anterior trunk aesthetic unit from the submammary and lateral chest area to the pubic, thigh, and buttock zones, with a greater overall aesthetic result and margin of vascular safety.

## Clinical Caveats

### *Key Principles of the High Lateral Tension Abdominoplasty*

- The HLTA is driven by the concerted effort to treat not only the tissues above the incision but also those below. This treatment is as much excision of redundancy as it is a far-reaching body lift through a relatively anterior incision. The pubis and anteromedial thighs as well as the hips, anterolateral thighs, and even buttocks can be aesthetically improved by this technique.
- This procedure is fundamentally and philosophically different in that the skin is considered more redundant at the lateral trunk than in the midline. Therefore the anterolateral thigh can be more effectively treated. In addition, the redundant upper abdominal skin emanates more from the chest and demonstrates more of a horizontal laxity compared with the vertical laxity of the lower pannus. Thus the relatively oblique pull of the HLTA can more effectively treat this epigastric excess.
- This approach, in contradistinction to the traditional abdominoplasty, is not driven by the usually mandatory excision of all the skin between the pubis and umbilicus. Therefore the pubic/median portion of the incision can be naturally lower and more hidden and the closure can be under less tension, improving the chances for healing by first intention and a more natural looking result.
- The HLTA often mandates that the incision be longer laterally. However, it is also true that the longer the lateral incision, the better the result. This approach allows the excision of a greater extent of skin, and what is more important, affords an impressive body lift of the surrounding tissues. This balance between scar length and result must be negotiated with the patient.
- As a corollary, if there is not a significantly redundant skin envelope at the lateral thigh, the HLTA should be “tempered,” and the scar can and should be shorter.

- This technique, although often more effective at treating the upper abdominal skin excess, should be supplemented by a second-stage reverse abdominoplasty procedure when necessary or even “converted” to a fleur-de-lis initially.
- The HLTA is predicated on preservation of the flap blood supply first and foremost. As part of this philosophy, for a patient with a medium to high BMI the surgeon should seriously consider a staged liposuction of the central and superior abdominal flap instead of either liposuction or direct excision. Only then can a zero tolerance for skin necrosis truly be honored.
- The entire anterior trunk should be considered as one aesthetic unit. Thus not just the traditional lower abdominal pannus is treated but all of the areas surrounding this deformity as well.

#### *Fleur-de-Lis Abdominoplasty*

- The excess skin (particularly when first applying this technique) should be tailor-tacked in the vertical and horizontal directions to more safely conduct the skin excisions.
- Tacking should always be started at the inverted-T junction to ensure that enough skin is preserved for the suprapubic closure.
- Surgery beyond the xiphisternum should be avoided to avoid the scar’s riding up between the breasts.
- The surgeon should imagine the excision as a fleur-de-lis skin template, never undermining the skin flaps.

#### *Reverse Abdominoplasty*

- All patients undergoing significant routine abdominoplasties (especially weight-loss patients considering possible breast rejuvenation) should be informed that a reverse abdominoplasty might be desirable at a later time.
- The position of the future crease should be accurately determined with the patient in the upright position on the operating table.
- The abdominal flap should always be doubly secured to the defined inframammary crease to create a platform on which the breast can rest and the abdominal flap can hang.
- The relative mobility of the umbilicus and the extent of excision must be assessed to help determine how much umbilical displacement may occur. The tissue above the umbilicus should be left undissected in an effort to block excessive superior movement.

## Annotated Bibliography

Baroudi R, Keppke EM, Carvalho CG. Mammary reduction combined with reverse abdominoplasty. *Ann Plast Surg* 2:368, 1979.

*These investigators were the first to publish a report in the English-language literature of the combined technique of reduction mammoplasty and reverse abdominoplasty. They give credit to Rebello and Franco for originally describing the approach in 1972 in the Brazilian literature.*

Dellon AL. Fleur-de-lis abdominoplasty. *Aesthetic Plast Surg* 9:27-32, 1985.

*This is the first description of the fleur-de-lis technique. Dellon emphasizes the advantage of combining a vertical and a horizontal resection in restoring abdominal contour.*

Lockwood T. High-lateral-tension abdominoplasty with superficial fascial system suspension. *Plast Reconstr Surg* 9:603-615, 1995.

*This seminal article describes the principles and surgical results of this new approach to abdominoplasty.*

## Suggested Readings

Babcock W. The correction of the obese and relaxed abdominal wall with special reference to the use of buried silver chain. *Am J Obstet* 74:596, 1916.

Burget G, Menick F. The subunit principle in nasal reconstruction. *Plast Reconstr Surg* 76:239-247, 1985.

Castanares S, Goethel J. Abdominal lipectomy: a modification in technique. *Plast Reconstr Surg* 40:378-383, 1967.

Duff C. Fleur-de-lys abdominoplasty: a consecutive case series. *Br J Plast Surg* 56:557-566, 2003.

Fang RC, Lin SJ, Mustoe TA. Abdominoplasty flap elevation in a more superficial plane: decreasing the need for drains. *Plast Reconstr Surg* 125:677-682, 2010.

Grazer F. Abdominoplasty. *Plast Reconstr Surg* 51:617-623, 1973.

Huger W Jr. The anatomic rationale for abdominal lipectomy. *Am Surg* 45:612-617, 1979.

Kelly H. Excision of the fat of the abdominal wall. *Surg Gynecol Obstet* 10:229, 1910.

Le Louarn C. Partial subfascial abdominoplasty. *Aesthetic Plast Surg* 20:123-127, 1996.

Le Louarn C, Buis J, Buthiau D. Treatment of depressor anguli oris weakening with the face recurve concept. *Aesthet Surg J* 26:603-611, 2006.

Matarasso A. Abdominolipoplasty: a system of classification and treatment for combined abdominoplasty and suction-assisted lipectomy. *Aesthetic Plast Surg* 15:111-121, 1991.

Nahai F, Brown RG, Vasconez LO. Blood supply to the abdominal wall as related to planning abdominal incisions. *Am Surg* 42:691-695, 1976.

- Pitanguy I. Abdominal lipectomy: an approach to it through an analysis of 300 consecutive cases. *Plast Reconstr Surg* 40:384-391, 1967.
- Ramsey-Stewart G. Radical “fleur-de-lis” abdominal after bariatric surgery. *Obesity Surg* 3:410-414, 1993.
- Rebello C, Franco T. [Abdominoplasty with inframammary scar] *Rev Bras Cir* 62:249, 1972.
- Regnault P. Abdominal dermolipectomies. *Clin Plast Surg* 2:411-429, 1975.
- Rosenfield LK. High tension abdominoplasty 2.0. *Clin Plast Surg* 37:441-465, 2010.
- Saldanha OR, de Souza Pinto EB, Mattos WN Jr, et al. Lipoabdominoplasty with selective and safe undermining. *Aesthetic Plast Surg* 27:322-327, 2003.

